NASA CR 65427

FINAL REPORT ON CONTRACT NUMBER NAS 9-3905

"PHYSIOLOGIC EFFECTS OF DIETARY CLAY SUPPLEMENTS"

Principal Investigator: Benjamin H. Ershoff, Ph.D.

Co-Investigator: Gurwant S. Bajwa, D.V.M., Ph.D.

Institution: Institute for Biological Research
5345 West 102nd Street
Los Angeles, California. 90045

Period Covered: 1 December, 1964 through June 15,1965

Submitted to: NASA Manned Spacecraft Center
General Research Procurement Office
2101 Webster-Seabrook Road
Houston, Texas. 77058

GPO PRICE $ _____

CFSTI PRICE(S) $ _____

Hard copy (HC) 2.50

Microfiche (MF) .75

ff 653 July 65

FACILITY FORM 602

N66 32620 (ACCESSION NUMBER)

72 (PAGES)

CR-65427 (NASA CR OR TMX OR AD NUMBER)

(THRU)

1 (CODE)

04 (CATEGORY)

Date Submitted: July 19, 1965

FOREWARD

The investigations described in this report were carried out during the period of 1 December 1964 to 15 June 1965. The research was supported by Contract No. NAS 9-3905 with NASA Manned Spacecraft Center, Procurement & Contracts Division, General Research Procurement Branch, Houston, Texas. The technical initiator and monitor of the project was Dr. Paul A. LaChance. The technical assistance of Mr. K. S. Dhindsa, L. Slaughter and L. Galpern of the Institute for Biological Research is gratefully acknowledged. Animal experimentation was conducted in accordance with the Principles of Laboratory Animal Care as established by the National Society for Medical Research.

TABLE OF CONTENTS

PAGE

Physiologic effects of dietary clay supplements

A. Introduction..... 1

B. Experimental: Procedure and results.

I. Experiment No. 1: Comparative effects of clay supplement "A" on the increment in body weight and the microscopic appearance of the long bones of rats, hamsters, mice and miniature pigs fed a low calcium, low protein, low fat, non-heat-processed, wheat flour-containing ration similar to diet 256 of McClure..... 4

a. Studies with rats..... 4

b. Studies with hamsters..... 7

c. Studies with mice..... 10

d. Studies with miniature pigs..... 12

II. Experiment No. 2: Comparative effects of calcium carbonate and clay supplement "A" on the increment in body weight and the microscopic appearance of the long bones of rats fed different types of low calcium diets..... 14

a. Comparative effects of calcium carbonate and graded levels of clay supplement "A" on the increment in body weight and the microscopic appearance of the long bones of immature male rats fed a low calcium, low protein, low fat, non-heat-processed, wheat flour-containing ration similar to diet 256 of McClure..... 15

b. Comparative effects of calcium carbonate and graded levels of clay supplement "A" on the increment in body weight and the microscopic appearance of the long bones of immature male rats fed a low calcium, low protein, low fat, rye flour-containing ration.. 17

c. Comparative effects of calcium carbonate and graded levels of clay supplement "A" on the increment in body weight and the microscopic appearance of the long bones of immature male rats fed a purified, calcium-deficient ration containing casein as the source of dietary protein..... 21

TABLE OF CONTENTS

d. Comparative effects of calcium carbonate and graded levels of clay supplement "A" on the increment in body weight and the microscopic appearance of the long bones of immature male rats fed a purified, calcium-deficient ration containing methionine-supplemented soy protein as the source of dietary protein..... 24

III. Experiment No. 3: Comparative effects of clay sample "A" and other clay and soil samples on the weight increment of immature male rats fed a low calcium, low protein, low fat, non-heat-processed, wheat flour-containing ration similar to diet 256 of McClure..... 28

C. Discussion..... 31

D. Summary..... 33

References..... 35

Footnotes to paper..... 36

Legend to figures..... 38

Figures..... 49

A. Introduction

An extensive literature is available which has recently been reviewed by Cooper (1) indicating that the eating of clay has been observed in many peoples and animals in all parts of the world since antiquity. Many of the early writers considered clay-eating a manifestation of perverted appetite and responsible for a wide variety of physical ailments, debility and disease. Christopherson (2) and Mathieu (3) considered the principal danger of earth-eating or clay-eating to be that of swallowing the ova or embryos of intestinal parasites that may be present in these materials. Other writers have reported that clay eating was apparently without deleterious effects and may even have contributed toward well-being and health. Blair (4) described the widespread use of kanwa (earth from a "lick" near Lake Chad) for animals and humans in Nigeria. Long journeys were made to the lick to obtain a tribal supply of this earth, and it was then issued as rations to cattle and humans. Blair noted that from parturition to weaning the nursing mothers received a double ration, the infants being given lumps to suck from eighteen months onward. Lasch (5) reported that earth-eating was widespread in parts of Central Europe, particularly among women and children, and reported a number of the common superstitions concerning it: namely that it stops vomiting in pregnancy, is a remedy for constipation, serves as a specific against syphlis, secures a good posture in the foetus - causes it to "stand up", and the old superstition that it insures fine progeny. French (6) mentions that licking and eating of earth at certain recognized spots by domesticated animals has been such a

common feature of native animal husbandry in many parts of Africa that it is regarded as natural and even essential to health and fertility of livestock. If no edible earths are available locally it is customary to trek animals at regular intervals to areas where the above spots are located or to bring supplies of such soil to the animals. Foster (7) reported that earth or clay eating and other forms of pica in animals are indicative of a dietary deficiency. He noted that pica is prevalent among humans in widely scattered races, being commonest in pregnancy, lactation and the growth period when demands upon nutrition are greatest. From the analogy of natural and experimental cases of pica among animals, he suggested tentatively that the underlying factor in human pica lies in a deficiency in the inorganic constituents of the diet.

That earth or clay-eating is not merely of historical interest is indicated by some very recent references to it. In 1942 Dickens and Ford (8) made a survey of Negro school children in rural Mississippi. Their findings showed that of 207 children, 26% of the boys and 25% of the girls had eaten dirt or clay in the two-week period immediately preceding. A significant relationship was found between dirt and clay eating and the type of food taken, the dirt and clay-eaters being those who had fewer iron-rich foods. In 1952 deCastro (9) reported that " in Bahia, a city of northeastern Brazil, nearly 40% of the school children were found to be suffering from anemia. When a supplement containing iron was added to their diet, the anemia rate dropped in four months to only 3%, confirming the fact that a deficiency was the cause of the disease. In places where this evil is most intense, one finds the strange phenomenon of geophagy or geomania,

the habit of eating earth". This custom, according to deCastro, represents a state of specific hunger. He states that "An analysis of the clays that are eaten as foods in Brazil confirms the fact observed by Cobert in Tunisa, and Batz in the Congo - they are for the most part clays which contain high proportions of iron salts?. There are indications, however, that the beneficial effects of earth or clay eating may be due, at least in part, to factors other than their iron content. Thus Sydenstricker (10) observed that the eating of Kaolin was very common among pellagrins and that "Certain veins of clay were greatly esteemed; they carved it into sticks and ate it like candy". Of possible pertinence to the above is the report by Cooper (1) that "Keepers in the Baltimore Zoo routinely supply to the kangaroos three to four pounds of red clay per week as a dietary supplement. In discussing this with the administrative and veterinary staff of the Zoo they said it is common knowledge among zoo keepers that kangaroos in captivity are liable to develop lesions in the mouth which are more or less comparable to canine black tongue. When this condition in the kangaroo is discovered very early, it can be treated successfully by the administration of the B-complex (untreated, it is rapidly fatal), but it can be avoided entirely by supplying red clay to the animals regularly". Additional data indicating the beneficial effects of clay supplementation have recently been obtained by Ershoff and Bajwa (12) who found that certain batches of clay when incorporated at levels of 2% to 4% in the diet largely counteracted the adverse effects of feeding a low calcium, low protein, low fat, cariogenic ration similar to diet 256 of McClure (13) on the weight increment, caries experience, and bone pathology of rats. The following

experiments were undertaken to obtain further data on the effects of dietary clay supplements on the immature rat, hamster, mouse and miniature pig.

B. Experimental: Procedure and results

Experiment No. 1: Comparative effects of clay supplement "A" on the increment in body weight and the microscopic appearance of the long bones of immature male rats, hamsters, mice and miniature pigs fed a low calcium, low protein, low fat, non-heat processed, wheat flour-containing ration similar to diet 256 of McClure

The basal ration used in these studies consisted of non-heat processed wheat flour, 80%; cerelose, 18%; and Dessicated Liver N.F., 2%; To each kg. of the above were added 5,000 U.S.P. units of vitamin A, 500 U.S.P. units of vitamin D_2 and 100 mg. of alpha-tocopherol acetate. Diet A1 was the unsupplemented basal ration indicated above; diets A2, A3, and A4 were similar but were supplemented with clay sample "A"[1] at levels of 1%, 2%, and 4% of the ration respectively. The latter was incorporated in the diet in place of an equal amount of cerelose.

a. Studies with rats.

Sixty male rats of the Long-Evans strain were selected at an average body weight of 43.5 gm (range 37 to 53 gm) and were divided into four comparable groups of 15 rats each. Animals were placed in metal cages with raised screen bottoms (3 rats per cage) and the four groups were provided with diets A1 to A4 respectively and distilled water ad libitum. The rats were weighed once weekly during the course of the experiment. Animals were sacrificed after 8 weeks of feeding. The hind legs were placed in 10% neutral formalin for fixation, decalcified in 10% nitric acid in 10% formalin, washed with saturated lithium carbonate, dehydrated and

infiltrated in the routine manner, imbedded in paraffin, and sections prepared at 7μ in thickness and stained with hematoxylin and eosin.

In agreement with previous findings (13) the ingestion of a clay supplement significantly improved the weight increment and the microscopic appearance of the long bones of immature rats fed a low calcium, low protein, low fat, non-heat-processed, wheat flour-containing ration similar to diet 256 of McClure. The increment in body weight was proportional to the level of clay supplement fed. The average weight increments in rats in the various groups after 2, 4, 6, and 8 weeks of feeding are summarized in Table 1.

Table 1

Effects of graded levels of clay supplement "A" on the weight increment of immature male rats fed a low calcium, low protein, low fat, non-heat-processed, wheat flour-containing ration (15 animals per group).

Dietary Group	Initial body wt.	Gain in body wt. after the following weeks of feeding			
		2	4	6	8
	gm.	gm.	gm.	gm.	gm.
Basal ration (diet A1)	43.5	26.1	52.5	65.0	80.0
Basal ration + 1% clay supplement "A" (diet A2)	43.5	29.3	64.2	92.3	121.2
Basal ration + 2% clay supplement "A" (diet A3)	43.5	36.0	83.6	125.5	166.7
Basal ration + 4% clay supplement "A" (diet A4)	43.4	39.7	92.2	144.2	187.7

The bones of rats on the unsupplemented basal ration (diet A1) showed gross and microscopic changes typical of rickets. Grossly the tibia and femur were bent, enlarged at the epiphyseal

ends and knobby in appearance due to healed spontaneous fractures. Their marrow cavity was much widened. The articular surfaces had an uneven and somewhat flattened appearance due to under-developed and deficient supporting epiphyseal trabecular bone. Spontaneous fractures observed regularly were healed and were accompanied by moderate to marked chondromatosis and periosteal thickening. Pathologic changes occurred in all areas of the bones and were marked by severe cancellous degeneration of the cortical bone (Fig. 1), defective and deficient modelling of the spongiosa bone in the metaphysis (Fig. 4), abnormal bone regeneration, osteoid replacement and deficient mineralization of the formed bone, generalized osteoblastic hyperplasia, marked decrease in the hematopoietic marrow (Fig. 4,7), compensatory thickening and hyperplasia of the periosteum, and generalized congestion of the marrow. The cortical cancellous changes were regularly more severe along the convex aspect of the tibial and femoral shaft (Fig. 1). The epiphyseal plate was considerably thickened due to lack of ossification of its columns. The bone growth was usually so defective that the entire metaphysis was seen as a mere network of osteoid and hyperplastic osteoblasts (Fig. 4). These changes often extended deep into the diaphysis involving the entire shaft. The marrow everywhere was sparse in hematopoietic tissue and consisted mainly of fatty tissue and engorged capillaries (Fig. 7).

In contrast, the bones of rats fed the basal ration supplemented with 4% clay supplement "A" (diet A4) were normal in appearance with well developed compact cortical bone (Fig.2), a normal looking epiphyseal plate supported by normally modelled spongiosa bone (Fig. 5), and active hematopoietic marrow (Fig 8).

The cortical bone was virtually equal in thickness in the convex and concave side of the shaft of the femur. A significant improvement in the appearance of the femur and tibia both grossly and microscopically over that of rats fed the basal ration (diet A1) was also observed in rats fed the basal ration plus 1% and 2% clay supplement "A" (diets A2 and A3) respectively). The bone in the latter groups was not as well developed and modelled however, as that of rats fed clay supplement "A" at a 4% level (diet A4). Minimal rachitic changes were present in rats fed clay supplement "A" at a 1% level (diet A2)(Fig. 3 and 6) but not at the 2% level of supplementation (diet A3). The hematopoietic tissue although well developed in rats fed diets A2 and A3 compared to that of rats fed the unsupplemented basal ration (diet A1), was less abundant than that of rats fed the 4% clay supplement (diet A4)(Fig 8 and 9). No spontaneous fractures were observed in any of the rats fed clay supplement "A" at any level of feeding.

b. Studies with hamsters.

Sixty male hamsters[2] were selected at an average body weight of 41.3 gm (range 36 to 49 gm) and were divided into four comparable groups of 15 animals each. Animals were placed in metal cages with raised screen bottoms (3 hamsters per cage) and the four groups were provided with diets A1 to A4 respectively and distilled water ad libitum. The hamsters were weighed once weekly during the course of the experiment. Animals were sacrificed after 8 weeks of feeding. Histological sections of the hind legs were prepared by the same procedure as was employed in the rat experiments (section a, above). In agreement with findings in the rat experiments the ingestion of clay supplement "A" significantly improved the weight increment and the microscopic

appearance of the long bones of immature male hamsters fed the low calcium, low protein, low fat, non-heat-processed, wheat flour-containing ration similar to diet 256 of McClure. In contrast to findings in rats, however, clay supplement "A" at a 1% level of supplementation (diet A2) did not differ significantly from the 2% and 4% levels of supplementation (diets A3 and A4, respectively) insofar as effects on increment in body weight were concerned. The average weight increments of hamsters in the various groups after 2,4,6, and 8 weeks of feeding are summarized in Table 2.

Table 2

Effects of graded levels of clay supplement "A" on the weight increment of immature male hamsters fed a low calcium, low protein, low fat, non-heat processed, wheat flour-containing ration (15 animals per group).

Dietary Group	Initial body wt.	Gain in body wt. after the following weeks of feeding			
		2	4	6	8
	gm.	gm.	gm.	gm.	gm.
Basal ration (diet A1)	41.3	20.5	30.3	36.1	35.6
Basal ration + 1% clay supplement "A" (diet A2)	41.3	20.3	39.2	51.7	59.0
Basal ration + 2% clay supplement "A"	41.3	25.3	42.6	53.7	60.8
Basal ration + 4% clay supplement "A" (diet A4)	41.2	21.2	39.4	53.6	62.8

The bones of hamsters on the unsupplemented basal ration (diet A1) exhibited gross and microscopic changes typical of rickets but less marked than those of rats fed a similar diet. Normal modelling of the bone was generally preserved excepting moderate enlargement of the epiphyseal ends. The bones were smaller than normal and had some irregularity of their articular

surfaces due to malformed and underdeveloped supporting trabecular bone. The major effects noted were on the hematopoietic marrow which was replaced in large part by fatty tissue (Fig. 10 and 16). The cortical bone was thin and porous and exhibited moderate chondromatosis and thickening and hyperplasia of the periosteum along the anterior and convex aspect of the shaft.(Fig. 10). There was marked disruption of the normal architecture of the spongiosa bone due to defective growth and modelling of its supporting epiphyseal processes. The metaphysis was transformed into a network of thin, malformed and irregular trabeculae, hyperplastic osteoblasts and severely engorged blood vessels (Fig. 13). These changes were contiguous with similar lesions in the diaphysis. The trabeculae here and in the metaphysis were composed of thin osseous bone, persistent chondroblasts and abundant osteoid surrounded by multiple layers of proliferating osteoblasts (Fig. 13). The osteoclastic activity appeared to be either minimal or completely absent. The bony cortex along the posterior or concave aspect of the shaft although thin and less cancellous contained prominently widened canals. Slight to moderate periosteal thickening and hyperplasia were also present. (Fig. 10)

In contrast, the bones of hamsters fed the basal ration supplemented with 1% clay supplement "A" (diet A2) had only minimal rachitic changes and a near normal appearance. A marked increase in hematopoietic tissue was apparent throughout. Bone growth and modelling of the spongiosa bone were only slightly abnormal and the supporting epiphyseal processes had assumed a normal downward growth pattern and thickness. There was marked reduction of osteoplastic activity adjacent to the trabeculae

which showed well developed bone and only a slight amount of osteoid. The epiphyseal plate had deeper penetrating blood capillaries and essentially normal thickness. The spongiosa bone contained abundant hematopoietic tissue. There was marked reduction of periosteal thickening except along the cancellous cortex of the anterior or convex part of the midshaft. Supplementation with 4% clay supplement "A" (diet A4) promoted bone growth and development to the fullest extent. The bones of hamsters in the latter group showed normal modelling, thick, well developed cortical bone (Fig. 11), abundant hematopoietic tissue (Fig. 11 and 17), normal bone growth (Fig. 14), and well developed trabecular bone (Fig. 14). The bones of hamsters fed the basal ration supplemented with 2% clay supplement "A" (diet A3) were devoid of rachitic changes and were normal in appearance but were less developed than those of hamsters fed the 4% clay supplement (diet A4)(Fig. 12, 15 and 18).

c. Studies with Mice.

Sixty male mice of the Swiss Webster strain were selected at an average body weight of 12.7 gm.(range 10.6 to 14.2 gm) and were divided into four comparable groups of 15 animals each. Animals were placed in metal cages with raised screen bottoms (5 mice per cage) and the four groups were provided with diets A1 to A4 respectively and distilled water ad libitum. The mice were weighed once weekly during the course of the experiment. Animals were sacrificed after 8 weeks of feeding. Histologic sections of the hind legs were prepared by the same procedure as was employed in the rat experiment (section a, above). Findings indicate that clay supplement "A" at all levels of feeding resulted in a significantly greater weight increment than occurred

in mice fed the unsupplemented basal ration (diet A1). The growth promoting effects of the clay supplement were particularly marked during the first 4 weeks of feeding. As in the case of hamsters (section b above) the weight increment of mice fed the basal ration + 1% clay supplement "A" (diet A2) did not differ significantly from that of mice fed the 2% or 4% clay supplements (diets A3 and A4 respectively). The average weight increments of mice in the various groups after 2,4,6, and 8 weeks of feeding are summarized in Table 3.

Table 3

Effects of graded levels of clay supplement "A" on the weight increment of immature male mice fed a low calcium, low protein, low fat, non-heat-processed, wheat flour-containing ration.

Dietary Group (15 animals per group)	Initial body wt.	Gain in body wt. after the following weeks of feeding.			
		2	4	6	8
	gm	gm	gm	gm	gm
Basal ration (diet A1)	12.7	4.5	5.4 (13)	7.2 (13)	8.5 (13)
Basal ration + 1% clay supplement "A" (diet A2)	12.7	9.6	14.1	17.0	17.1
Basal ration + 2% clay supplement "A" (diet A3)	12.7	7.5	11.7	13.9	15.4
Basal ration + 4% clay supplement "A" (diet A4)	12.6	10.7	13.7	15.3	15.8

The values in parenthesis indicate the number of animals which survived and on which data are based, when less than the original number per group.

Among the various species of animals used in this study, mice fed the unsupplemented basal ration (diet A1) showed the least changes in respect to the microscopic appearance of the bone. Only mild rachitic changes were present as evidenced by a slightly

defective bone growth pattern (Fig. 21). Otherwise, in respect to the cortical and trabecular bone, hematopoietic tissue and modelling, the bones were well developed and normal in appearance (Fig. 19). The addition of 1% clay supplement "A" to the basal ration prevented the early rachitic growth defect and promoted bone development. Higher levels of clay supplementation (diets A3 and A4) promoted bone development in excess of that obtained on diet A2, the effects being proportional to the amount of clay added (Fig. 20 and 22).

d. Studies with miniature pigs.

Eight male miniature pigs[3] were selected at an average body weight of 26.7 lb. (range 23 to 31 lbs.) and were divided into two comparable groups of 4 animals each. Animals were placed in wooden pens (4' in width, 6' in length, and 42" in height), containing 2 pigs per pen. The pens had solid wooden bottoms covered with wood shavings which were changed daily. One group was fed the unsupplemented basal ration (diet A1); the other, the basal ration + 2% clay supplement "A" (diet A3). The diets were mixed with distilled water immediately before feeding into a semi-liquid mash. These diets as well as an additional supply of distilled water were provided ad libitum daily. The pigs were weighed at 2 week intervals during the course of the experiment. Animals were sacrificed after 12 weeks of feeding. One hind limb of each pig was removed at the hip joint at the time of sacrifice and x-ray pictures taken for examination. Histological sections of the other leg were prepared at the proximal end of the tibia for microscopic examination. In contrast to findings in rats, hamsters and mice, miniature pigs fed clay supplement "A" at a 2%

level in the ration (diet A3) did not exhibit an increment in body weight significantly greater than that obtained on the unsupplemented basal ration (diet A1). The average weight increments of miniature pigs on the test diets during the 12 week experimental period are summarized in Table 4.

Table 4

Effects of clay supplement "A" when fed at a 2% level in the ration on the weight increment of immature male pigs fed a low calcium, low protein, low fat, non-heat processed, wheat flour-containing ration (4 animals per group)

Dietary Group	Initial body wt.	Gain in body wt. after the following weeks of feeding					
		2	4	6	8	10	12
	lb	lb	lb	lb	lb	lb	lb
Basal ration (diet A1)	27.1	3.8	9.8	14.1	19.3	24.3	28.5
Basal ration + 2% supplement "A" (diet A3)	26.3	3.8	8.2	13.1	18.7	26.2	30.3

The miniature pigs on the unsupplemented basal ration (diet A1) exhibited gross findings suggestive of early rickets. Both the tibia and femur had enlarged joints due to widened epiphyseal ends and exhibited decreased density in the x-ray film. The femoral neck was shortened and the head increased in diameter (Fig. 23 and 24). Histologically, the tibial shaft showed demineralization, absorption and increase in osteoid as evidence of early osteoporotic changes (fig. 25). The cortical and trabecular bone was thin throughout. Bone growth was defective resulting in malformed spongiosa bone, especially its supporting epiphyseal processes (Fig. 27). The spongiosa bone showed marked compensatory fibroblastic proliferation, a defective trabecular modelling, marked congestion and scant hematopoietic tissue and

engorged blood vessels (Fig. 29). In contrast to the above miniature pigs fed the basal ration + 2% clay supplement "A" (diet A3) had bones with only slight rachitic alterations. On x-ray examination they were denser, more normally modelled and more developed than those of pigs fed the unsupplemented basal ration (diet I)(Figs. 23 and 24). The trabecular bone was thicker and more compact but not fully developed (Fig. 26). The epiphyseal trabecular and spongiosa bone were more developed and normally modelled (Fig. 28). Bone growth was more normal as shown by deeper capillary penetration, moderate ossification, reduced thickness, and more normally modelled supporting spongiosa processes of the eiphyseal plate (Fig.30). The marrow contained a moderate amount of hematopoietic tissue and near normal vasculature (Fig 30).

II. Experiment No. 2: Comparative effects of calcium carbonate and clay supplement "A" on the increment in body weight and the microscopic appearance of the long bones of immature male rats fed different types of low calcium diets.

Four basal low-calcium diets were employed in the present experiment: Diets A1, B1, C1, and D1: diet A1 was identical to the unsupplemented basal ration used in Experiment No. 1 and was a low calcium, low protein, low fat, non-heat-processed, wheat flour-containing ration similar to diet 256 of McClure. Diet B1 was similar to diet A1 but rye flour was incorporated in the ration in place of the non-heat-processed wheat flour. The composition of diet B1 was: Rye flour, 80%; cerelose, 18%; and Desiccated Liver N.F., 2%. To each kg. of the above were added 5,000 U.S.P. units of vitamin A, 500 U.S.P. units of vitamin D_2, and 100 mg. of alpha-tocopherol acetate. Diet C1 was a highly purified, calcium-deficient ration containing casein as the source of dietary protein. It consisted of: Vitamin-Free

Test Casein[4], 18%; cottonseed oil, 5%;calcium-free salt mixture[5], 3%; and sucrose, 74%. To each kg. of the above were added the following vitamins: thiamine hydrochloride, 4 mg; riboflavin, 4 mg.; pyridoxine hydrochloride, 4 mg; calcium pantothenate, 40 mg; nicotinic acid, 100 mg.; ascorbic acid, 200 mg.; biotin, 1 mg.; folic acid, 2 mg.; para-aminobenzoic acid, 200 mg.; inositol, 400 mg.; vitamin B_{12}, 100 μg; 2-methyl-1, 4-naptho-quinone, 5 mg; choline chloride, 2 gm; vitamin A, 5,000 U.S.P. units; vitamin D_2, 500 U.S.P. units; and alpha-tocopherol acetate 100 mg. The vitamins were added in place of an equal amount of sucrose. Diet D1 was similar to diet C1 but contained methionine-supplemented soy protein in place of casein as the source of dietary protein. It consisted of Soya Assay Protein[4], 18%; cottonseed oil, 5%; calcium-free salt mixture,[5] 3%;dl-methionine, 0.375% and sucrose 73.625%. To each kg. of the above were added the same vitamin supplements as were added to diet C1. The vitamin supplements and dl-methionine were added in place of an equal amount of sucrose.

a. Comparative effects of calcium carbonate and graded levels of clay supplement "A" on the increment in body weight and the microscopic appearance of the long bones of immature male rats fed a low calcium, low protein, low fat, non-heat-processed, wheat flour-containing ration similar to diet 256 of McClure.

Sixty-six male rats of the Long-Evans strain averaging 43.5 gm. in body weight (range 37-53 gm.) were employed in the present experiment. Animals were divided into 5 groups, 4 of which consisted of 15 animals each; the 5th group of 6 rats. One group of 15 rats was fed the unsupplemented basal ration (diet A1). Three additional groups of 15 rats each were fed the above basal ration supplemented with 1%, 2% and 4% clay supplement "A"

(diets A2, A3, A4 respectively). The above 4 groups were the same animals that were reported on under section "A" of Experiment No. 1. The 5th group was fed diet A5 which consisted of the above basal ration plus 3 gm. $CaCO_3$ per kg. of diet which was added in place of an equal amount of cerelose. This amount of $CaCO_3$ contained the same amount of calcium present in the clay supplement "A" incorporated in a kg. of diet A4. Animals were placed in metal cages with raised screen bottoms (3 rats per cage) and were provided with the test diets and distilled water ad libitum. The rats were weighed once weekly during the course of the experiment. Animals were sacrificed after 8 weeks of feeding and histological sections of the hind legs prepared as described under section a, experiment 1. Findings indicate that whereas clay supplement "A" at levels of 1%, 2% and 4% of the ration (diets A2, A3 and A4 respectively) resulted in a significant increment in body weight over that obtained on the unsupplemented basal ration (diet A1), the $CaCO_3$ supplement (diet A5) was ineffective in promoting an increment in body weight. The average weight increments of rats in the various groups after 2, 4, 6, and 8 weeks of feeding are summarized in Table 5.

Table 5

Comparative effects of calcium carbonate and graded levels of clay supplement "A" on the increment in body weight of immature male rats fed a low calcium, low protein, low fat, non-heat processed, wheat flour-containing ration similar to diet 256 of McClure.

Dietary Group	No. of rats	Initial body wt.	Gain in body weight after the following weeks of feeding			
			2	4	6	8
		gm.	gm	gm	gm	gm
Basal Ration (diet A1)	15	43.5	26.1	52.5	65.0	80.0
Basal Ration + 1% clay supplement "A" (diet A2)	15	43.5	29.3	64.2	92.3	121.2
Basal ration + 2% clay supplement "A" (diet A3)	15	43.5	36.0	83.6	125.5	166.7
Basal ration + 4% clay supplement "A" (diet A4)	15	43.3	39.7	92.2	144.2	187.7
Basal ration + 3 gm. $CaCO_3$ per kg. of diet (diet A5)	6	43.6	27.8	43.6	63.0	73.8

The microscopic appearance of rats fed diets A1, A2, A3 and A4 was previously reported under section a, experiment 1 (Fig.1 to 9). Supplementation with $CaCO_3$ (diet A5) resulted in a moderate improvement in the appearance of bone (Fig. 31, 32, and 33) over that of rats fed the unsupplemented basal ration (diet A1). Rats fed the $CaCO_3$ supplement had bones which were similar in appearance to those of rats fed the 1% clay supplement (diet A2). $CACO_3$ supplementation, however, resulted in no improvement in the appearance of hematopoietic tissue over that of rats fed the unsupplemented basal ration in contrast to the well developed hematopoietic tissue in rats fed the 1% clay supplement (diet A2) (Fig. 9 and 33).

b. Comparative effects of calcium carbonate and graded levels of clay supplement "A" on the increment in body weight and the microscopic appearance of the long bones of immature male rats fed a low calcium, low protein, low fat, rye flour-containing ration.

Fifty-four male rats of the Long-Evans strain averaging 41.7 gm. in body weight (range 36 to 50 gm) were employed in the present experiment. Animals were divided into 5 groups, 4 of which consisted of 12 animals each; the 5th group of 6 rats. One group of 12 rats was fed the unsupplemented basal ration (diet B1). Three additional groups of 12 rats each were fed the above basal ration supplemented with 1%, 2% and 4% clay supplement "A" (diets B2, B3 and B4 respectively). The 5th group was fed diet B5 which consisted of the above basal ration plus 3 gm. $CaCO_3$ per kg. of diet which was added in place of an equal amount of cerelose. This amount of $CaCO_3$ contained the same amount of calcium present in the clay supplement "A" incorporated in a kg. of diet B4. Animals were placed in metal cages with raised screen bottoms (3 rats per cage) and were provided with the test diets and distilled water ad libitum. The rats were weighed once weekly during the course of the experiment. Animals were sacrificed after 8 weeks of feeding and histological sections of the hind legs prepared as described under section a, experiment 1, above. Findings indicate that the ingestion of clay supplement "A" significantly improved the weight increment and the microscopic appearance of the long bones of immature male rats fed a low calcium, low protein, low fat, rye flour-containing ration. The increment in body weight was prpportional to the level of clay supplement fed. In contrast to the effects obtained with clay supplement "A", $CaCO_3$ when fed at a level of 3 gm. per kg. of diet was without activity in promoting an increment in body weight. On the contrary, the weight increment of rats fed the $CaCO_3$ supplement was less than that of rats fed the unsupplemented basal ration (diet B1). The average weight increments of rats fed diets B1-B5 after 2, 4, 6, and 8 weeks of

feeding are summarized in Table 6.

Table 6

Comparative effects of calcium carbonate and graded levels of clay supplement "A" on the increment in body weight of immature male rats fed a low calcium, low protein, low fat, rye flour-containing ration.

Dietary Group	No. of Rats.	Initial body wt.	Gain in body weight after the following weeks of feeding: 2	4	6	8
		gm.	gm	gm	gm	gm
Basal ration (diet B1)	12	41.7	24.0	42.1	55.7	78.9
Basal ration + 1% clay supplement "A" (diet B2)	12	41.6	23.7	54.7	81.7	107.3
Basal ration + 2% clay supplement "A" (diet B3)	12	41.7	31.2	71.1	110.3	144.9
Basal ration + 4% clay supplement "A" (diet B4)	12	41.7	38.3	81.3	130.6	164.4
Basal ration + 3 gm $CaCO_3$ per kg. of diet (diet B5)	6	41.6	24.7	38.7	48.2	54.7

The bones of rats on the unsupplemented basal ration (diet B1) showed gross and microscopic changes typical of rickets. Grossly the tibia and femur were bent, malformed and enlarged at their epiphyseal ends. Their articular surfaces were uneven and somewhat flattened in appearance due to thin articular cartilage supported by thin and underdeveloped epiphyseal trabecular bone. Spontaneous fractures were common giving the bone a knobby appearance. The lesions were generalized and characterized by marked thinning, porosity, demineralization and increased osteoid of the cortical bone, especially along the anterior or convex aspect of the shaft (Fig. 34), widening and thickening of the epiphyseal

plate, defective and deficient bone growth (fig 38), and defective modelling of the trabeculae and epiphyseal processes of the spongiosa bone (Fig. 38). The marrow was deficient in hematopoietic tissue and was replaced by fatty tissue (Fig. 42). The hematopoietic tissue of rats fed diet B1,however, was more abundant than that of rats fed diet A1 (Fig. 7 and 42). The above changes were essentially similar to but less severe than those observed in rats fed the unsupplemented basal ration (diet A1) (Fig. 1, 4, and 7).

In contrast to the above the bones of rats fed the basal ration supplemented with 4% clay supplement "A" (diet B4) had fully and well developed bones with compact and mineralized cortical bone (Fig. 35), normal appearing spongiosa, epiphyseal trabecular bone and hematopoietic marrow (Fig. 39 and 43); A significant improvement in the appearance of the femur and tibia both grossly and microscopically over that of rats fed the basal ration (diet B1) was also observed in rats fed the basal ration plus 1% and 2% clay supplement "A" (diets B2 and B3 respectively)(Fig.36,40, and 44).The bone in the latter groups was not as well developed and modelled as that of rats fed clay supplement "A" at a 4% level (diet B4) and some rachitic changes were present in these groups, particularly in rats fed the 1% clay supplement (diet B2). No spontaneous fractures were observed, however, in any of the rats fed clay supplement "A" and all animals fed rations containing this supplement (Diets B2,B3 and B4) had bone marrows with abundant hematopoietic tissue. Rats fed the $CaCO_3$ supplement (diet B5) had bones which were similar in microscopic appearance to that of rats fed the 2% clay supplement (diet B3) (Fig.36,37,40,41,44, and 45). Little if any improvement was observed however, in the amount of hematopoietic tissue in rats fed diet B5 over that of rats fed the basal ration (diet B1)

C. Comparative effects of calcium carbonate and graded levels of clay supplement "A" on the increment in body weight and the microscopic appearance of the long bones of immature male rats fed a purified, calcium-deficient ration containing casein as the source of dietary protein.

Fifty-four male rats of the Long-Evans strain averaging 41.8 gm in body weight (range 36 to 50 gm) were employed in the present experiment. Animals were divided into 5 groups, 4 of which consisted of 12 animals each; the 5th group of 6 rats. One group of 12 rats was fed the unsupplemented basal ration (diet C1). Three additional groups of 12 rats each were fed the basal ration supplemented with 1%, 2% and 4% clay supplement "A" (diets C2, C3 and C4, respectively). The 5th group was fed diet C5 which consisted of the above basal ration plus 3 gm. $CaCO_3$ per kg. of diet which was added in place of an equal amount of sucrose. This amount of $CaCO_3$ contained the same amount of calcium present in the clay supplement "A" incorporated in a kg. of diet C4. Animals were placed in metal cages with raised screen bottoms (3 rats per cage) and were provided with the test diets and distilled water ad libitum. The rats were weighed once weekly during the course of the experiment. During the 5th week of feeding a number of animals fed the unsupplemented basal ration (diet C1) lost weight and during the ensuing 2 weeks 7 of the 12 rats in this group died. The experiment was accordingly terminated and animals sacrificed after 7 weeks of feeding. Histological sections of the hind legs were prepared as described under section a, experiment 1. Findings indicate that the ingestion of clay supplement "A" significantly improved the weight increment and the microscopic appearance of the long bones of immature male rats fed a purified, calcium-deficient ration containing casein as the source of dietary protein. The increment in body weight was proportional to the level of clay supplement fed.

In contrast to the effects obtained on diet A5 and diet B5, $CaCO_3$ when fed at a level of 3 gm. per kg. of diet also promoted a significant increment in body weight over that obtained on the unsupplemented basal ration (diet C1) although less than that obtained with 4% clay supplement "A" (diet C4). The average weight increments of rats fed diets C1-C5 after 2,4,6, and 7 weeks of feeding are summarized in Table 7.

Table 7

Comparative effects of calcium carbonate and graded levels of clay supplement "A" on the increment in body weight of immature male rats fed a purified, calcium-deficient ration containing casein as the source of dietary protein.

Dietary Group	No. of Rats	Initial body wt.	Gain in body weight after the following weeks of feeding. 2	4	6	7
		gm	gm	gm	gm	gm
Basal ration (diet C1)	12	41.8	53.6	79.5	73.4 (9)	82.2 (5)
Basal ration + 1% clay supplement "A" (diet C2)	12	41.8	56.0	101.8	126.0	137.4
Basal ration + 2% clay supplement "A" (diet C3)	12	41.8	58.8	122.7	176.5	195.5
Basal ration + 4% clay supplement "A" (diet C4)	12	41.7	66.0	144.7	210.4	231.7
Basal ration + 3 gm $CaCO_3$ per kg. of diet (diet C5)	6	41.8	58.2	123.2	180.5	200.7

The values in parenthesis indicate the number of animals which survived and on which data are based when less than the original number per group.

The bones of rats on the unsupplemented basal ration (diet C1) showed severe rachitic changes. The femur and tibia were markedly bent and deformed with epiphyseal ends about twice the normal size.

The bones had a knobby appearance due to multiple spontaneous fractures. The articular surfaces were dented and prominently flattened. Microscopically these bones were so malformed that the metaphysis and diaphysis were indistinguishable in appearance consisting of a network of trabecular osteoid, hyperplastic osteoblasts and severely congested vessels. The cortical and trabecular bone throughout were reduced to a thin lamina of osteoid surrounded by layers of hyperplastic osteoblasts (Fig. 46). The epiphyseal plate was 2 to 3 times normal width and was devoid of penetrating capillaries. The epiphyseal supporting processes of the spongiosa were poorly developed (Fig. 50). The marrow cavity was absent and was largely replaced by a network of osteoid tissue with the hematopoietic tissue severely decreased (Fig. 50). Moderate to severe chondromatosis were noted adjacent to the fractured bone. The blood vessels were generally enlarged and had a cavernous appearance. The periosteum was increased in thickness and hyperplastic. In contrast to the above, rats fed the basal ration plus 4% clay supplement "A" (diet C4) had well developed bones with thick and mineralized cortical and trabecular bone (Fig. 47); normal bone growth and modelling of the spongiosa bone and supporting epiphyseal processes (Fig. 51) and abundant hematopoietic tissue (Fig. 47). No spontaneous fractures were observed in any of the rats in this group. A significant improvement in the appearance of the femur and tibia both grossly and microscopically over that of rats fed the basal ration (diet C1) was also observed in rats fed the basal ration plus 1% and 2% clay supplement "A" (diets C2 and C3 resp.) (Fig.48 and 52). The bones in the latter groups were not as well developed and modelled as that of rats fed clay supplement "A" at a 4% level (diet C4) and a number of rachitic changes were present

in these groups, particularly in rats fed the 1% clay supplement (diet C2). Spontaneous fractures were also observed in a number of rats fed the 1% and 2% clay supplements. Rats fed the $CaCO_3$ supplement (diet C5) also showed a significant improvement in the appearance of the femur and tibia both grossly and microscopically (Fig 49 and 53) over that of rats fed the basal ration (diet C1) but were less well developed than those fed the 4% clay supplement (diet C4). No fractures were observed in any of rats in this group. The bones of rats fed diet C5 were intermediate in appearance between those of rats fed the 2% and 4% clay supplements (diets C3 and C4 respectively.

d. Comparative effects of calcium carbonate and graded levels of clay supplement "A" on the increment in body weight and the microscopic appearance of the long bones of immature male rats fed a purified, calcium-deficient ration containing methionine-supplemented soy protein as the source of dietary protein.

Fifty-four male rats of the Long-Evans strain averaging 41.9 grams in body weight (range 36 to 51 gm) were employed in the present experiment. Animals were divided into 5 groups, 4 of which consisted of 12 animals each; the 5th group of 6 rats. One group of 12 rats was fed the unsupplemented basal ration (diet D1). Three additional groups of 12 rats each were fed the basal ration supplemented with 1%, 2%, and 4% clay supplement "A" (diets D2, D3, and D4 respectively). The 5th group was fed diet D5 which consisted of the above basal ration plus 3 gm. $CaCO_3$ per kg. of diet which was added in place of an equal amount of sucrose. This amount of $CaCO_3$ contained the same amount of calcium present in the clay supplement "A" incorporated in a kg. of diet D4. Animals were placed in metal cages with raised screen bottoms (8 rats per cage) and were provided with test diets and distilled water ad libitum. The rats were weighed once weekly during the course of the experiment. During

the 5th week of feeding as was the case in rats fed diet C1 a number of animals fed the unsupplemented basal ration (diet D1) lost weight and during the ensuing 2 weeks 6 of the 12 rats in this group died. The experiment was terminated after 7 weeks of feeding, animals sacrificed, and histological sections of the hind legs prepared as described under section a, experiment 1. Findings indicate that the ingestion of clay supplement "A" significantly improved the weight increment and the microscopic appearance of the long bones of immature male rats fed a purified, calcium-deficient ration containing methionine-supplemented soy protein as the source of dietary protein. The increment in body weight was proportional to the level of clay supplement fed. $CaCO_3$ when fed at a level of 3 gm. per kg. of diet promoted an increment in body weight comparable to that obtained with 4% clay supplement "A". The average weight increments of rats fed diets D1-D5 after 2, 4, 6, and 7 weeks of feeding are summarized in Table 8.

Table 8

Comparative effects of calcium carbonate and graded levels of clay supplement "A" on the increment in body weight of immature male rats fed a purified, calcium-deficient ration containing methionine-supplemented soy protein as the source of dietary protein.

Dietary Group	No. of Rats	Initial body wt.	Gain in body weight after the following weeks of feeding. 2	4	6	8
		gm	gm	gm	gm	gm
Basal ration (diet D1)	12	41.9	60.0	89.6 (11)	90.9 (10)	82.3 (6)
Basal ration + 1% clay supplement "A" (diet D2)	12	41.9	47.8	109.3	148.7	162.4
Basal ration + 2% clay supplement "A" (diet D3)	12	41.8	56.7	130.2	193.3	211.4
Basal ration + 4% clay supplement "A" (diet D4)	12	41.8	66.7	145.3	219.9	244.4
Basal ration + 3 gm. $CaCO_3$ per kg. of diet (diet D5)	6	41.9	56.2	141.7	217.2	241.7

The values in parenthesis indicate the number of animals which survived and on which data are based when less than the original number per group.

Histologically the bones of rats fed the basal ration (diet D1) although rachitic were significantly better developed than those of rats fed the purified basal ration (diet C1). The cortical bone was less porous; it was wider and more mineralized than that of rats on the latter diet (Fig. 54). The epiphyseal plate was decreased in width and thickness and was supported by better formed spongiosa bone (Fig. 57). The marrow contained more hematopoietic tissue and was less congested (Fig. 54). Spontaneous fractures were observed however, in all rats fed the basal ration (diet D1). In general, rats fed the latter ration were comparable both grossly and in

microscopic appearance to those fed diet A1. Rats fed the basal ration plus 4% clay supplement "A" (diet D4) were normal in appearance with well developed compact bone (Fig. 55 and 58). A significant improvement in the appearance of the femur and tibia both grossly and microscopically over that of rats fed the basal ration (diet D1) was also observed in rats fed the basal ration plus 1% and 2% clay supplement "A" (diets D2 and D3 respectively). The bone in the latter groups was not as well developed and modelled, however, as that of rats fed clay supplement "A" at a 4% level (diet D4). Minimal rachitic changes were present in rats fed clay supplement "A" at a 1% level (diet D2) but not at the 2% level of supplementation (diet D3). The hematopoietic tissue although well developed in rats fed diets D2 and D3 compared to that of rats fed the unsupplemented ration (D1) was less abundant than that of rats fed the 4% clay supplement (diet D4). No spontaneous fractures were observed in any of the rats fed clay supplement "A" at any level of feeding. Rats fed the $CaCO_3$ supplement (diet D5) also showed a significant improvement in the appearance of the femur and tibia both grossly and microscopically (Fig. 56 and 59) over that of rats fed the basal ration (diet D1) but were less well developed than those fed the 4% clay supplement (diet D4). No fractures were observed in any of the rats fed diet D5. These animals were intermediate in appearance between those fed the 2% and 4% clay supplements (diet D3 and D4, respectively).

III. Experiment No. 3: Comparative effects of clay sample "A" and other clay and soil samples on the weight increment of immature male rats fed a low calcium, low protein, low fat, non-heat-processed, wheat flour-containing ration similar to diet 256 of McClure.

One hundred and four male rats of the Long-Evans strain were selected at an average body weight of 44.2 gm(range 39 to 52 gm) and were divided into 13 comparable groups of 8 animals each. One group was fed the unsupplemented basal ration (diet A1); the others were fed a similar ration plus the various supplements indicated in Table 9. The test supplements were incorporated in the diets in place of an equal amount of cerelose. Animals were placed in metal cages with raised screen bottoms and were provided the various diets and distilled water ad libitum. Rats were weighed once weekly during the course of the experiment. Data were obtained on the average weight increment of rats in the various groups over a 6 week period. Results are summarized in Table 9.

Table 9

Comparative effects of clay sample "A" and other clay and soil samples on the weight increment of immature male rats fed a low calcium, low protein, low fat, non-heat-processed, wheat flour-containing ration similar to diet 256 of McClure (8 animals per group).*

Dietary Group	Initial body wt.	Gain in body weight after the following weeks of feeding. 2	4	6
	gm.	gm.	gm.	gm.
Basal ration (diet A1)	44.6	22.8	48.5	62.0
Basal ration + following supplements:				
2% clay supplement "A"	44.0	34.6	74.1	109.6
2% clay supplement "B"	44.0	30.0	68.4	101.1
2% clay supplement "C"	44.1	26.7	63.7	96.2
2% clay supplement "D"	44.0	28.8	63.4	95.6
2% clay supplement "E"	44.0	29.0	60.0	90.9
2% clay supplement "F"	44.0	23.9	51.1	72.5
2% bentonite	44.6	27.8	63.0	96.1
2% kaolin	44.4	24.4	47.5	64.7
2% ditch bank dirt	44.0	22.8	48.8	67.8
2% top soil	44.2	21.8	46.3	62.2
2% beach sand	44.1	21.2	41.0	57.8
2% silica	44.2	22.4	46.5	63.8

* All clay samples employed in this experiment were ground to a particle size that passed through a # 12 screen. Clay sample "A" was the same material used in experiments No. 1 and 2. It was a pinkish tan clay obtained from a deposit near Brawley, California. Clay sample "B" was a grayish-white clay obtained from the Coyote Mountain area 35 miles west of Brawley. Clay sample "C" was a

brownish clay obtained approximately 200 yards east of clay sample "A". Clay sample "D" was a tan colored clay obtained approximately 1/2 mile south of clay sample "A". Clay sample "E" was a pinkish tan clay obtained approximately 3/4ths of a mile south east of clay sample "A". Clay sample "F" was a pinkish tan clay obtained from an area approximately 5 miles south of clay sample "A". The ditch bank dirt was obtained from an area near Brawley, California. The top soil was obtained from grounds adjacent to the Institute for Biological Research at its former location in Culver City, Calif. The beach sand was obtained from Santa Monica, California.

Findings indicate that the various clays differed significantly in growth-promoting activity. The most active material tested was clay sample "A" which promoted a highly significant increment in body weight over that obtained on the unsupplemented basal ration (diet A1) whereas clay sample "F" and kaolin were virtually devoid of growth-promoting activity. It is of interest that clay samples "C", "D", and "E" which were obtained within one mile of the clay sample "A" deposit were consistently less active than clay sample "A" in growth-promoting activity. No correlation was observed between the color of the clay and its effect on increment in body weight. Clay sample "B" which was only slightly less active than clay sample "A" was grayish white in color in contrast to the pinkish tan appearance of clay supplement "A". Furthermore, clay sample "F" which had little if any growth-promoting activity was indistinguishable from clay sample "A" in appearance. Bentonite had significant growth-promoting activity although less than clay supplement "A". Silica and the ditch bank dirt, top soil and beach sand supplements were devoid of activity.

C. Discussion:

Findings indicate that clay supplement "A" when incorporated at levels of 1%, 2% and 4% of the diet caused a highly significant increment in body weight and prevented the occurrence of pathological changes in the long bones of immature rats, hamsters and mice fed a low calcium, low protein, low fat, non-heat-processed, wheat flour containing ration similar to diet 256 of McClure with effects proportional to the level of clay supplement fed. The protective effect of clay supplement "A" was also observed on the microscopic and radiological appearance of the long bones of miniature pigs fed rations similar to the above although in this species no growth promoting effect was noted. Clay supplement "A" was also active in promoting growth and preventing pathological changes in the long bones of rats fed (a) a low calcium, low protein, low fat, rye flour-containing ration (b)a highly purified, calcium-deficient ration containing casein as the source of dietary protein, and (c) a highly purified, calcium-deficient ration containing methionine-supplemented soy protein as the source of dietary protein. Findings indicate that the protective effects of clay supplement "A" when fed with the wheat flour and rye flour-containing rations were due in large part to some factor or factors other than its calcium content.[6] This is indicated by the fact that calcium when fed in the form of $CaCO_3$ at the same level of calcium as was provided by clay supplement "A" at a 4% level in the diet had no growth promoting activity and was far less active than the 4% clay supplement in preventing the pathological changes which occurred in the long bones of rats fed the unsupplemented wheat flour and rye flour-containing rations. The beneficial effects of clay supplement "A" when fed

with the purified, casein-containing and soy protein-containing rations, however, were due in large part to its calcium content. This is indicated by the fact that calcium when fed in the form of $CaCO_3$ at the same level of calcium as was provided by clay supplement "A" at a 4% level in the diet was only slightly less active than the 4% clay supplement in promoting increment in body weight although it was substantially less active than the latter in promoting bone development in rats fed the purified casein-containing and soy-protein-containing rations. The latter findings suggest either that the calcium in clay supplement "A" is absorbed more efficiently than the calcium in $CaCO_3$ or that clay supplement "A" contains some factor or factors other than calcium which promotes improved calcium utilization and/or bone formation. Further studies are indicated to determine the factor or factors in clay supplement "A" responsible for its protective effects and the modus operandi involved. Although clay sample "A" was the most active of the various clay samples tested in promoting a weight increment in immature rats fed the low calcium, low protein, low fat, non-heat-processed,wheat flour-containing ration other clay samples were also active in this regard although some were devoid of growth promoting activity. No correlation was observed between the color of the clay and its effect on increment in body weight.

Present findings indicate that clay supplement "A" was active in preventing rachitic changes and promoting bone development in several species of young growing animals. Further studies are indicated to determine whether this supplement would also be active in prevent osteoporosis in adult animals with normal skeletal development when placed on calcium-deficient and other osteoporosis-inducing diets. Studies are warranted to determine the effects of

clay supplement "A" on calcium excretion and the occurrence and severity of osteoporosis in adult animals whose hind limbs are immobilized in bivalved body casts. Normal osteoblastic activity depends to a large measure upon the stresses of muscular contractions and weight-bearing compression forces (14-18). The loss of these stimuli results in insufficient formation of bone matrix, inadequate deposition of calcium salts and increased porosity of bone. The softened bone loses its strength and resiliency and is subject to fractures. It would be of interest to determine whether clay supplement "A" which had significant activity in promoting osteoblastic activity, formation of bone matrix and deposition of calcium salts in young animals fed calcium-deficient rations would also be active under conditions where the stresses of muscular contractions and weight-bearing compression forces are removed as would occur under plaster immobilization. Such studies might also be pertinent to conditions of prolonged exposure to a sub-gravity or weightless state where an increased calcium excretion is likely to occur. Since a high incidence of renal tract calculus formation might also be anticipated under the latter conditions, it would be of interest to determine whether clay supplement "A" would be active in preventing or minimizing the occurrence of renal calculi under experimental conditions where the latter occur.

D. Summary:

Studies were conducted on the effects of clay supplementation on the weight increment and microscopic appearnce of the long bones of immature male rats, hamsters, mice and miniature pigs fed a low calcium, low protein, low fat, non-heat-processed, wheat flour-containing ration similar to diet 256 of McClure. Findings indicate that the clay supplementation at levels of 1%, 2% and 4% in the

above diet caused a highly significant increment in body weight and prevented the occurrence of pathological changes which were observed in the long bones of immature rats, hamsters and mice fed the unsupplemented diet. Effects were proportional to the level of clay supplement fed. The protective effect of the clay supplement was also observed on the microscopic and radiological appearance of the long bones of miniature pigs although in this species no growth-promoting effect was noted. Clay supplementation at the above levels of feeding was also active in promoting growth and preventing pathological changes in the long bones of rats fed (a) a low calcium, low protein, low fat, rye flour-containing ration (b) a highly purified calcium-deficient ration containing casein as the source of dietary protein, and (c) a highly purified, calcium-deficient ration containing methionine-supplemented soy protein as the source of dietary protein. Findings indicate that the protective effects of the clay supplement when fed with the wheat flour and rye flour-containing rations were due in large part to some factor or factors other than its calcium content. The beneficial effects of clay supplementation when fed with the purified casein-containing and soy protein-containing rations, however, were due primarily to its serving as a source of dietary calcium although evidence was obtained that the clay supplement contained some factor or factors other than calcium which promoted improved calcium utilization and/or bone formation. A number of clays were tested and found to differ significantly in growth-promoting activity.

REFERENCES

1. Cooper, M.: Pica. Charles C. Thomas, Publisher, Springfield, Ill. 1957.

2. Christopherson, J.B.: Earth eating in the Egyptian Sudan. J. Trop. Med., xiii:3, 1910.

3. Mathieu, J.: Geophagy and intestinal parasitism in Morocco. Arch. de med. d. enf., 30:591, 1927.

4. Blair, M.D.: Native salts in Nigeria, C.R.(D),7,1926.

5. Lasch, R.: Ueber geophagie. Mitt. Anthropol. Gesellsch., Wein 28:214, 1898.

6. French, M.H.: Geophagia in animals. E. African M.J., XXII: 103, 1945.

7. Foster, J.W.: Pica. Kenya and E. African M.J., 68, 1927.

8. Dickens, D., and Ford, R.N.: Geophagy (diet eating) among Mississippi school children. Am. Soc. Rev., VII: 1,59,1942.

9. DeCastro, J.: The Geography of Hunger, Little, Brown & Co., Boston, 1952. p. 87.

10. Sydenstricker, V.: Personal communication, cited by Cooper (1), p. 86.

11. Cooper, M. (1), p. 87.

12. Ershoff, B.H. and Bajwa, G.S.: Unpublished findings.

13. McClure, F.J.: Wheat cereal diets, rat caries, lysine and minerals. J. Nutrition, 65:619, 1958.

14. Geiser, M. and Trueta, J.: Muscle action, bone rarefaction and bone formation: an experimental study. J. Bone and Joint Surg., 40-B:282,1958.

15. Grey, E. G., and Carr, J.L.: An experimental study of the factors responsible for noninfectious bone atrophy. Bull. Johns Hopkins Hosp., 26:381, 1915.

16. Stevenson, F.H.: The osteoporosis of immobilization in recumbency. J. of Bone and Joint Surg. 34-3:256, 1952.

17. Symposium on bone as a tissue. Lankenau Hospital Conference, Oct. 30-31, 1958, Blakiston Co., New York.

18. Urist, M.R.: The etiology of osteoporosis. J.A.M.A., 169: 710, 1959.

19. Dodds, M.L. and Lawe, R.: Mineralization of a cereal diet as it affects cariogenicity. J. Nutrition.84:272, 1964.

Footnotes to the paper.

1. Clay supplement "A" is a pinkish tan clay obtained from a deposit near Brawley, California. It is an impure mixture of clays (or interlayered clay) in which halloysite predominates. Some montmorillonite is also present. It contains no detectable organic matter or quartz sand. A chemical analysis of this material indicated it has the following composition:

Ingredient	% by weight
Moisture	4.38
Silica	50.66
Alumina	20.92
Iron Oxide	1.73
Calcium	3.00
Magnesium	4.30
Titanium	0.65
Sodium	1.13
Potassium	2.05
Phosphate	0.16
Carbonate	3.31
Nitrogen	0.00
Sulfate	0.00
Spectrographic analysis	
Manganese	0.046
Barium	0.095
Strontium	0.016
Lead	0.013
Tin	0.009
Copper	0.088
Nickel	0.005
Vanadium	0.009
Cobalt	0.002
Chromium	0.009
Zirconium	0.018
Boron	0.004
Gallium	0.005

The authors are indebted to Mr. H. K. Hebbard of the Cal-Min Company, Brawley, California, for providing the clay supplement "A" employed in the present investigation.

2. Obtained from Tumblebrook Farm, Inc., Brant Lake, N.Y.

3. The miniature pigs (Black Barrows) were obtained from the Hormel Institute, Austin, Minn. They were approximately 10 weeks of age at the start of the experiment.

4. Obtained from General Biochemicals, Chagrin Falls, Ohio.

5. The calcium-free salt mixture had the following composition:

Ammonium phosphate, Monobasic.	110.24 gm
Copper Sulfate	0.39 gm
Ferric Citrate	22.04 gm
Manganous Sulfate	0.20 gm
Magnesium Sulfate	90.00 gm
Potassium Aluminum Sulfate	0.09 gm
Potassium Chloride	120.00 gm
Potassium Dihydrogen Phosphate	310.00 gm
Potassium Iodide	0.05 gm
Sodium Chloride	105.00 gm
Sodium Fluoride	0.57 gm

6. Preliminary studies indicate that the protective effects of clay supplement "A" when fed with the wheat flour-containing ration were due in part to its sodium content. The addition of Na_2HPO_4 to the basal ration (diet A1) at a level of 1.4 gm. per kg. of diet, an amount of Na_2HPO_4 which contained the same amount of sodium as was present in the 4% clay supplement in a kg. of diet A4, resulted in a significant weight increment over that obtained on the unsupplemented basal ration (diet A1). After 8 weeks of feeding the average weight increment of immature rats fed the Na_2HPO_4-containing diet was 159.0 gm in contrast to an average weight increment of 81.4 gm in rats fed the basal ration (diet A1). This was less, however, than the average weight increment of 189.6 gm of rats fed the ration containing 4% clay supplement "A" (diet A4). The growth-promoting effect of Na_2HPO_4 is in agreement with the recent report of Dodds and Law (19) that diet 256 of McClure (which is similar to diet A1 of the present investigation) is deficient in sodium. Preliminary studies also indicated that rats fed the above Na_2HPO_4 supplement exhibited a significant increase in the amount of hematopoietic tissue and an improved appearance in respect to the modelling and growth of spongiosa bone over that of rats fed the basal ration (diet A1). The Na_2HPO_4 supplement had no effect, however, on the thickness and mineralization of cortical or trabecular bone in contrast to the marked protective effect of 4% clay supplement "A".

LEGEND TO FIGURES

Fig. 1. Tibia of rat fed the basal wheat-containing ration (diet A1), x 116. Note severely malformed, cancellous and underdeveloped cortical bone appearing as a thin and poorly calcified lamina, and marrow containing largely fatty tissue and sparse hematopoietic tissue.

Fig. 2 Tibia of rat fed the basal wheat-containing ration + 4% clay supplement (diet A4), x 116. Note normal appearance showing well developed cortical bone and marrow with densely packed hematopoietic tissue in contrast to Fig. 1.

Fig. 3. Tibia of rat fed the basal wheat-containing ration + 1% clay supplement (diet A2), x 116. Note the cortical bone is significantly more developed and the marrow is composed largely of hematopoietic tissue in contrast to Fig. 1, but less than in Fig. 2.

Fig. 4. Tibial epiphyseal plate and spongiosa bone of rat fed the basal wheat-containing ration (diet A1), x 116. Note abnormal growth pattern of the epiphyseal cartilage columns which are not projecting straight downward and are not undergoing mineralization and ossification. This has resulted in defective modelling of the spongiosa bone which is seen as a network of malformed trabeculae (made of osteoid and persistent cartilage cells), hyperplastic osteoblasts and engorged blood vessels.

Fig. 5. Tibial epiphyseal plate and spongiosa bone of rat fed the basal wheat-containing ration + 4% clay supplement (diet A4), x 144. Note normal appearance and bone growth pattern in contrast to Fig. 4. The spongiosa bone shows normal modelling and the epiphyseal cartilage columns are growing downward and undergoing ossification in a normal manner.

Fig. 6. Tibial epiphyseal plate and spongiosa bone of rat fed the basal wheat-containing ration + 1% clay supplement (diet A2), x 144. Bone growth and architecture is nearly normal in contrast to Fig. 1, but the spongiosa bone is not as well developed as in Fig. 5.

Fig. 7. Femoral epiphyseal bone of rat fed the basal wheat-containing ration (diet A1), x 72. Note poorly developed and widely separated bony trabeculae with the marrow consisting largely of fatty tissue.

Fig. 8. Femoral epiphyseal bone of rat fed the basal wheat-containing ration + 4% clay supplement (diet A4), x 72. Note well developed and numerous bony trabeculae and abundant hematopoietic tissue in the marrow in contrast to Fig. 7.

Fig. 9. Femoral epiphyseal bone of rat fed the basal wheat-containing ration + 1% clay supplement (diet A2), x 72. The trabecular bone is more developed and there is an abundance of hematopoietic tissue in contrast to fig. 7 but less than in Fig. 8.

Fig. 10. Tibia of hamster fed the basal wheat-containing ration (diet A1), x 144. Note underdeveloped cortical bone, sparse hematopoietic tissue in the marrow and thickened periosteum.

Fig. 11. Tibia of hamster fed the basal wheat-containing ration + 4% clay supplement (diet A4), x 144. Note normal appearance with well developed cortical bone, normal periosteum and abundant hematopoietic tissue in contrast to Fig. 10.

Fib. 12. Tibia of hamster fed the basal wheat-containing ration + 2% clay supplement (diet A3), x 144. Note significantly improved cortical bone and hematopoietic tissue in contrast to Fig. 10, but less than in Fig. 11.

Fig. 13. Tibial epiphyseal plate and spongiosa bone of

hamster fed the basal wheat-containing ration (diet A1), x 144. Note loss of normal bone growth due to lack of normal downward modelling, mineralization and ossification of the cartilage columns resulting in obliteration of normal architecture of the spongiosa bone. These lesions are similar to but less marked than those in rats fed the same diet in Fig. 4.

Fig. 14. Tibial epiphyseal plate and spongiosa bone of hamster fed the basal wheat-containing ration + 4% clay supplement (diet A4), x 144. Note normal bone growth and modelling in contrast to Fig. 13.

Fig. 15. Tibial epiphyseal plate and spongiosa bone of hamster fed the basal wheat-cpntaining ration + 2% clay supplement (diet A3), x 144. Note nearly normal bone growth and modelling in contrast to Fig. 13. The bone is less developed, however, than in Fig. 14.

Fig. 16. Femoral epiphyseal bone of hamster fed the basal wheat-containing ration (diet A1), x 72. Note under-developed and deficient trabeculae with marrow consisting largely of fatty tissue.

Fig. 17. Femoral epiphyseal bone of hamster fed the basal wheat-containing ration + 4% clay supplement (diet A4), x 72. Note well developed and normal appearing trabeculae and abundant hematopoietic marrow in contrast to Fig. 16.

Fig. 18. Femoral epiphyseal bone of hamster fed the basal wheat-containing ration + 2% clay supplement (diet A3),x72. The trabeculae and hematopoietic marrow are significantly more developed than those of hamsters fed basal wheat-containing ration (diet A1) in Fig. 16, but less developed than those of hamsters fed the 4% clay supplement (diet A4) in Fig. 17.

Fig. 19. Tibia of mouse fed the basal wheat-containing ration (diet A1), x 144. Note normal appearing cortical bone and marrow with abundant hematopoietic tissue.

Fig. 20. Tibia of mouse fed the basal wheat-containing ration + 4% clay supplement (diet A4j, x 144. The cortical bone is better developed than in Fig. 19.

Fig. 21. Tibial epiphyseal plate and spongiosa bone of mouse fed the basal wheat-containing ration (diet A1), x 144. Note early rachitic changes along the epiphyseal plate but the spongiosa bone is normal in appearance and well developed.

Fig. 22. Tibial epiphyseal plate and spongiosa bone of mouse fed the basal wheat-containing ration + 4% clay supplement (diet A4), x 144. Note normal bone growth and architecture in contrast to Fig. 21.

Fig. 23. Contact positive print of x-ray of miniature pig "A" fed the basal wheat containing ration (diet A1) and miniature pig "B" fed the 2% clay supplement (diet A3). Both legs were x-rayed simultaneously on a single film. Note femur in "A" (top) shows decreased density and enlargement of most of the shaft and distal epiphyseal end. The femur in "B"(bottom) is uniformly denser with well defined cortex and more normally modelled proximal and distal epiphyseal ends.

Fig. 24. Contact positive print of x-ray of tibia, fibula and tarsal joint of miniature pig "A" fed the basal wheat-containing ration (diet A1) and miniature pig "B" fed 2% clay supplement (diet A3). These bones were also exposed simultaneously as in Fig. 23. Note the bones in "A"(top) are less dense and are more malformed than those in "B"(bottom). The tibia in the latter is well developed and normally modelled.

Fig. 25. Tibia of miniature pig fed the basal wheat containing ration (diet A1) x 72. Note underdeveloped, porous and irregularly calcified cortical bone.

Fig. 26. Tibia of miniature pig fed the basal wheat-containing ration + 2% clay supplement (diet A3), x 72. The cortical bone though slightly porous is significantly more developed than in Fig. 25.

Fig. 27; Tibial epiphyseal plate and spongiosa bone of miniature pig fed the basal wheat-containing ration (diet A1), x144. Bone growth pattern is indicative of moderate rachitic changes as shown by defective and deficient mineralization and ossification of the disappearing cartilage columns. Marked osteoblastic and osteoclastic activity is also noticeable.

Fig. 28. Tibial epiphyseal plate and spongiosa bone of miniature pig fed the basal wheat-containing ration + 2% clay supplement (diet A3), x 144. Note marked improvement in mineralization and ossification of cartilage columns over that in Fig. 27. The spongiosa bone though not fully developed shows near normal modelling and osteoblastic activity.

Fig. 29. Tibial spongiosa bone of miniature pig fed the basal wheat-containing ration (diet A1), x 72. Note severe obliteration of spongiosa bone which shows malformed trabeculae, fibroblastic proliferation and sparcity of hematopoietic tissue.

Fig. 30. Tibial spongiosa bone of miniature pig fed the basal wheat-containing ration + 2% clay supplement (diet A3), x 72. Note relatively normal appearing trabeculae and marrow with abundant hematopoietic tissue in contrast to Fig. 29.

Fig. 31. Tibia of rat fed the basal wheat-containing ration and calcium carbonate supplement (diet A5), x 144. Cortical bone

though slightly cancellous is similar in appearance to that of rats fed the 1% clay supplement (diet A2) in Fig. 3, but the marrow (hematopoietic tissue) is similar to that of rats fed the basal ration (diet A1) in Fig. 1.

Fig. 32. Tibial epiphyseal plate and spongiosa bone of rat fed the basal wheat-containing ration + $CaCO_3$ supplement (diet A5) x 144. Note improved appearance of the bone compared to that of rats fed the basal ration (diet A1) in Fig. 4, and similarity of appearance to that of rats fed the 1% clay supplement (diet A2) in Fig. 6.

Fig. 33. Femoral epiphyseal bone of rats fed the basal wheat-containing ration + $CaCO_3$ supplement (diet A5), x 72. The trabecular bone is similar in appearance to that of rats fed the 1% clay supplement (diet A2) in Fig. 6, but the hematopoietic tissue is comparable to that of rats fed the basal ration (diet A1) in Fig. 7.

Fig. 34. Tibia of rat fed the basal rye-flour containing ration (diet B1), x 144. The cortical bone though cancellous and malformed is more developed and the marrow contains more hematopoietic tissue than rats fed the basal wheat-containing ration (diet A1) in Fig. 1.

Fig. 35. Tibia of rat fed the basal rye-flour containing ration + 4% clay supplement (diet B4), x 144. Note well developed and normal appearing cortical bone and hematopoietic marrow in contrast to rats fed the basal rye-flour containing ration (diet B1) in Fig. 34.

Fig. 36. Tibia of rat fed the basal rye flour-containing ration + 2% clay supplement (diet B3) x 144. Note markedly improved cortical bone and marrow with abundant hematopoietic

tissue in contrast to that of rats fed the basal ration (diet B1) in Fig. 34, but less than that of rats fed the 4% clay supplement (diet B4) in Fig. 35.

Fig. 37. Tibia of rat fed the basal rye flour-containing ration + $CaCO_3$ supplement (diet B5), x 144. Cortical bone and hematopoietic marrow are well developed in contrast to rats fed the basal ration (diet B1) in Fig. 34 and is similar to rats fed the 2% clay supplement (diet B3) in Fig. 36.

Fig. 38. Tibial epiphyseal plate and spongiosa bone of rat fed the basal rye flour-containing ration (diet B1), x 144. Note typical rachitic appearance showing poor mineralization and ossification of the cartilage columns and defective modelling of the spongiosa bone.

Fig. 39. Tibial epiphyseal plate and spongiosa bone of rat fed the basal rye flour-containing ration + 4% clay supplement (diet B4), x 144. Note normal bone growth pattern and normal modelling of the spongiosa bone in contrast to rats fed the basal ration (diet B1) in Fig. 38.

Fig. 40. Tibial epiphyseal plate and spongiosa bone of rat fed the basal rye flour-containing ration + 2% clay supplement (diet B3), x 144. Note marked improvement in mineralization and ossification of the cartilage columns and normal pattern of the spongiosa bone in contrast to rats fed the basal ration (diet B1) in Fig. 38 but less than that of rats fed the 4% clay supplement (diet B4) in Fig. 39.

Fig. 41. Tibial epiphyseal plate and spongiosa bone of rat fed the basal rye-flour containing ration + $CaCO_3$ supplement (diet B5), x 144. The disappearing cartilage columns exhibit moderate mineralization and ossification, and the spongiosa is

nearly normal in architecture in contrast to rats fed the basal ration (diet B1) in Fig. 38. The appearance is comparable to that of rats fed the 2% clay supplement (diet B3) in Fig. 40.

Fig. 42. Femoral epiphyseal bone of rat fed the basal rye flour-containing ration (diet B1), x 72. The trabecular bone though not normal is significantly better developed and mineralized and the marrow contains more hematopoietic tissue than that of rats fed the basal wheat-containing ration (diet A1) in Fig. 7.

Fig. 43. Femoral epiphyseal bone of rat fed the basal rye flour-containing ration + 4% clay supplement (diet B4), x 72. Note well developed and normal appearing trabecular bone, and marrow with abundant hematopoietic tissue in contrast to rats fed the basal ration (diet B1) in Fig. 42.

Fig. 44. Femoral epiphyseal plate of rat fed the basal rye flour-containing ration + 2% clay supplement (diet B3), x 72. Note well developed trabeculae and hematopoietic marrow in contrast to rats fed the basal ration (diet B1) in Fig. 42, but less than that of rats fed the 4% clay supplement (diet B4) in Fig. 43.

Fig. 45. Femoral epiphyseal plate of rat fed the basal rye flour-containing ration + $CaCO_3$ supplement (diet B5), x 72. The trabecular bone is more developed and mineralized than that of rats fed the basal ration (diet B1) in Fig. 42, but the hematopoietic marrow is comparable in both groups. The appearance is similar to that of rats fed the 2% clay supplement (diet B3) in Fig. 44.

Fig. 46. Tibia of rat fed the basal, purified, calcium-deficient ration (diet C1), x 116. Note severe rachitic changes. The cortical bone is severely degenerated and cancellous,

consisting of a thin lamina mainly of osteoid. These lesions are more severe than those of rats fed the basal wheat-containing ration (diet A1) in Fig. 1 and the basal rye flour-containing ration (diet B1) in Fig. 34. However, the marrow is more abundant in hematopoietic tissue than in the above groups.

Fig. 47. Tibia of rat fed the basal, purified calcium-deficient ration + 4% clay supplement (diet C4), x 116. Note well developed and normal appearance of the cortical bone and hematopoietic marrow in contrast to rats fed the basal ration (diet C1) in Fig. 46.

Fig. 48. Tibia of rat fed the basal, purified, calcium-deficient ration + 2% clay supplement (diet C3), x 116. The cortical bone though malformed and deficient is better developed than that of rats fed the basal ration (diet C1) in Fig. 46.

Fig. 49. Tibia of rat fed the basal, purified, calcium-deficient ration + $CaCO_3$ supplement (diet C5), x 116. Note better developed cortical bone than that of rats fed the basal ration (diet C1) in Fig. 46. The appearance is intermediate between that of rats fed the 2% clay supplement (diet C3) in Fig. 48, and that of rats fed the 4% clay supplement (diet C4) in Fig. 47.

Fig. 50. Tibial epiphyseal plate and spongiosa bone of rat fed the basal, purified, calcium-deficient ration (diet C1),x116. Note extensive rachitic changes as evidenced by absence of mineralization and ossification of cartilage columns, resulting in loss of normal architecture of the spongiosa bone, which is transformed into a network of osteoid and hyperplastic osteoblasts. These lesions are more severe than those of rats fed the basal wheat-containing ration (diet A1) in Fig. 4, and rats fed

the basal rye flour-containing ration (diet B1) in Fig. 36.

Fig. 51. Tibial epiphyseal plate and spongiosa bone of rat fed the basal, purified, calcium deficient ration + 4% clay supplement (diet C4), x 116. Note normal appearance in contrast to that of rats fed the basal ration (diet C1) in Fig. 50.

Fig. 52. Tibial epiphyseal plate and spongiosa bone of rat fed the basal, purified, calcium-deficient ration + 2% clay supplement (diet C3), x 144. Note marked improvement in bone growth, mineralization, ossification and normal modelling in contrast to rats fed the basal ration (diet C1) in Fig. 50, but less than that of rats fed the 4% supplement (diet C4) in Fig. 51.

Fig. 53. Tibial epiphyseal plate and spongiosa bone of rat fed the basal, purified, calcium-deficient ration + $CaCO_3$ supplement (diet C5), x 144. Note moderate mineralization and normal modelling of the spongiosa bone in contrast to rats fed the basal ration (diet C1) in Fig. 50, but less developed bone than that of rats fed the 4% clay supplement (diet C4) in Fig. 51.

Fig. 54. Tibia of rat fed the basal, purified, calcium-deficient ration (diet D1), x 144. Note severe rachitic changes. The cortical bone is poorly developed, cancellous and consists of a thin bony lamina. The bone is more mineralized and its marrow contains more hematopoietic tissue than rats fed the basal, purified, calcium-deficient ration (diet C1) in Fig. 46.

Fig. 55. Tibia of rat fed the basal, purified calcium-deficient ration + 4% clay supplement (diet D4), x 116. Note well developed and normal appearance of cortical bone and hematopoietic marrow in contrast to rats fed the basal ration (diet D1) in Fig. 54.

Fig. 56. Tibia of rat fed the basal, purified, calcium-

deficient ration + $CaCO_3$ supplement (diet D5), x 116. The cortical bone though slightly cancellous is significantly better developed than that of rats fed the basal ration (diet D1) in Fig.54 and is intermediate in appearance between rats fed the 2% and 4% clay supplements (diet D3 and D4, respectively).

Fig. 57. Tibial epiphyseal plate and spongiosa bone of rat fed the basal, purified calcium-deficient ration (diet D1), x 116 Note severe rachitic changes. The spongiosa bone is similar in appearance but more mineralized than that of rats fed the basal ration (diet C1) in Fig. 50.

Fig. 58. Tibial epiphyseal plate and spongiosa bone of rat fed the basal, purified, calcium-deficient ration + 4% clay supplement (diet D4), x 116. Note normal bone growth and modelling in contrast to rats fed the basal ration (diet D1) in Fig. 57.

Fig. 59. Tibial epiphyseal plate and spongiosa bone of rat fed the basal, purified calcium-deficient ration + $CaCO_3$ supplement (diet D5), x 116. Note marked improvement in bone growth and modelling and spongiosa bone in contrast to rats fed the basal ration (diet D1) in Fig. 57, but less developed appearance than that of rats fed the 4% clay supplement (diet D4) in Fig. 58.

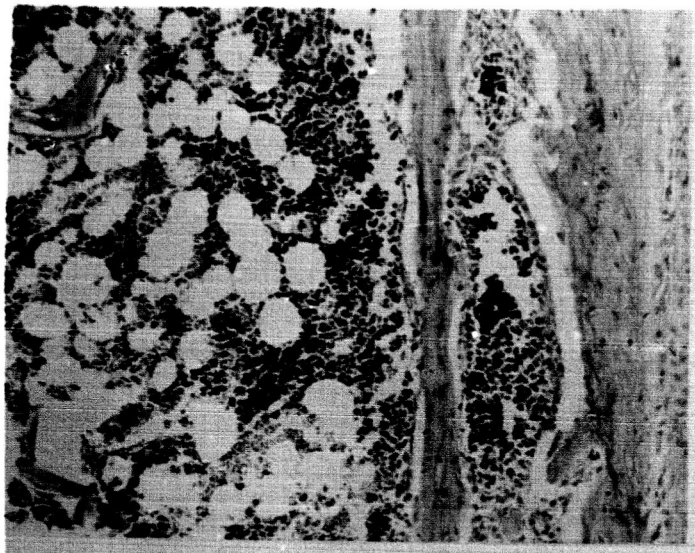

Fig.1

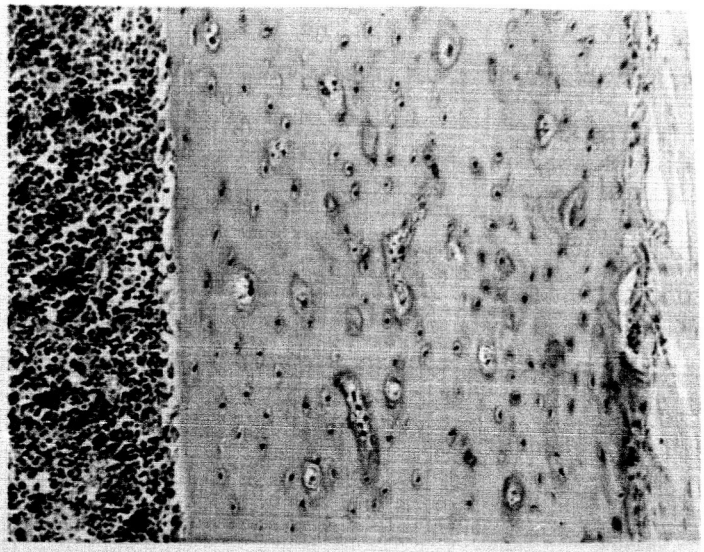

Fig.2

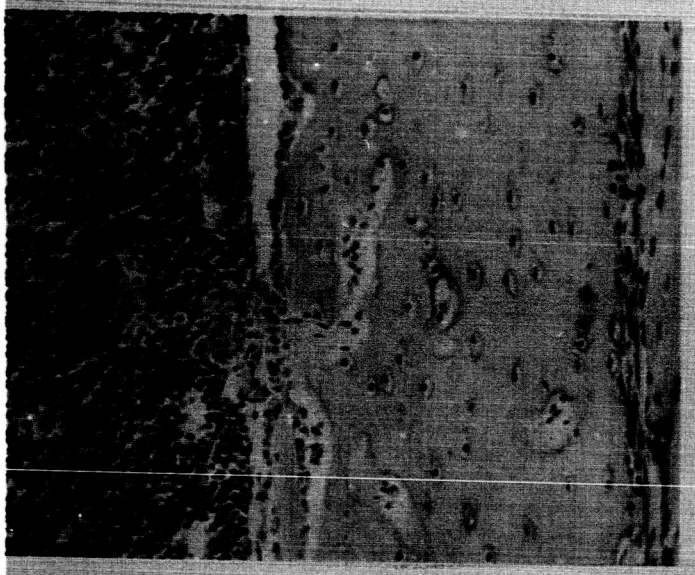

Fig.3

Fig.4

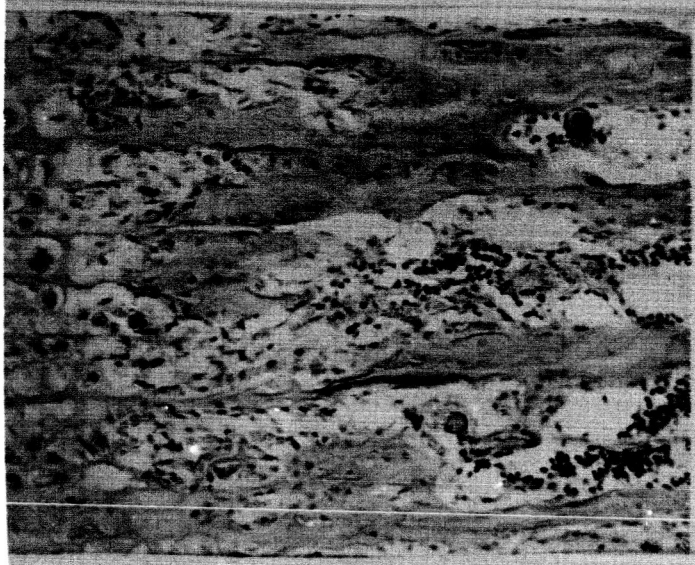

Fig.5

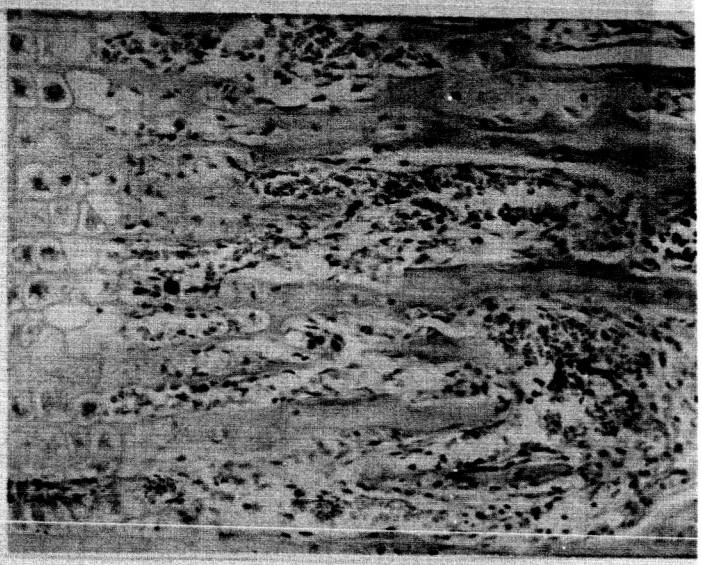

Fig.6

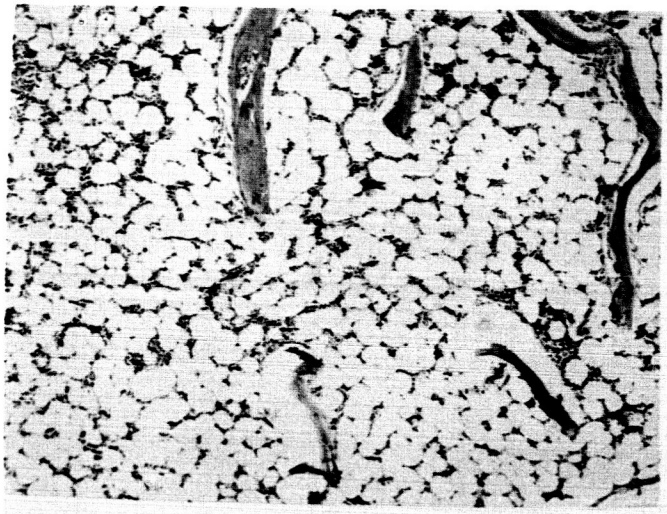

Fig.7

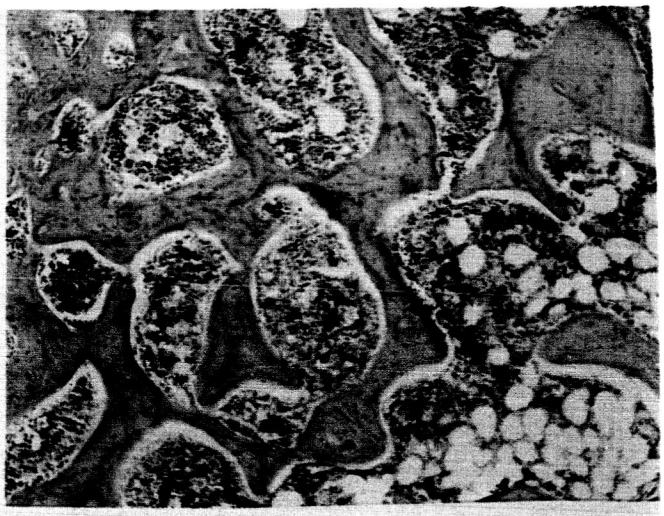

Fig.8

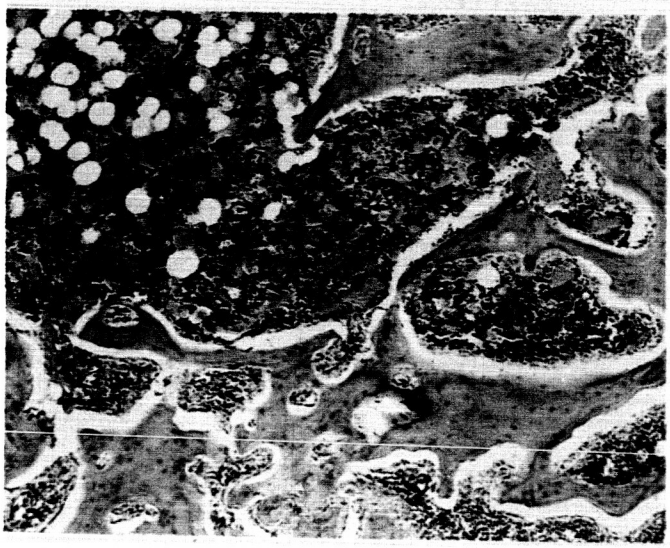

Fig.9

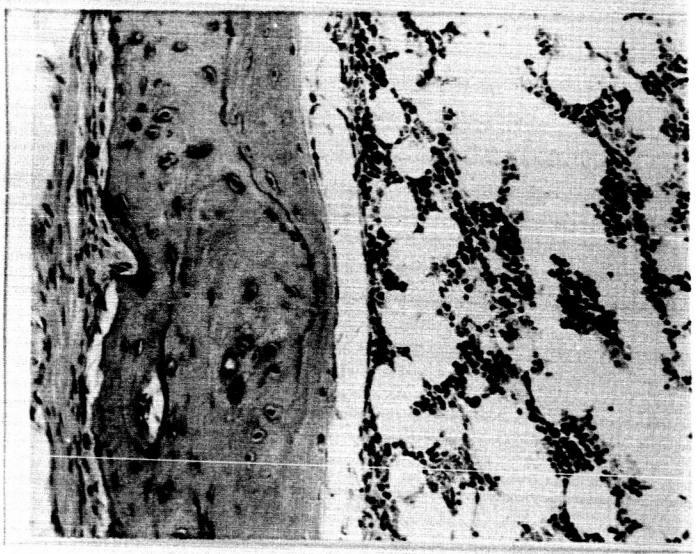

Fig.10

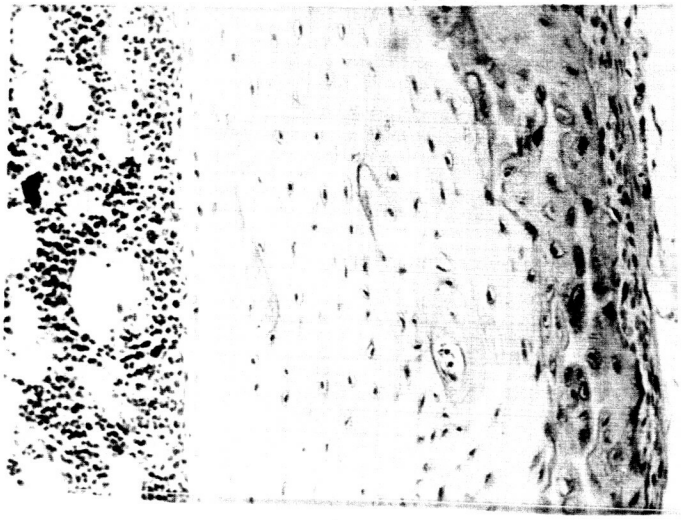

Fig.11

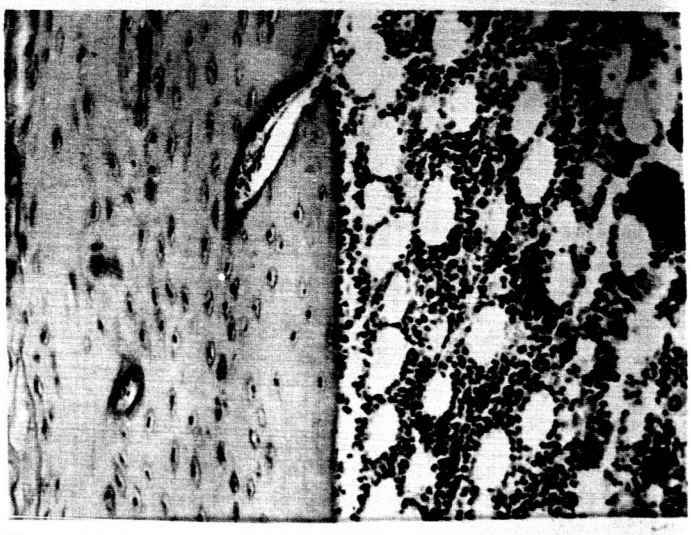

Fig.12

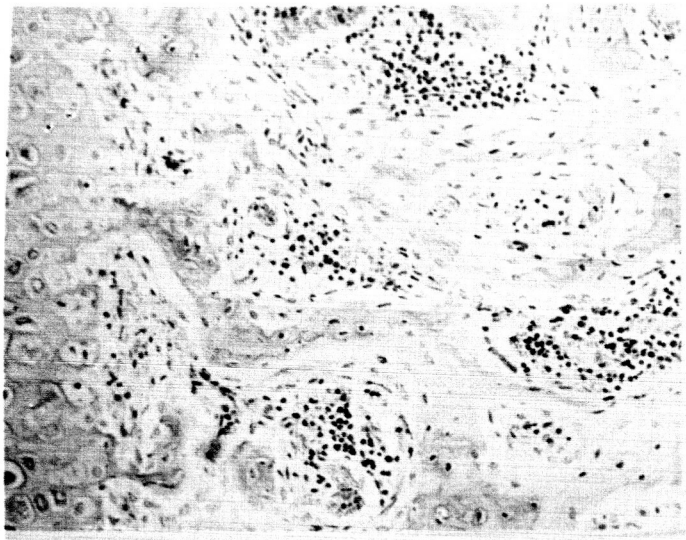

Fig.13

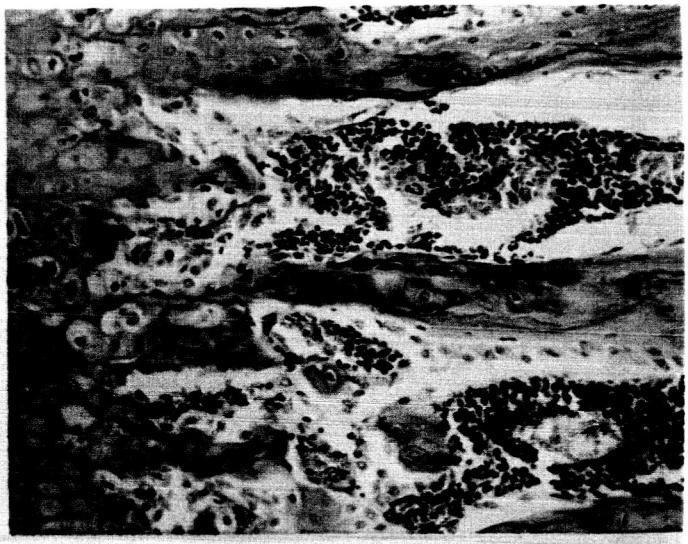

Fig.14



Fig.15

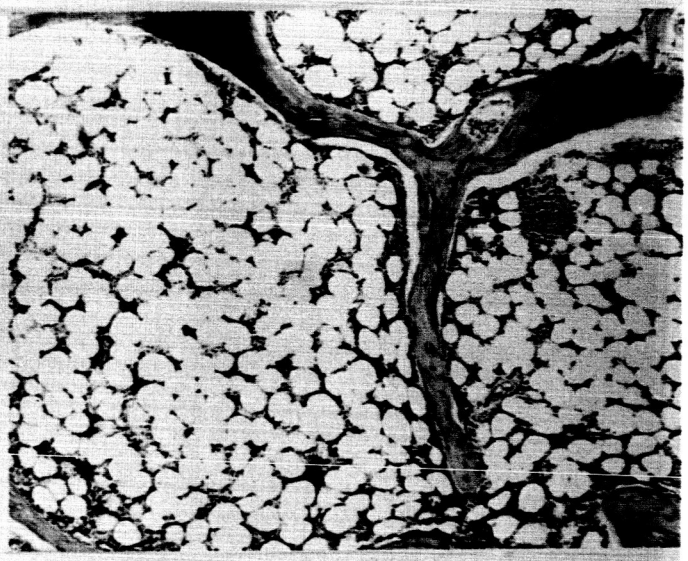

Fig.16

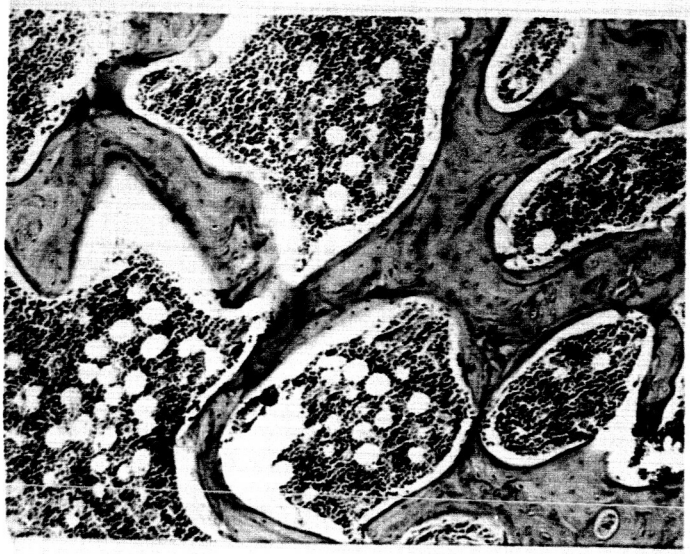

Fig.17

Fig.18

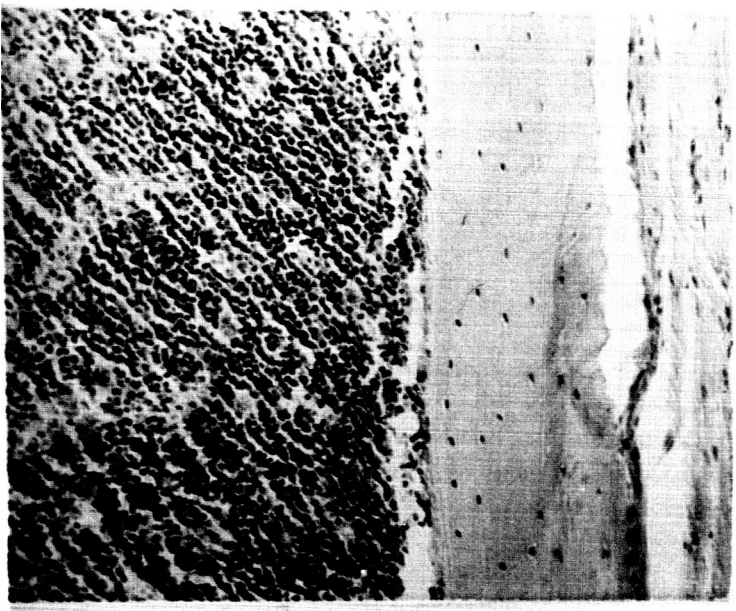

Fig. 19

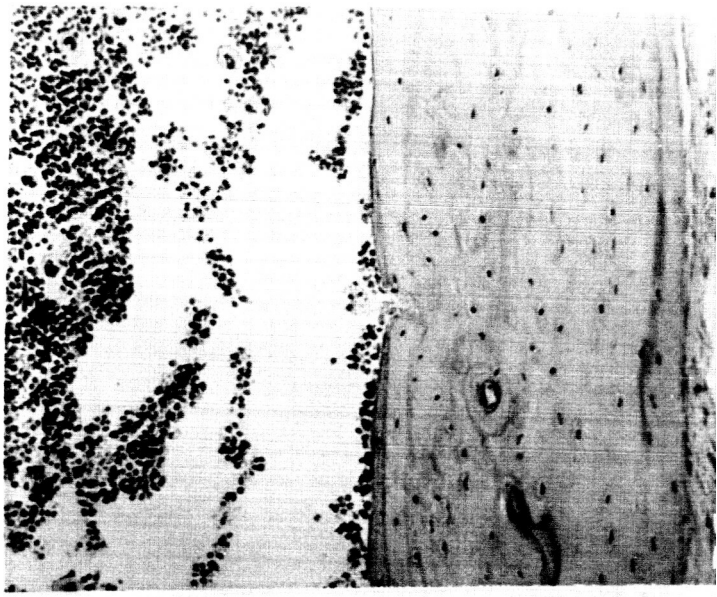

Fig.20

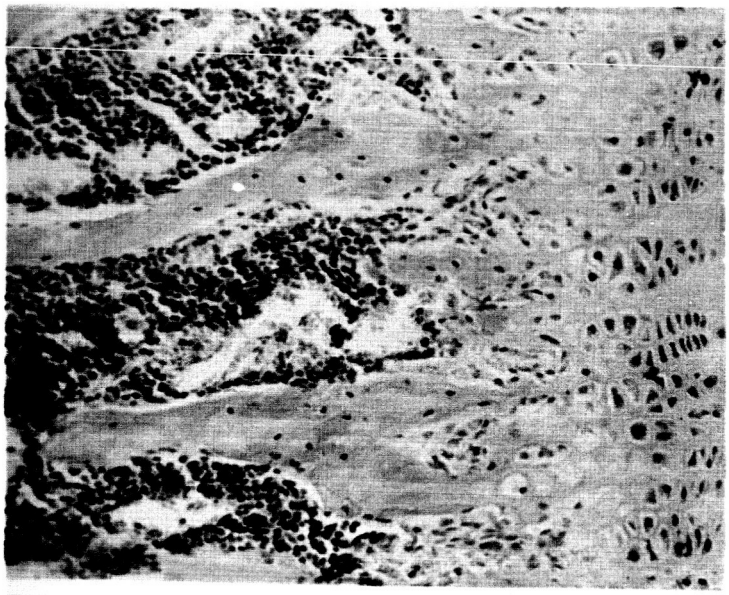

Fig.21

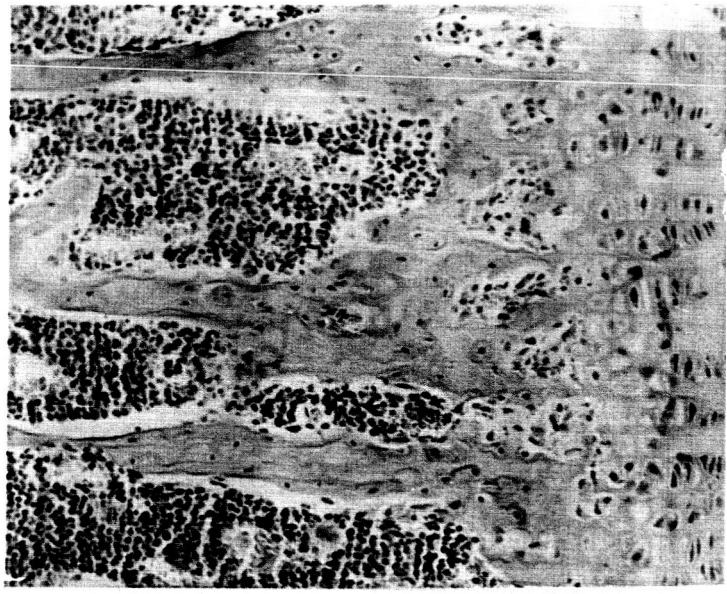

Fig.22

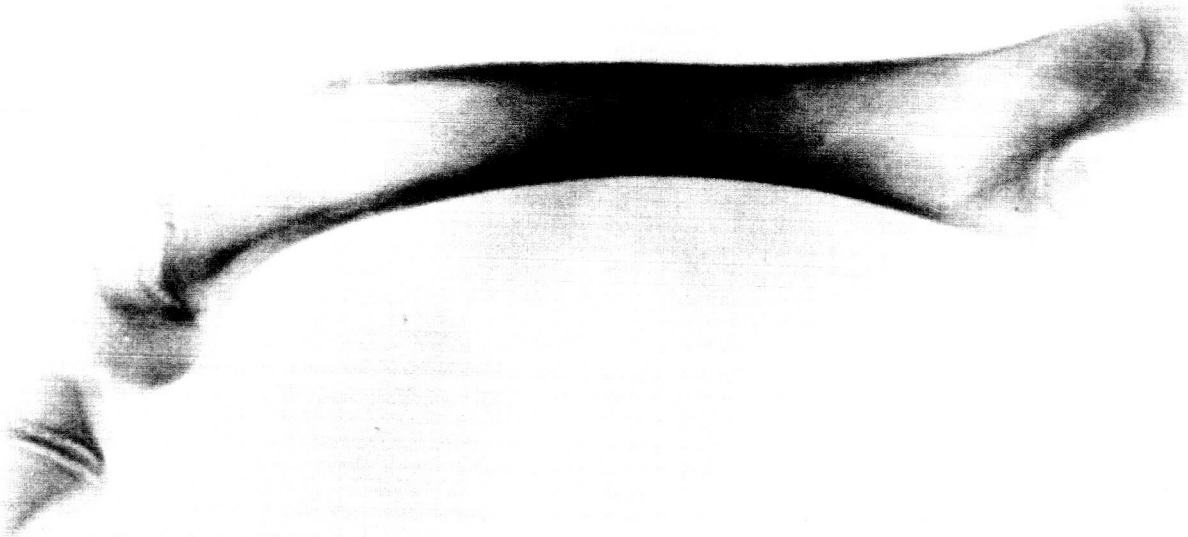

Fig 2[illegible]--a[illegible]

Fig.25

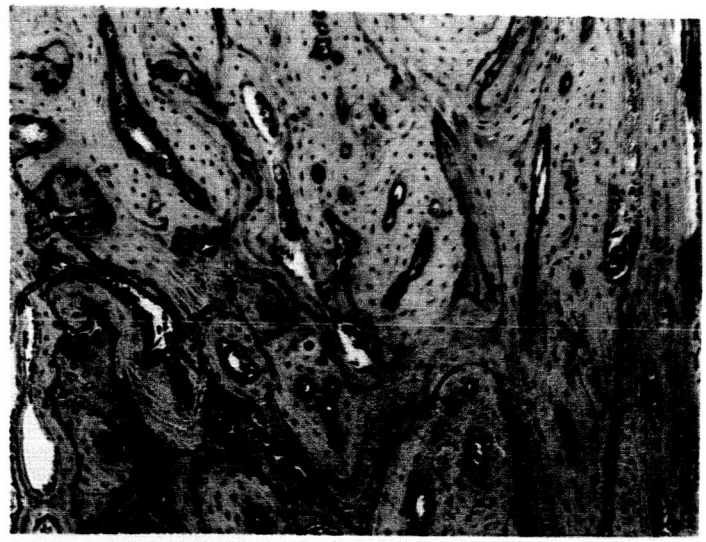

Fig.26

Fig.27

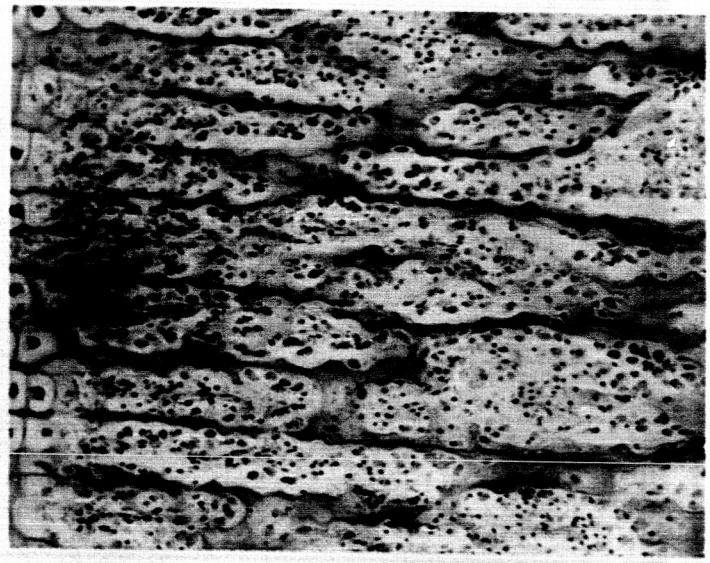

Fig.28

Fig.29

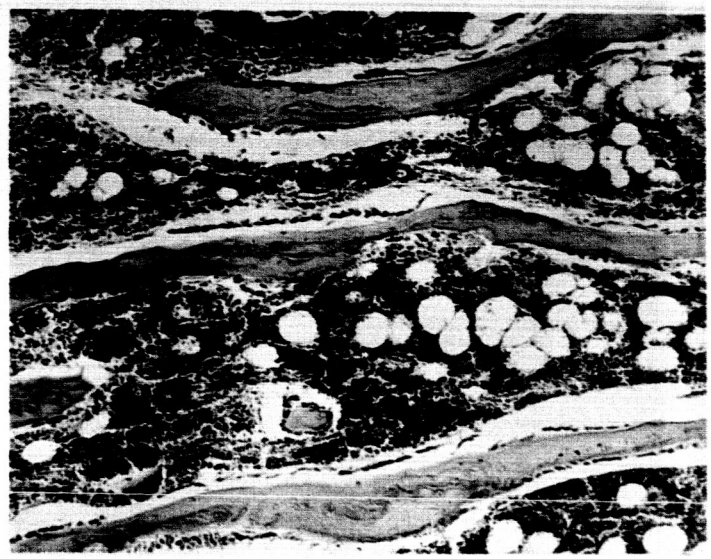

Fig.30

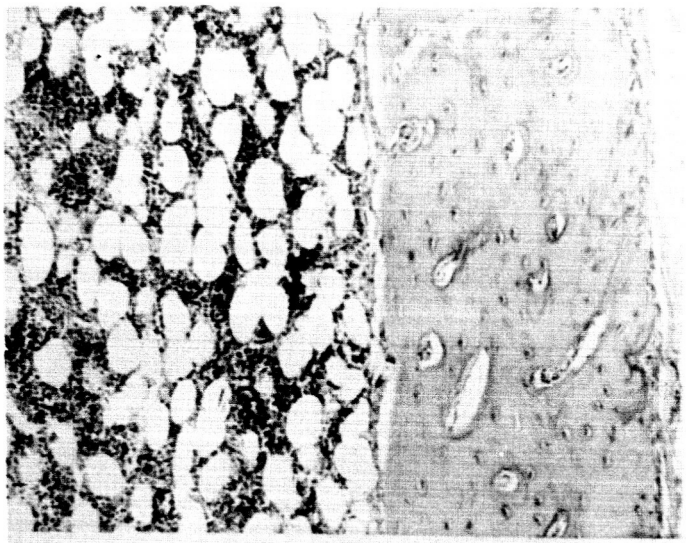

Fig.31

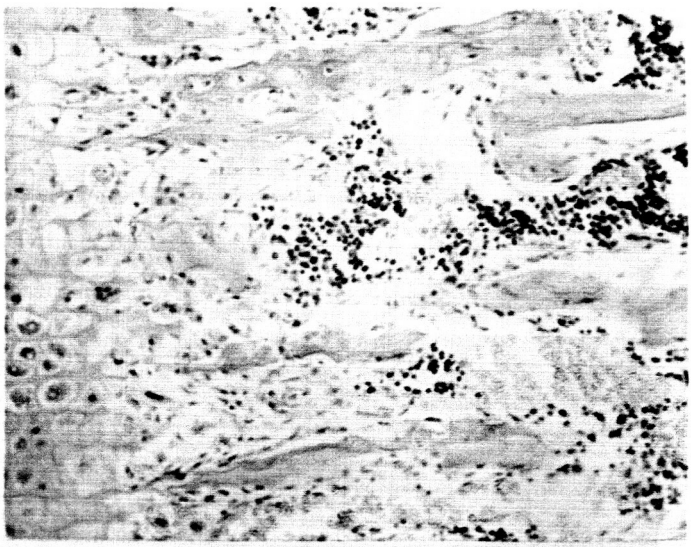

Fig.32

Fig.33

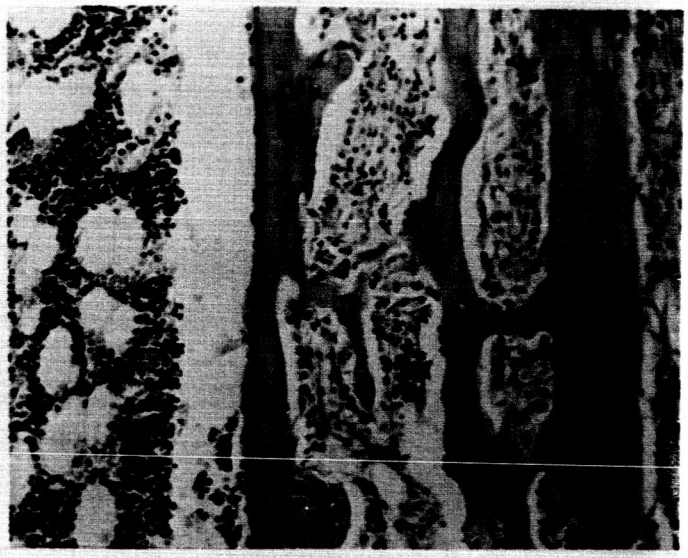

Fig.34

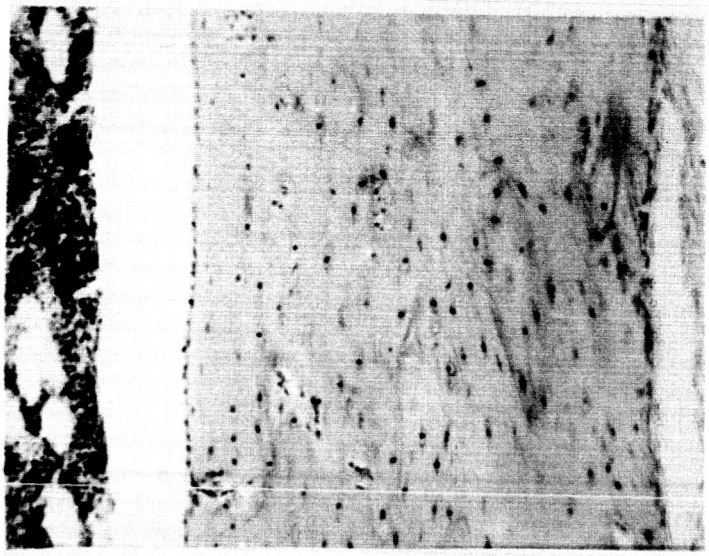

Fig.35

Fig.36

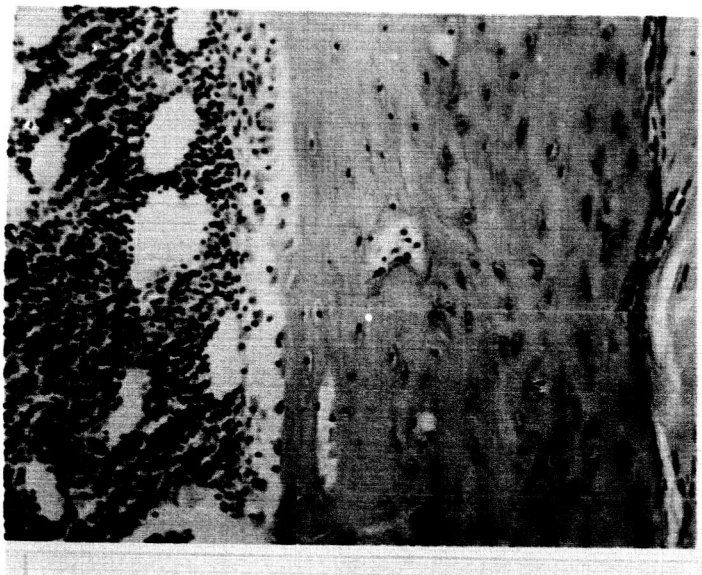

Fig.37

Fig.38

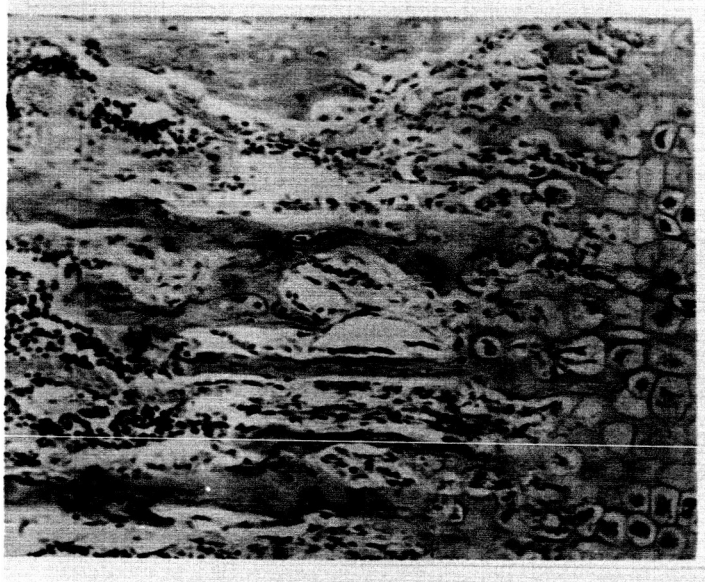

Fig.39

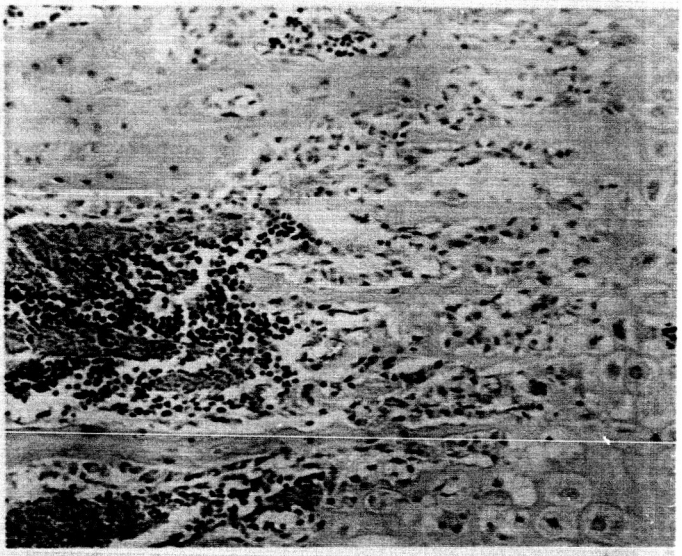

Fig.40

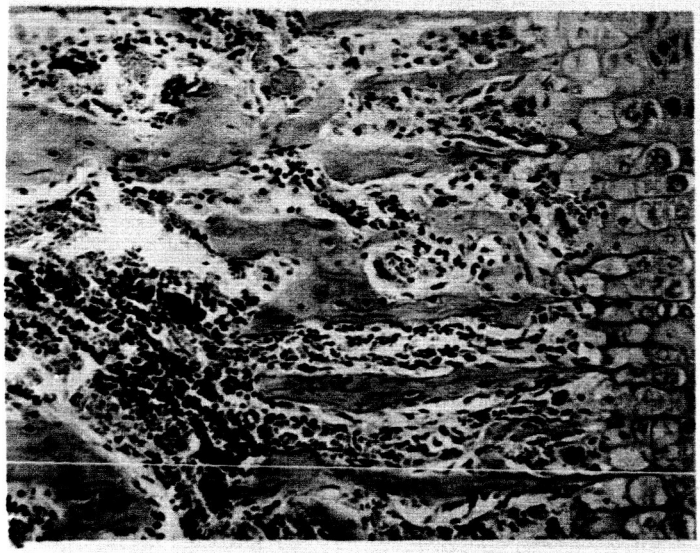

Fig.41

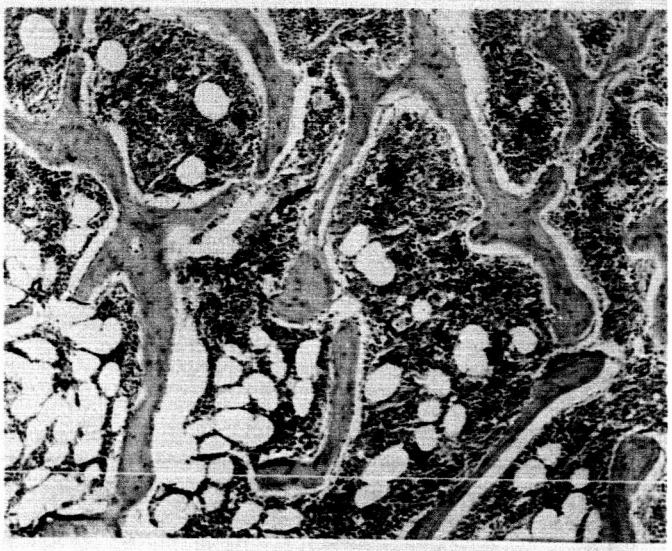

Fig.42

Fig.43

Fig.44

Fig.45

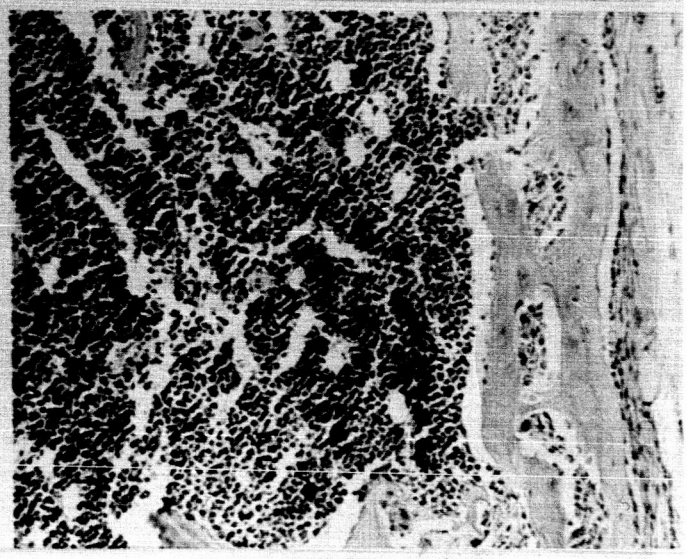

Fig.46

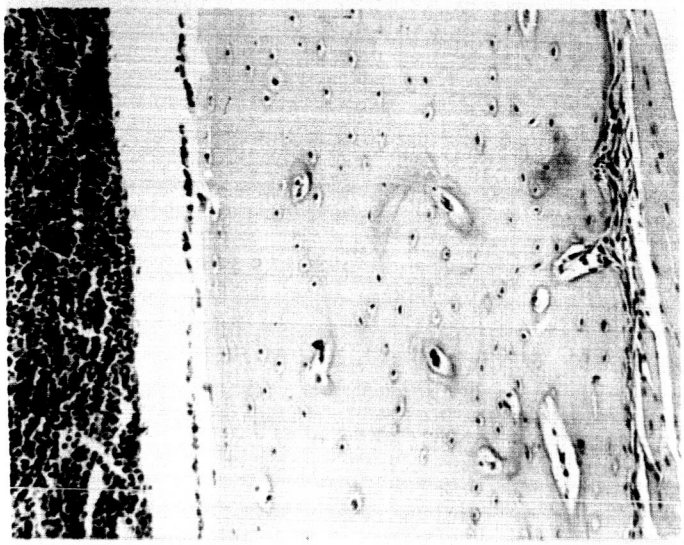

Fig.47

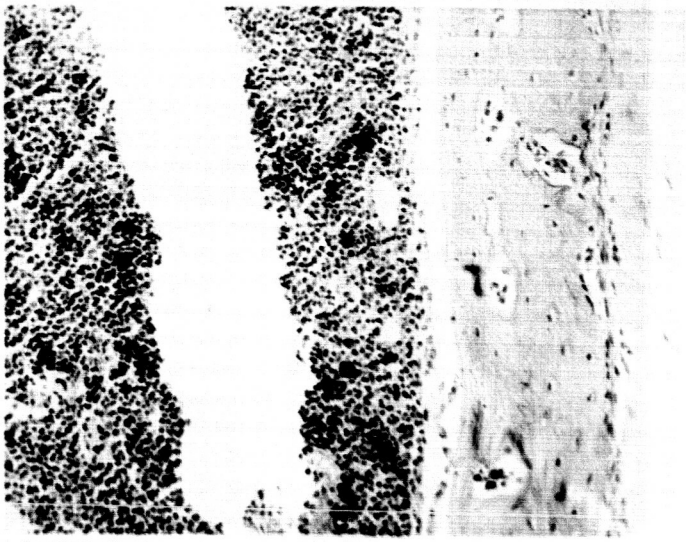

Fig.48

Fig.49

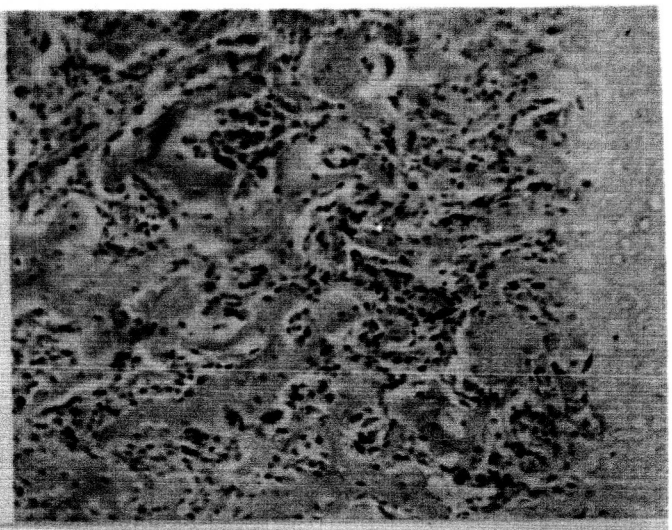

Fig.50

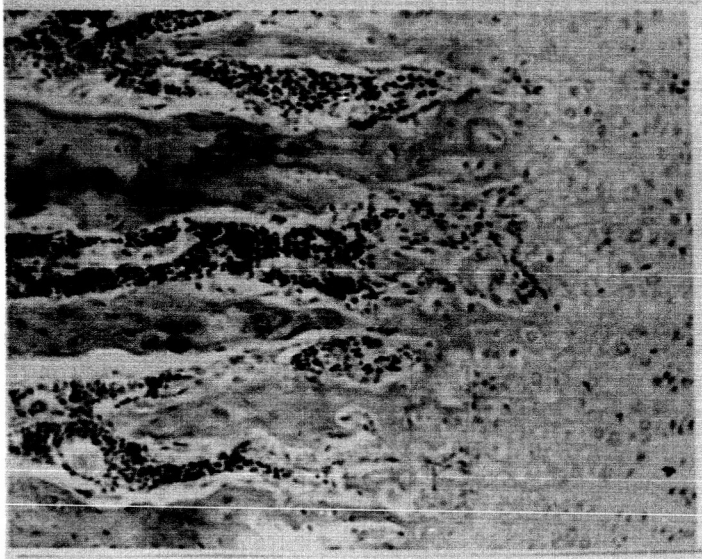

Fig.51



Fig.52

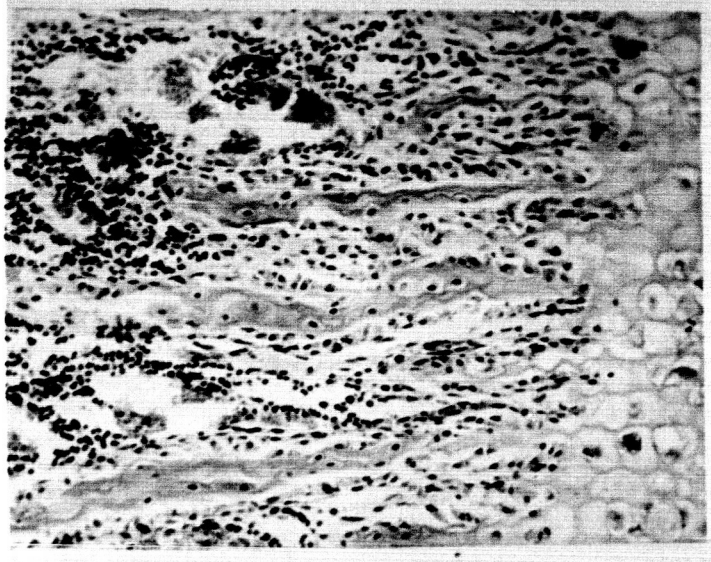

Fig.53

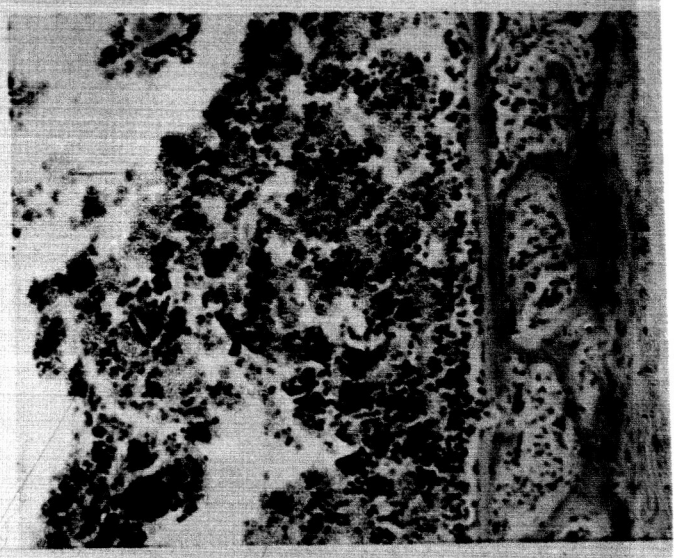

Fig.54

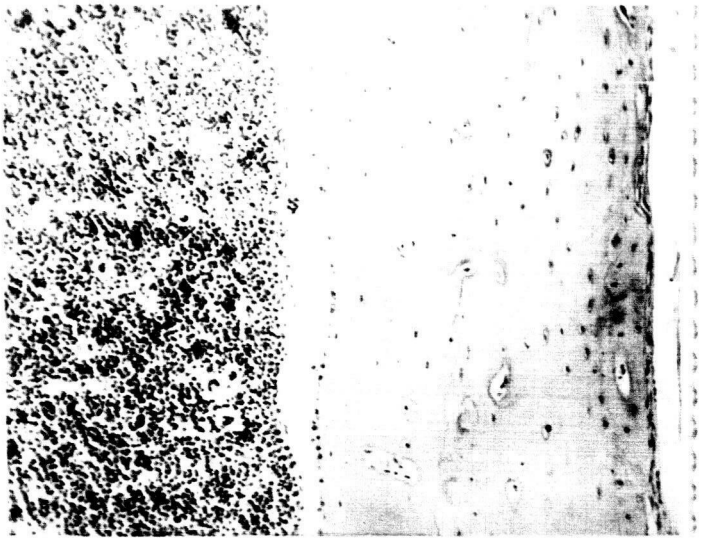

Fig.55

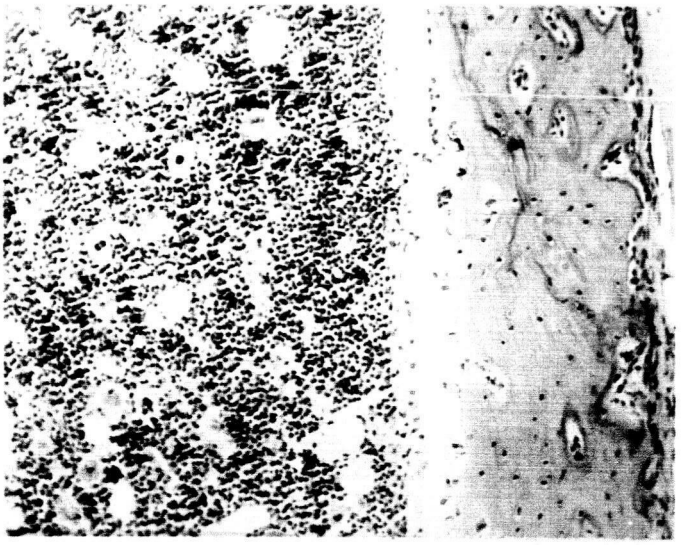

Fig.56

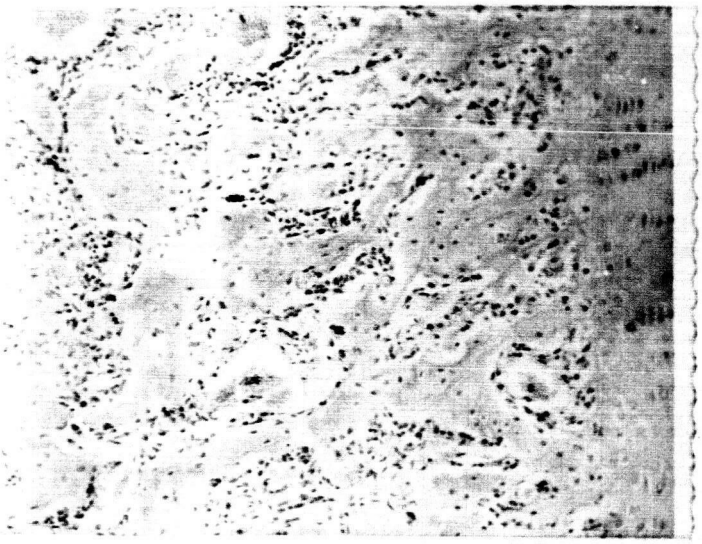

Fig.57

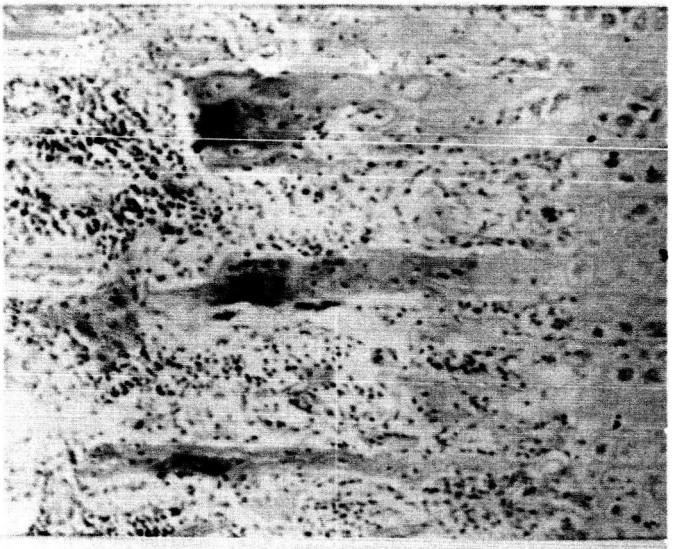

Fig.58

Fig. 59--Page 60