ARL-TR-66-15

HISTOPATHOLOGY OF THE CHIMPANZEE EAR

E. L. House
M. S. Jacobs
B. Pansky
et al.

GPO PRICE $ _____

CFSTI PRICE(S) $ _____

Hard copy (HC) 4.00

Microfiche (MF) .75

ff 653 July 65

June 1966

NASA

N67 13673
(ACCESSION NUMBER)
107
(PAGES)
CR 80719
(NASA CR OR TMX OR AD NUMBER)
(THRU)
1
(CODE)
04
(CATEGORY)
FACILITY FORM 602

This document is subject to special export controls and each transmittal to foreign governments or foreign nations may be made only with prior approval of the 6571st Aeromedical Research Laboratory, Holloman AFB, New Mexico.

6571st Aeromedical Research Laboratory
Aerospace Medical Division
Air Force Systems Command
Holloman Air Force Base, New Mexico

The animals used in this study were handled in accordance with the "Principles of Laboratory Animal Care" established by the National Society for Medical Research.

Certain of the animals used for this research were provided by the National Aeronautics and Space Administration under Order R-25.

This report is made available for study with the understanding that proprietary interests in and relating thereto will not be impaired. In case of apparent conflict or any other questions between the Government's rights and those of others, notify the Judge Advocate, Air Force Systems Command, Andrews Air Force Base, Washington, D.C. 20331.

This report may be reproduced to satisfy needs of U.S. Government agencies. No other reproduction is authorized except with permission of the 6571st Aeromedical Research Laboratory, Holloman AFB, NMex.

Do not return this copy. Retain or destroy.

HISTOPATHOLOGY OF THE CHIMPANZEE EAR

E.L. House
M.S. Jacobs
B. Pansky
et al.

This document is subject to special export controls and each transmittal to foreign governments or foreign nations may be made only with prior approval of the 6571st Aeromedical Research Laboratory, Holloman AFB, New Mexico.

FOREWORD

This report was prepared by the New York Medical College under Contract AF 29(600)-4563. The work on which the report is based was accomplished from 1 March 1964 to 31 December 1965 under Project 6892 and monitored by the Veterinary Division of the 6571st Aeromedical Research Laboratory.

The authors wish to acknowledge the invaluable assistance of James R. Prine, Major, USAF, VC who served as the Air Force Technical Monitor as well as Robert H. Edwards, Major, USAF, MC and William S. Strutton, Captain, USAF, MC who supervised the experiments on the Daisy Decelerator and performed the necropsies. Appreciation is also extended to Bernard M. Wagner, M.D., Chairman of the Department of Pathology, New York Medical College, for his advice and suggestions.

***

This technical report has been reviewed and approved for publication.

C.H. Kratochvil

C.H. KRATOCHVIL, Lt Colonel, USAF, MC
Commander

ABSTRACT

Four female and two male chimpanzees were secured in various positions on a Daisy Decelerator and subjected to forces ranging from 54 to 180 G. It was found that forces in excess of 54 G may rupture the tympanic membranes and cause subepithelial hemorrhages in the middle ear. The majority of cases showed proteinaceous material, with or without cells in the petrous air spaces. When exposed to forces above 119 G, there was engorgement and often rupture of the pericarotid venous plexus. When supine, distortion of both superior and posterior semicircular canals was found. With forces in excess of 54 G, the cupulae of the cristae ampullaris were either elevated or destroyed. The hair processes were also often broken off. The otolithic membranes, especially of the maculae utriculi were also elevated or otherwise distorted and the saccule was often partially collapsed. In several instances, there was an overabundance of a proteinaceous substance in the lumina of the vestibular apparatus and in the cochlear ducts with their associated scalae. In half the cases, the cochlear duct was narrowed by the depression of the vestibular membrane. Although there seems to be considerable individual variation in ability to withstand these forces, neither age, sex nor weight appear to directly influence the results. The possible sources for the materials found both in the air cells and labyrinth are discussed.

TABLE OF CONTENTS

		Page
I.	INTRODUCTION	1
II.	MATERIALS AND METHODS	
	A. GENERAL	2
	B. SPECIFIC TREATMENT	3
	C. HISTOLOGICAL METHODS	4
III.	OBSERVATIONS	
	A. POST-IMPACT EFFECTS	5
	B. RADIOLOGICAL	6
	C. NECROPSY - EXCEPT BRAIN AND EAR	7
	D. POSTMORTEM - SKULL, MENINGES, BRAIN	9
	E. TYMPANIC MEMBRANE AND MIDDLE EAR	10
	F. MICROSCOPIC STUDY	12
IV.	DISCUSSION	19
V.	CONCLUSIONS	23
	REFERENCES	25
	APPENDIX - FIGURES 1-119	29

LIST OF ILLUSTRATIONS

GROSS ASPECTS

Figures

1-6 Brain

7-10 Tympanic membrane

MICROSCOPIC ASPECTS

Figures

11-14 Series A63-031R - Petrous bone and Carotic Canal

15-19 Series A63-031R - Vestibule

20-22 Series A63-031R - Cochlea

23 Series A63-032R - Petrous bone

24-27 Series A63-032R - Vestibule

28-29 Series A63-032R - Saccule

30 Series A63-032R - Secondary tympanic membrane

31-37 Series A63-032L - Vestibule

38-40 Series A63-032L - Utricle

41 Series A63-032L - Cochlea

42 Series A63-032L - Secondary tympanic membrane

43-45 Series A63-033R - Petrous bone

46 Series A63-033R - Vestibule

47-48 Series A63-033R - Cochlea

49 Series A63-033R - Secondary tympanic membrane

50-51 Series A63-033L - Petrous bone

52-61 Series A63-033L - Vestibule

62 Series A63-033L - Saccule

63-64 Series A63-033L - Cochlea

65 Series A63-033L - Secondary tympanic membrane

66-68 Series A63-035R - Vestibule

69 Series A63-035R - Utricle

70-72 Series A63-035R - Cochlea

73 Series A63-035R - Secondary tympanic membrane

74-75 Series A63-035L - Petrous bone

76-77 Series A63-035L - Vestibule

78-80 Series A63-035L - Cochlea

81 Series A63-035L - Secondary tympanic membrane

82-85 Series A63-036R - Vestibule

86-88 Series A63-036R - Utricle

MICROSCOPIC ASPECTS

Figures	
89-92	Series A63-036R - Cochlea
93	Series A63-036R - Secondary tympanic membrane
94-97	Series A63-036L - Petrous bone
98-101	Series A63-036L - Vestibule
102-104	Series A63-036L - Utricle and Saccule
105-107	Series A63-036L - Cochlea
108-109	Series A63-038R - Petrous bone
110	Series A63-038R - Vestibule
111	Series A63-038R - Carotid
112-113	Series A63-038L - Carotid
114-116	Series A63-038L - Vestibule
117	Series A63-038L - Utricle
118-119	Series A63-038L - Cochlea

I. INTRODUCTION

In the 47 years since Guild (18) reported on the deleterious effects of war-induced sounds on the labyrinth of the human inner ear, many accounts have appeared in the literature showing the relationships between sound waves (their frequencies, intensities and duration) and the physiopathology of the cochlea, including both the organ of Corti and its annexa (1; 6-12; 16; 19-22; 26-28; 33; 34; 36-38). These studies encompassed such diverse areas as the exact localization of pathology following sounds of known frequency and intensity; variations in histochemistry not only of the sensory receptor cells but the ganglion cells; electron microscopy and the problem of reversability of the pathological processes. The effects of drugs (3-5), vibration (25) and blows to the head, (35) both on hearing and cochlear structure, have also been noted. The fact that there is a great disproportion of investigations on the auditory portion of the labyrinth should not be surprising when one considers that deafness has always been a common human affliction which might be expected to increase in an ever noisier environment.

After Dickinson and Chadwick (14) had reported symptoms of equilibrium difficulty in individuals exposed to jet engine noise, several papers appeared relating the effects of intense sound on the non-auditory labyrinth (25; 29; 30). The effects of vibration on the auditory apparatus have also been studied (32).

With the advent of space flight, the effect of weightlessness upon the labyrinth assumes greater importance. Because of the necessity for an astronaut to carry out a large number of physical activities requiring coordination of movement, the vestibular portion of the inner ear is of even greater interest than the cochlear. However, as Spoendlin, et al. (38) pointed out in their 1964 report, before one can accurately evaluate the effect of zero gravitational forces, either on structure or function, it would first be essential to determine the consequences of "high-G" forces experienced in ascent to and descent from outer space. A search of the literature has indicated a dearth of such information, especially where a correlation between impaired function and damaged structure are concerned. Three papers, dating back over a period of more than 57 years, have indicated shifts in the otolithic membranes after exposure of experimental animals to rotation or centrifugation (13; 23; 40). Somewhat more recently, equilibrium problems, often lasting for hours, have been reported for human subjects exposed to "high-G" forces in the centrifuge (2; 15; 17).

However, even before the first phases of our own work (24). had gotten underway, or the Spoendlin group (38) had reported its negative findings, several humans had journied into weightlessness. And since then, many other astronauts both here and in the U.S.S.R. have completed round-trips into outer space, apparently without direct deleterious effects. Even so, with the difficulties in obtaining accurate information concerning the Russians and the limited experience accumulated in this country, there is inadequate data to dismiss vestibular disturbances as a factor in space flight operations. Further studies in this area, using experimental animals as near human proportions as possible, are needed to clarify several points: (a) the determination of the highest limits of "high-G" forces which the ear can tolerate without permanent damage; (b) the effects of repeated exposure to higher than normal, but in themselves tolerable, gravitational forces; (c) the effects of repeated exposure, as might be encountered in training, plus the flight plus weightlessness.

Since Spoendlin, et al. (38) has shown that the squirrel monkey can withstand gravitational forces of 5.4 to 10.9 G's in a single exposure of up to 10 minutes, our experiment attempts to elucidate the upper-limits of gravitational tolerance.

II. MATERIALS AND METHOD

GENERAL

Six chimpanzees, 4 female and 2 male, were used in this experiment. In each instance, the animal was anesthetized using Sernylan (R Parke Davis) and 5% pentobarbital (Nembutal) as indicated below. They were restrained in various positions on the Daisy Decelerator, and subjected to G forces ranging from 54 to 180. In cases where the animal failed to regain consciousness after the sled run, the animals were immediately x-rayed and a necropsy was performed. Those animals which recovered from the experimental procedure were observed in their cages for from 6 to 11 days. These were then once more placed under Sernylan and pentobarbital anesthesia and examined radiologically. Within half an hour after death, for those who succumbed to trauma, or while still under deep anesthesia, for those who survived, the left jugular vein was exposed and incised while the right common carotid artery was being cannulated. During the next 10 minutes about one quart of saline was infused under pressure of 15 to 20 psi. By this time the saline escaping from the vein was nearly clear. A solution of 10% buffered formalin was introduced through the cannula at the same pressure. Flow was continued until up to two quarts had passed into the system. The

skulls were then opened. The heads were removed and immersed in 10% formalin. They were shipped to our laboratory in this fluid.

On arrival in New York, the brains, including arachnoid and pia were taken from the cranium and inspected for evidence of superficial damage and hemorrhage. Both cerebellar and cerebral hemispheres were detached from the underlying brainstem and the cerebrum was sliced in the coronal plane. Any areas of brain, meninges or choroid plexuses which appeared questionable were cut out and prepared for microscopic study. Since the brain stems appeared completely normal, they were preserved for possible use in another study.

The dura was stripped from the bones and a search was made for epidural bleeding and small fractures. When this study was complete, the soft parts were scraped away from bone and the skulls were cut down to a piece (right and left) including the petrous, mastoid, and a small part of the squamous temporal bone. Using a dental engine and burrs, the floor of the external auditory canal was eroded to a point where the tympanic membrane could be visualized. When this had been inspected and photographed, the membrane was removed and the middle ear examined. The bone block was then further reduced in size, the final piece consisting of the petrous bone only. These were then processed for histological study (vide infra).

For convenience, both here and later, the animals are treated individually and are identified by the necropsy number. It should be noted that the ages of all animals are based on dental eruption dates and are considered to be accurate within $\pm$ six months.

SPECIFIC TREATMENT

A63-031 This was a mature female chimpanzee in apparently good health, bearing the colony number 35. Her age was estimated to be 76 months and weight 34 kg. On 21 May, 1963 she was first lightly anesthetized under nitrous oxide. This was followed immediately by the subcutaneous injection of 14 mg. of Sernylan R . Over the next hour and a half, she received 10 injections of pentobarbital, the total dose being 16.0 ml. Following the last injection, she was restrained on her back on the Daisy Decelerator with the head oriented in the direction of impact ($-G_z$). The thighs and legs were flexed at a 90° angle and the torso was securely strapped in position. The head was placed between two parallel plates which were near immediate contact with the shoulders. This animal was exposed to approximately 170 G forces at impact.

A63-032 This was a well-developed mature female named Dolly, bearing the colony number 49. Her age was 7.5 years and her weight

was 31.6 kg. On 16 May, 1963 she received 14 mg. of Sernylan followed over the next hour and a half by a total dose of 16.0 ml of 5% pentobarbital. She was restrained on the Daisy Decelerator in the head first, eyes up position ($-G_z$). She sustained 54 to 58 G.

A63-033 This was a male chimpanzee in apparent good health, bearing the colony number 45. His age was estimated at 9.25 years (111 months). No recent weight was given. On 23 May, 1963 he was anesthetized in a manner similar to the preceding and restrained on the Daisy Decelerator in the supine position, his head pointing in the direction of impact ($-G_z$). He sustained 120 G.

A63-035 This was a well-developed, mature and apparently healthy female chimpanzee named Miss Priss, bearing the colony number 50. Her age was 8.5 years and her weight was approximately 37.6 kg. On 16 May, 1963 she was given 17.5 mg. of Sernylan, followed by 80.0 ml. of Nembutal over a period of half an hour. She was restrained, supine, on the Daisy Decelerator with her feet pointing in the direction of impact ($+G_z$). She sustained 63-64 G.

A63-036 This was a well-developed, mature and apparently healthy chimpanzee named Glenda, bearing the colony number 106. Her age was 5 years and her weight was approximately 25.4 kg. On 21 May, 1963 she was given 15 mg. of Sernylan plus 6.0 ml. of pentobarbital. She was restrained on the Daisy Decelerator with the buttocks directed toward the impact. The eyeballs were in the down position ($+G_z$). She sustained 180 G.

A63-038 This was a well-developed, mature and apparently healthy male chimpanzee named Big Mike, bearing the colony number 131. His age was 11.75 years and he weighed approximately 59 kg. On 23 May, 1963 he was anesthetized under Sernylan and Nembutal at a dose level comparable to that used in the preceding cases. He was restrained on the Daisy Decelerator in the buttocks first, eyeballs down position ($+G_z$). He sustained 119.4 G.

All details concerning the past history of the animals, the deceleration experiments, the radiological examination and the necropsy findings were provided by Holloman Air Force Base through Robert H. Edwards, Major and William H. Strutton, Captain, USAF, MC.

HISTOLOGICAL METHODS

The entire heads with the calvaria removed, remained immersed in 10% formalin from May 1963, until August 1963. At this time, the

brains and skulls were examined. After removal of the brain, the skulls were cleaned and all but the temporal bones were cut away and discarded. The temporal bones were placed in fresh 10% formalin and this was changed twice between August and March of the following year (1964). During the first week in April 1964, the temporal bones were cut down still more to blocks which averaged 4.0 to 6.0 cm. in length and 3.0 to 4.0 cm. in width which included mainly the petrous portion. Each block was then put in a jar containing 20% formic acid plus 30 gm. of Win 3000. The formic acid was changed every two weeks. The decalcification process was carried out over a period of 50 days. Following this, each block was washed in distilled water, with two changes each day for a total of three days. The dehydration was carried out through a graded, frequently changed series of ethyl alcohol as follows: 50%, 2 days; 60%, 2 days; 70%, 2 days; 95%, 3 days; 100%, 3 days. The blocks were then cleared in an equal parts mixture of absolute ethyl alcohol and ethyl ether for 24 hours. The infiltration process extended over a period of 17 weeks in celloidin solutions whose concentrations ranged from 1% to 12% as indicated: 1% celloidin, 4 weeks; 2% celloidin, 3 weeks; 4% celloidin, 3 weeks; 6% celloidin, 2 weeks; 8% celloidin, 2 weeks; 10% celloidin, 2 weeks; 12% celloidin, 1 week. Each block was embedded and hardened over a period of 1 week by allowing the 12% celloidin to evaporate in a desicator containing Dririte and an open jar of chloroform. The top of the desicator was opened at least once each day. When ready, each block was fastened to a vulcanized fiber block set in a sliding microtome with the crest of the petrous bone lying uppermost. They were sectioned at 20 micra, the block being moistened continuously with 70% ethyl alcohol. The sections were placed between pieces of filter paper and stored in 70% ethyl alcohol until ready for staining. Each block was examined during the sectioning process and all sections lying superficial to the auditory mechanism were discarded, as were those which appeared to be (in the block) below the ear structures. The average number of sections saved from each block was about 600. In the series cut from A-63-31 left, every tenth section was selected for staining. In the A-63-38 left series, every fourth section was stained. In all of the others, every fifth section was used. Each section was treated individually, stained in a combination of Harris' Hematoxylin and Phloxin "B" and mounted in Permount on 2" x 3" slides.

III. OBSERVATIONS

IMMEDIATE POST-IMPACT EFFECTS

A63-031 The animal was alive and breathing when removed from the Daisy Decelerator but died 14 minutes after impact without regaining consciousness.

A63-032 Following impact, her condition was described as good although showing signs of early shock for about 10 minutes. She fully recovered and lived normally for the next 11 days at which time she was sacrificed.

A63-033 This animal was experiencing respiratory difficulty when removed from the Daisy Decelerator. Death occurred one hour and forty minutes after impact without return to consciousness.

A63-035 This animal showed signs of early shock for about one hour after impact. She then fully recovered and appeared normal for the next 10 days at which time she was sacrificed.

A63-036 This subject showed respiratory distress for three hours after impact and exhibited depression, presumably due to anesthesia, for seven hours. Following recovery from the above, the animal showed complete posterior paralysis. Six days following impact the subject was able to move about, dragging her lower extremities and was able to get up using her upper extremities only. Aside from these observations her health, vital signs and appetite were good. She was sacrificed seven days after impact.

A63-038 Following impact, the animal was considered to be in fairly good condition and had completely recovered within half an hour. After recovery, from the anesthesia, he was found to have no motor function in his lower extremities. On the fifth day, it was noted that there was no bladder function (urinary retention). The following day, the sixth day after impact, he was sacrificed.

RADIOLOGICAL OBSERVATIONS

A63-031 Transverse fractures were seen in the middle portion of both humeri and in the left femur 5 cm. distal to the greater trochanter. Greenstick fractures near the middle of each clavicle were also observed.

A63-032 No significant findings.

A63-033 A greenstick fracture was found in the right clavicle.

A63-035 Greenstick fractures were found in both femurs.

A63-036 Compression fracture between the fourth and fifth thoracic vertebrae was observed.

A63-038 Compression fracture between the seventh and eighth thoracic vertebrae was seen.

NECROPSY FINDINGS - EXCEPT BRAIN AND EARS (SUMMARY)

A63-031

Attributable to experiment. External: swellings over transverse fractures; two linear contusions on each side of lower neck; superficial crimson skin due to straps. Internal: mediastinal hemorrhage; ruptures of thoracic aorta; intimal tears in pulmonary trunk, pulmonary hemorrhage; myocardial hemorrhage, acute and focal; contusion of tracheal wall with partial obstruction of the air passage; rupture of spleen with resultant hemoperitoneum; acute bilateral hemorrhage into crura of diaphragm; hemorrhage into liver, acute, subcapsular and focal; hemorrhage, acute into visceral mesenteries; hemorrhage, acute into tail of pancreas; fractures with displacement of bones in both femurs, left humerus and both clavicles.

Attributable to other causes: hepatitis, subacute and focal; acute splenitis; false passage adjoining urethra, chronic; chronic pyelonephritis.

A63-032

Attributable to experiment. External: no significant findings. Internal: diffuse pleural and parenchymal pulmonary hemorrhage; diffuse bilateral perinephric capsular hemorrhages; hemorrhagic lesions in the gastrosplenic ligaments and the ligaments between the hepatic flexure of the colon and liver; pleural petechial hemorrhages in the pleural reflections over the sides of the thoracic vertebrae; focal and acute hemorrhage within the capsule of the right lobe of the liver; focal acute pancreatic hemorrhage.

Attributable to other causes: none suggested.

A63-033

Attributable to experiment. External: nothing significant. Internal: rupture of right subclavian artery with hemorrhage into mediastinum; compression of venous return to heart secondary to the preceding; rupture of intimal surface of thoracic aorta; retroperitoneal hemorrhages - periadrenal and perirenal and around neck of bladder; acute subendocardial hemorrhage; hemorrhage into liver in area of ligamentous attachments; hemorrhage into tail of pancreas; hemorrhage into fascial support of spleen; hematuria, probably due to urethral laceration.

Attributable to other causes: epicarditis and myocarditis.

A63-035

Attributable to experiment. External: no visible signs. Internal: acute focal bilateral subpleural hemorrhage and bleb formation (minimal); acute focal periacinar pancreatic hemorrhage (minimal); acute focal bilateral glomerular and interstitial renal hemorrhage (minimal); acute focal bilateral pericapsular renal hemorrhage (minimal).

Attributable to other causes: acute diffuse hepatitis.

A63-036

Attributable to experiment. External: no evidence of pathology. Internal: moderate hemorrhage about hilar areas of right and left lungs plus adjacent mediastinal hemorrhage; focal perinephritic connective tissue hemorrhages; focal, acute and old hemorrhage on dorsal pleural surface, left lower lobe of lung; focal hemorrhages on mesenteric reflections of ascending colon, on right iliac crest, on right lobe of liver along hepatocolic ligaments; hematoma measuring 5x3x2 cm.with necrosis in the iliopsoas muscle adjacent to the second and third lumbar vertebrae circumscribing the first portion of the femoral and lumbosacral nerves; hematoma, measuring 3x2x1 cm. between ribs 7 and 8 adjacent to their vertebral articulations; compression and fracture of the fourth and fifth thoracic vertebrae with compression and necrosis of the spinal cord between these segments.

Attributable to other causes: none suggested.

A63-038

Attributable to experiment. External: no discernible lesions. Internal: oblique vertebral fracture through the sixth, seventh and eighth thoracic segments resulting in thoracic scoliosis and spinal cord compression together with epidural focal hemorrhages at the level of the seventh thoracic vertebra; retropleural hemorrhages at the levels of the articulations of the sixth, seventh and eighth ribs with the vertebral columns; bilateral hemorrhage at the hilus of the lungs and in the mediastinum; subpleural and parenchymal focal hemorrhage both recent and old in the left lower, right middle and lower lobes of the lungs; subpleural blebs in left lower and right middle lobes of the lungs; bilateral pleural hemorrhages and fluid (100 ml. per cavity); diaphragmatic hemorrhages on both pleural and peritoneal sides circumscribing the hiatuses of the esophagus and aorta; hemorrhage into the falciform ligament at its point of attachment to the capsule of the liver and along the coronary ligament; parenchymal lacerations and hemorrhage in right lobe of liver; multiple linear lacerations of the diaphragmatic surface of the spleen with clots on both anterior and gastric surface; hemorrhage

along the superior surface of the pancreas and inferior surface of the stomach; massive bilateral periadrenal hemorrhage more severe on the left; perinephric and capsular kidney hemorrhages; hemorrhage into the mucosa of the kidney calyxes, pelvis, ureters and bladders which contained a large fibrin clot 5x5x3 cm.; hemorrhage into the perineural sheaths of the femoral and lumbosacral nerves bilaterally; peritoneal hemorrhage, approximately 400 ml. in volume; hemmorhage into transverse mesocolon, measuring 8x8 cm.

Attributable to other causes: none suggested.

POSTMORTEM ON SKULL, MENINGES AND BRAIN

A63-031

Gross. Neither the scalp, calvarium nor skull showed anything remarkable. The dura, leptomeninges and brain surface were also essentially normal except for extreme congestion of the cerebral vessels plus a bloody exudate in the area of the cerebello-pontine angle (Fig. 1). Coronal sections revealed congestion of the blood vessels around the basal ganglia. The skull and dura were negative.

Microscopic. There were no lesions within the brain parenchyma. Acute passive congestion of the basal ganglia was observed. There was a questionable acute hemorrhage around some of the vessels of the dura.

A63-032

Gross. The external aspects of the brain and leptomeninges are not remarkable. Coronal sections show a cystic space involving the head of the caudate nucleus on the right side (Fig. 3). It measured 1.0 cm. in diameter and appeared to compress the ventricle. The skull and dura were negative.

Microscopic. The perivascular spaces are somewhat prominent. No reactive changes were seen and it was therefore concluded that the cyst seen on gross inspection was an artefact.

A63-033

Gross. There was nothing remarkable about the calvarium and the skull in general except for a fine crack in both temporal bones. There appeared to be neither epidural, subarachnoid nor intracerebral bleeding, although there was much congestion of the superficial cerebral vessels (Fig. 4). However, a subdural clot, measuring 3-5 ml. in volume was found in the region of the cisterna magna (Fig. 5). Coronal sections of the brain were not remarkable.

Microscopic. Sections in the frontal lobe show occlusion of small cortical vessels by old thrombosis. Other vessels are surrounded by lipid-laden phagocytes. The nearby leptomeninges show a few inflammation cells which are thought to be due to an old traumatic or infectious process.

Note: The subdural clot is possibly postmortem due to the trauma in removal of the calvarium.

A63-035

Gross. Although two depressed areas appear on the superior aspects of the cerebellar hemispheres (Fig. 6), these were interpreted as artefacts. No significant changes were noted in the leptomeninges. In coronal sections some congestion of the blood vessels was seen in the region of the basal ganglia and internal capsule on the right side. The skull and dura were negative.

Microscopic. None of the sections showed anything remarkable.

A63-036

Gross. Except for some discoloration in the region of the pons, the brain, meninges and skull were not remarkable. Coronal sections failed to show any significant pathology (Fig. 2).

Microscopic. Sections of the brain were not remarkable. Many melanophores were seen in the leptomeninges.

A63-038

Gross. External aspects of the brain, meninges and skull were normal. Coronal sections showed xanthomata in the choroid plexus of both lateral ventricles.

Microscopic. Except for the xanthomata no abnormalities were seen.

GROSS EXAMINATION OF THE TYMPANIC MEMBRANE AND MIDDLE EAR

A63-031 - Right

The tympanic membrane was intact. The ossicles and intrinsic muscles appeared normal.

A63-031 - Left

The tympanic membrane was intact (Fig. 7). The ossicles and intrinsic muscles appeared normal. There was evidence of blood along the posterior border of the foot plate of the stapes.

A63-032 - Right

There was a tear in the tympanic membrane without displacement. The ossicles and intrinsic muscles were normal.

A63-032 - Left

The lower half of the tympanic membrane was blown out (Fig. 8). Although the ossicles and intrinsic muscles appeared normal, traces of blood were seen in the middle ear cavity, posteriorly.

A63-033 - Right

The tympanic membrane was intact but was depressed ventrally, below the umbo. The mucosa of the middle ear was engorged but no definite hemorrhage could be seen.

A63-033 - Left

The posterior inferior part of the tympanic membrane was blown in with fragments of the membrane and hairs from the external canal deposited in the middle ear cavity. The ossicles and intrinsic muscles were normal.

A63-035 - Right

A triangular piece was torn out of the tympanic membrane (Fig. 9). There was no abnormality in the ossicles or intrinsic muscles. No hemorrhage seen.

A63-035 - Left

There was a single tear in the tympanic membrane without displacement. The ossicles and intrinsic muscles were normal. There was no hemorrhage.

A63-036 - Right

A small tear was observed in the lower part of the tympanic membrane (Fig. 10). The middle ear structures were normal and no hemorrhage was seen.

A63-036 - Left

The tympanic membrane and all structures of the middle ear were normal. No hemorrhage was seen.

A63-038 - Right

The tympanic membrane was intact and all contents of the middle ear were normal. No hemorrhage was observed.

A63-038 - Left

The tympanic membrane was intact. The ossicles and intrinsic muscles were normal but a bloody discoloration was seen around the round window.

MICROSCOPIC STUDY

A63-031 - Right

Petrous bone in general. Near the edges of the section many of the peripheral air cells, especially those along the trimmed portions of the block, showed large amounts of coarsely granular material including bone fragments (Fig. 11). Occasionally a similar substance was seen in some of the deeper-lying spaces. In addition, in several of these spaces, a dense, homogeneous and strongly acidophilic material was encountered (Fig. 12). The venous plexus around the carotid artery was greatly engorged (Figs. 13 & 14). In some of the most caudal sections of this block, these veins were so distended that it gave the impression that some of them had actually ruptured forming extravascular clots (Fig. 14).

Vestibular apparatus. As near as could be determined, there were no breaks in the membranous labyrinth. However, there were distinctly abnormal conditions in all of the ampullae. In the superior canal, the cupula was far removed from the crest (Fig. 15) but the processes of the hair cells appeared intact (Fig. 16). In the ampulla of the lateral canal, the cupula is "cloud-like" and is elevated almost completely from the apex and one side of the crest (Fig. 17), although the hair cells appear normal (Figs. 18 & 19). This was also seen in another area of the same crest. The plane of section through the ampulla of the posterior canal was not comparable to that of the other two so it was difficult to assess the damage, if any, in this region. However, neither cupula nor hairs were evident. The otolithic membranes of both utricle and saccule were definitely different than those described by us as being "normal" (House, et al., 24).

Cochlea. This appeared to be essentially normal with little if any distortion of its parts (Figs. 20-22). The only change was the appearance of a light pinkish granular material found especially in the scala vestibuli (Fig. 20).

Secondary tympanic membrane. This was intact throughout.

A63-031 - Left

In general this was a very poor series. Both decalcification and infiltration were incomplete. However, there appears to have

been a considerable amount of hemorrhage. Some of the disruption of the bone, including the modiolus and the osseous spiral lamina may have occurred antemortem as a result of the experimental procedure. The only definite statement that can be made is that the secondary tympanic membrane is intact.

A63-032 - Right

Petrous bone in general. Many of the air cells showed a thickening of the endosteum and their lumina were seen to contain a faintly acidophilic debris which also included mononuclear cells (Fig. 23). There may be some compression of small blood vessels against the bone. There were no changes in the carotid artery or its surrounding venous plexus.

Vestibular apparatus. In this series, a very striking change was seen, first in a marked compression of a long strip of the posterior canal, beginning first as a flattening on one side just above the origin of the canal from the common crus (Fig. 24). This condition persists and actually worsens further along the course of the canal (Fig. 25). There were likewise changes in the crests of the superior and posterior (Figs. 26 & 27), canals. In all instances, the crests were shifted in position and can be seen in the latter two illustrations as a thin film of homogeneous material along one side of the crest. In none of these were the hair processes clearly visible. The wall of the saccule has been compressed against its macula (Figs. 28 & 29). The otolithic membranes were atypical in both cases.

Cochlea. In this series, the vestibular membranes are quite irregular and a quantity of faintly acidophilic, granular material was found in both the cochlear duct and in the scala tympani.

Secondary tympanic membrane. This was found to be intact (Fig. 30) throughout.

A63-032 - Left

Petrous bone in general. In this series, the petrous air cells are clear and there is no evidence of congestion or rupture of any of the veins of the plexus around the carotid artery.

Vestibular apparatus. In this series, there was once again a compression of the superior canal (Fig. 31), even down near its ampulla (Fig. 32), as well as in the posterior canal. Changes have also occurred in crests of these canals. In the superior canal the cupula is atypical in form and is elevated well above its apex (Figs. 34 & 35). The hair cells appear normal (Fig. 35). The

cupula of the lateral canal has a "cloud-like" appearance and has shifted away from its apex (Fig. 36), but the hair cells are normal (Fig. 37). There is a proteinaceous material in the lumina of the ampullae and the scalae which has the appearance of plasma proteins. The maculae of both utricle and saccule are essentially normal. In one area, the otolithic membrane of the macula utricluli is completely typical (Figs. 38 & 39). In another region of the same macula, the otolithic membrane seems more diffuse and is very slightly elevated from the surface of the macula (Fig. 40)

Cochlea. In some coils of the cochlea a light granular substance was found in the scalae and in the cochlear duct (Figs. 41 & 42). In one coil, the vestibular membrane of the cochlea was quite irregular but in general the cochlear structure was quite normal.

Secondary tympanic membrane. This structure was intact throughout (Fig. 42).

A63-033 - Right

Petrous bone in general. Many of the air spaces throughout this block are filled with a pale, faintly acidophilic substance, probably protein-rich. In some areas of the precipitate, groups of mononuclear cells were found (Figs 43-45). The latter appear to be macrophages which may have come from the adjacent tissues. The carotid canal is clear and there was no engorgement of the venous plexus.

Vestibular apparatus. Both the superior and posterior crest (Fig. 46) show abnormal cupulae. The lateral canal was not cut in the proper plane to be able to demonstrate adequately any structural alterations. The otolithic membranes associated with the maculae of both utricle and saccule were not clearly demonstrated but appeared to be at least in part, missing.

Cochlea. Throughout much of the cochlea there was either great irregularity (Fig. 47) of the vestibular membrane or it was compressed in its lower medial portion so that it rested on top of the organ of Corti (Fig. 48). The cochlear duct and the scalae were relatively clear of precipitate.

Secondary tympanic membrane. This was intact throughout (Fig. 49).

A63-033 - Left

Petrous bone in general. Two types of material were encountered in the petrous air cells. The first type was seen among the largest spaces in the upper portion of the block. This was a homogeneous, deeply acidophilic substance which nearly fills the space (Fig. 50). This stains with the appearance of protein and could be of vascular or lymphatic origin. The second was less homogeneous, more granular and less deeply acidophilic (Fig. 51). The carotid canal was clear of blood and there was no engorgement of the venous plexus around the artery.

Vestibular apparatus. The posterior canal is either greatly indented (Figs. 52-54) or nearly completely collapsed (Fig. 55). In one area of the posterior canal a mass of cells appears in its lumen (Figs. 53 & 54). These cells have the same staining quality as some of those of the labyrinthine wall and probably represent a further invagination of one side of the canal. The common crus also was flattened on one side and it contained an abnormally large amount of apparently proteinaceous substance (Figs. 56 & 57). Although hair cells are clearly visible on the crest of the superior canal, the cupula is completely missing (Figs. 55 & 60). Essentially, the same picture is seen of the crest of the posterior canal (Fig. 61). The entire saccule is collapsed in this series (Fig. 62).

Cochlea. The apical coil of the cochlea shows a marked compression of the vestibular membrane on the left side and compression, but to a lesser degree on the right side. The middle coil of the cochlea shows extreme compression on both sides, the lumen of the cochlear duct being almost completely obliterated (Figs. 63 & 64).

Secondary tympanic membrane. This was intact throughout. (Fig. 65).

A63-035 - Right

Petrous bone in general. Some of the air spaces display some of the same proteinaceous material of vascular or lymphatic origin seen in other figures. There is also evidence of old focal capillary hemorrhages, which might have occurred at the time of impact. The carotid artery and associated veins are free of signs of hemorrhage or congestion.

Vestibular apparatus. In this series, all of the canals maintained their normal configuration. The crest of the superior canal is without its cupula (Fig. 61), there is a considerable amount of granular acidophilic material in its ampulla. The crest of the lateral canal, showing normal hair cells, but no cupula, was also

observed (Figs. 67 & 68). The otolithic membrane over the macula utricli is elevated from the surface of the macula and there appear to be red blood cells imbedded in it (Figs. 67 & 69).

Cochlea. In nearly all coils of the cochlea, there was great compression of the vestibular membrane (Figs. 70-72). Accumulations of proteinaceous material is also seen in the cochlear duct (Figs. 71 & 72).

Secondary tympanic membrane. This is intact throughout (Fig. 73).

A63-035 - Left

Petrous bone in general. Throughout most of the block, many of the large petrous air spaces were filled with a protein-rich fluid which varied from above downward in density, homogenicity, the intensity of its acidophilitic reaction and the extent of filling of the spaces (Figs. 74 & 75). The carotid canal was free of congestion and hemorrhage.

Vestibular apparatus. A considerable amount of distortion was found over a large area of the medial limb of the superior canal (Fig. 76). The upper portion of the posterior canal is likewise distorted. The cupulae of all of the ampullary crests are either entirely missing or completely atypical. The hair processes are also missing as shown in the illustration of the crest of the lateral canal (Fig. 77). The otolithic membranes of both maculae are also atypical.

Cochlea. On one side of the middle coil of the cochlea, the lumen of the cochlear duct is almost completely obliterated (Fig. 78). This same condition is seen to persist some 250 microns farther along the coil on the same side (Fig. 80), while on the other side of the modiolus, the same duct is not as drastically compressed (Fig. 79). Some 800 microns beyond the area shown in Figure 79, the duct on the left side is just as strongly compressed while in the apical coil the compression is less marked.

Secondary tympanic membrane. This membrane is intact throughout (Fig. 81).

A63-036 - Right

Petrous bone in general. The petrous air cells are clear of all extraneous material and there is no evidence of hemorrhage or congestion in the carotid canal.

Vestibular apparatus. The semicircular canals appear normal in shape with little if any distortion. The only abnormality seen was a very marked depression of one wall of the ampulla of the posterior canal (Fig. 82). The cupula of the crest of the superior canal is "cloud-like" and is completely elevated from the crest (Figs. 83 & 84). The cupula of the lateral ampullary crest is completely removed but may be included in the unidentifyable material seen in the ampulla above and to the left of the crest (Fig. 85). The cupula for the crista ampullaris of the posterior canal appears to be distorted and is seen streaming away above the crest (Fig. 82). There is an unusually large amount of proteinaceous material in the ampullae (Figs. 82, 84, 85). This may be a subepithelial protein exudate from venular compression. The otolithic membranes are lifted off from both maculae and may be a part of the unusually large amount of protein material seen in the lumen (Figs. 86-88).

Cochlea. In general the cochlear configuration was normal (Figs. 89-92) although in some areas an unusual amount of precipitate was seen in the cochlear duct (Figs. 90 & 91).

Secondary tympanic membrane. This was intact throughout (Fig. 93).

A63-036 - Left

Petrous bone in general. There is an abnormal amount of acidophilic material throughout the entire block. In the more cephalic sections, it is very light, only faintly acidophilic and free of cells (Fig. 94). This is edema-like fluid, suggestive of vascular origin. In more caudal sections, it becomes more dense, vacuolated and cell-rich (Figs. 95-97). In the most caudal areas, the material is very homogeneous, dense and intensely acidophilic (Figs. 96 & 97). In this region the endosteal lining of the spaces is extremely thickened (Figs. 96 & 97). The carotid canal is free of hemorrhage and congestion.

Vestibular apparatus. In this series, the wall of the semicircular canals are free of distortion. Although the crests of all the ampullae are abnormal, only that of the lateral canal has been illustrated since they were generally alike in that there is no typical cupula and the hair processes are not visible. A thin film of homogenous material which may represent a remnant of the cupula may be seen in the last of this series (Figs. 98-101). Overall, the saccule has been depressed upon its macula (Figs. 103-104). The otolithic membrane is almost impossible to detect (Figs. 103 & 104) while that ofthe utricle is almost completely lifted off its macula (Fig. 102).

Cochlea. The vestibular membrane is depressed posteriorally to a greater or lesser degree throughout most of its extent (Figs. 105-107).

Secondary tympanic membrane. This membrane is intact throughout.

A63-038 - Right

Petrous bone in general. A heavy eosinophilic material was present in many of the air spaces of the petrous bone (Fig. 108). In some of the spaces, groups of mononuclear cells, probably macrophages were seen (Fig. 109). This material appears to be a mixture of blood and plasma proteins. In addition to congestion of the venous plexus, in the carotid canal there was evidence of extravascular clots (Fig. 111).

Vestibular apparatus. Except for a slight compression in the lateral canal (Fig. 110) there was no extensive damage although the cupulae and otolithic membranes were not completely normal.

Cochlea. This structure was basically normal.

Secondary tympanic membrane. This was intact throughout.

A63-038 - Left

Petrous bone in general. The air spaces are clear in this series. However, there is great congestion of the periarterial venous plexus and there is evidence for hemorrhage into the connective tissue of the carotid canal (Figs. 112-113).

Vestibular apparatus. The walls of the semicircular canals are essentially normal as are those of both the utricle and saccule. At its apex, the crest of the superior canal shows the only completely normal cupula in the entire series of twelve ears (Figs. 115 & 116). In sections on the sides of the crest no cupula is seen but the hair processes seem normal (Fig. 114). The macula utriculi is normal (Fig. 117).

Cochlea. The cochlea seems to be essentially normal (Fig. 118), except for an unusually large amount of proteinaceous material and some debris in the region of the helicotrema (Fig. 119).

Secondary tympanic membrane. This was intact throughout.

IV. DISCUSSION

It is apparent that chimpanzees, strapped in the supine position with the head directed toward the impact with the brake were unable to withstand G forces of 120 or over, for both animals subjected to such stress died within 90 minutes after the conclusion of the sled run. The third animal in this supine, head-first group which did survive was exposed to less than half these forces (54-58 G's). One animal only was placed in the supine, feet-first attitude and survived the impact at 63-64 G's. Since the cause of death in the two animals, A63-031 and A63-033 was massive and multiple internal hemorrhages, without evident cranial trauma, it is doubtful whether this position would be any more effective in preserving life than the head-first attitude if comparable stress were applied. It was also established, that chimpanzees placed in the buttocks-first, eyes down position could survive up to 180 G's, although there were fractures of the vertebral column both at 119 and 180 G's. The evidence is insufficient to draw conclusions concerning the effect of age, weight or sex on the ability to withstand these stresses.

Except for the damage to the spinal cord related to fractures of the thoracic vertebrae in animals A63-036 and A63-038, there appears to be no direct damage to the central nervous system. Congestion of the superficial cerebral vessels and blood (sub-dural) in the region of the cisterna was seen in both chimpanzees which succumbed. The presence of these findings in the head-first animals should not be surprising. However, these specimens died too soon to determine whether there might have been permanent sequelae.

It is difficult to account for the bilateral hair-line fractures in the temporal bones of animal A63-033 even though it did receive the impact head first. No breaks were found in any of the other skulls. These cracks may account for some of the microscopic findings encountered in this specimen.

There apparently is a great deal of individual variations in the ability of the tympanic membranes to withstand these forces. It is a well-established fact that these membranes can be blown in depending upon the extent and rapidity of change in external pressures. Covell & Eldredge (7) and Davis, et al. (10) have commented on their (and other) investigations showing membrane rupture in response to intense sound. The former (7) described sub-epithelial hemorrhages in the middle ear with an accumulation of bloody fluid near the round window after guinea pigs had been exposed to intense sound. We found this on the left side in A63-031 and A63-032 and on the right side in A63-033. However, it should be noted that this

condition was observed only in those animals placed in the head-first position and one of these, A63-033, had cracks in the temporal bone. The damage which we noted in the tympanic membranes appeared to be related neither to the G forces applied nor to orientation toward impact for the two animals, A63-032 and A63-035 subjected to least stress showed bilateral ruptures of the tympanic membranes.

As near as could be determined, there were no fractures nor disarticulations among the auditory ossicles. The intrinsic muscles also appeared undamaged.

Apparently the pressure within the labyrinth was never great enough to disrupt the secondary tympanic membrane in any of the specimens. As others have so adequately pointed out before us, it is difficult to evaluate the effect of experimentation upon the membranous labyrinth and its associated sensory receptors due to the enormous technical difficulties involved in preparing the tissues. This is especially true in the large animals where these delicate structures become imbedded in ever-increasing amounts of extremely hard bone. This is perhaps one of the reasons why much of the work has been done on such species as the guinea pig. The great variability of tissues present in the petrous temporal bone may result in uneven fixation, although the fixation is perfused with the animal under deep anesthesia. The second difficulty involves the length of time the tissue is exposed to rather strong acid in the decalcification process, which, in this case, was nearly two months. A third point, is the problem of infiltration, for, to obtain good sections without distortion, all canals, and all cavities should be filled with the embedding medium (celloidin). Even using a graded series of this substance over a period of four months, it was impossible to tell, until one had sectioned deep into the block, whether infiltration was complete and then it is usually too late. A fourth point, which also cannot be predicted before sectioning, even with chemical tests, is whether there may not be small areas of calcium left deep in the bone. If such exist, the tissue around is often scratched or torn and subsequent sections frequently are distorted by the nicks made in the knife resulting from the encounter with undecalcified bone. And, last, but by no means least, of the problems, lies in the density differential between even the most perfectly demineralized bone and the fine walls of the membranous labyrinth. As the knife passes from a large mass of extremely dense osteoid tissue to a relatively smaller area containing a delicate membrane, tearing, pulling or stretching frequently occurs. This is especially true of the small trabeculae of connective tissue which traverse the perilymphatic spaces to help suspend the membranous within the osseous labyrinth. It is also difficult to quantitate

the amount of precipitation of the protein substances of the endolymph and perilymph, since there appears to be some variation in this even among normal animals. Therefore, we have attempted to emphasize only those things which are strikingly different from our findings in the previous base line studies (House, et al. 24).

In light of the above statements, it must be admitted that we do not know whether any of the walls of the membranous labyrinth were actually broken as a result of the experiment. Nor can we state with certainty whether the breaking of the membranes away from the bony walls was of experimental origin.

The congestion and hemorrhages found bordering the carotid artery were found exclusively in two animals, A63-031 and A63-038, both of which received G forces of 119 or above. In both cases, there was evidence of much internal bleeding as a result of the impact, in the former sufficient to lead to death within 15 minutes. It does not seem illogical that the periarterial venous plexus should engorge nor that some of these thin-walled vessels might be ruptured as they were violently compressed between the artery and the bony wall of the carotid canal.

The peculiar type of debris found in the petrous air spaces in A63-031 - right series may, of course, have been the fragments of bone or connective tissue resulting from trimming the block. This is suggested by the fact that it was seen in the spaces at the periphery along the cut edges. However, some of it was encountered in a few deeper spaces. As evidenced by the full necropsy report, this animal had several bone fractures and sustained severe damage in both thorax and abdomen. Thus, the possibility that this resulted from trauma cannot be completely precluded.

The more homogeneous, acidophilic substance seen in eight of the other eleven series was almost impossible to trace to its source, although it definitely was related to the experimental procedure. In only one series, A63-038 - right, could one say, there actually was blood in any of the spaces. However, it had all the appearances of proteinaceous material, certainly similar to the plasma proteins and therefore of either vascular or lymphatic origin. In one series only, A63-035 - right, focal, subepithelial capillary hemorrhages were detected which might have permitted passage of the escaped plasma through the epithelium into the spaces. In one series, A63-036 - left, the material seems to be a frothy, edema type fluid. In the other cases, we can only assume that the shock of the impact with all of its generalized sequelae lead to a marked increase in capillary permeability or that the sudden jolt lead to

compression of the venules which also could account for an outflow of plasma proteins.

The mononuclear cells found in about half of these fluid-filled spaces appeared to be macrophages, probably arising from the sub-endosteal connective tissue. In the A63-032 and A63-038 series, where the animals lived 6 to 11 days after impact, one might concede that this macrophage infiltration was an attempt to clean out the protein substance not normally found in this location. However, these cells were also found in the A63-033 animal, one which died within 90 minutes after impact and it seems unlikely, although possible, that macrophages would have been mobilized that quickly for this purpose.

The marked thickening seen in the endosteal lining of the air spaces in two of the series, especially in A63-036 - left, is suggestive of edema rather than proliferation.

Although one must be cautious in evaluation of distortion of the semicircular canals, the evidence seems to indicate that these changes are of traumatic origin. In 75% of the cases where these changes were found, they occurred in the superior or posterior canals or the common crus especially in those instances when the head or feet were directed toward the impact. In such positions, these are the canals which would be most vulnerable. In the one case, where the lateral canal was damaged, the animal was in the buttocks first, head down position. Both Lawrence (25) and Riopelle, et al. (31) reported identical damage after subjecting monkeys, restrained in the sitting position, to intense up and down vibration.

Although the changes in the cupulae have not been previously reported, the fact that these may be completely washed away or torn from their normal positions or even disintegrated would not be surprising. Since these are the kinetoreceptors which are intended to pick up flow of endolymph in the semicircular canals in response to ordinary movements of the head, they are not adapted to such violent forces. In some instances, those forces which wrenched away the cupulae also broke off the hair process by the same action. The distortions, elevations or destruction of the otolithic membranes have also been noted (25 & 32) in response to vibration in monkeys. Similar effects on the otolithic membrane after rotation or centrifugation have also been found (13, 23, 40). McCabe and Lawrence (29) also reported damage to otolithic membranes in response to intense sound.

The excessive amounts of proteinaceous material encountered in the vestibular labyrinth of some of the animals is not normal.

This may be due to the presence of excessive plasma proteins which entered the labyrinth from damaged vascular epithelium, as suggested by Covell & Eldredge (7). The possibility that it occurs as a result of a mixture of perilymph and endolymph due to outright ruptures in the membranous labyrinth cannot be excluded (vide infra).

The presence of precipitated materials in the cochlear duct and/or the scalae is probably due to the presence of plasma proteins as indicated for the vestibular mechanism.

The other damage, seen in the cochlea, namely the collapse of the cochlear duct with the compression of the vestibular membrane, occurred in over 50% of the cases. This was not the typical pathology noted by many others in response to sound of various frequencies, but is the sort of picture that might result from a great increase in perilymphatic pressure. Certainly, if enough force were applied externally, so great the tympanic membrane was ruptured, the resultant sudden incursion of the foot plate of the stapes could violently raise the perilymphatic pressure in the scala vestibuli. It is probable that this force either ruptured the vestibular membrane in one or more places or increased its permeability, permitting the escape of endolymph. In either case, the membrane would remain depressed because of the lack of fluid in the cochlear duct.

It is more than likely that the collapsed saccule seen in several series is also the result of lowered levels of endolymph, possibly due to a rupture in the wall of the saccule itself or may be associated with a break in the cochlear duct.

V. CONCLUSIONS

1. Gravitational forces in excess of 50 G's may rupture the tympanic membranes.

2. These same forces may result in subepithelial hemorrhages of the middle ear.

3. In the majority of cases, regardless of forces, the petrous air spaces are filled, to a greater or lesser degree, with a proteinaceous material, probably derived from blood, or from the lymphatics. In several cases, it definitely had the appearance of edematous fluid. This may be due to increased capillary permeability in shock or to compression of the veins.

4. When exposed to forces in excess of 119 G's, there is engorgement of the pericarotid venous plexus and hemorrhages of some of these veins.

5. In the supine position, regardless of orientation of the head, there is distortion of both the superior and posterior semicircular canals.

6. Regardless of the gravitation forces, at least in excess of 53 G's, the cupulae of the crests are either completely destroyed or are elevated from the crests. In nearly half of the cases, the hair processes are also broken off from the crests.

7. In the majority of cases, the otolithic membranes are either: missing, elevated from their maculae, or, in some manner distorted.

8. In several instances, the saccule is partially or almost completely collapsed.

9. In several cases, there was an unusual amount of proteinaceous material in the lumina of the vestibular apparatus. This may be due either to plasma exudate from beneath the epithelium or to a mixture of perilymph and endolymph resulting from actual ruptures of the labyrinthine walls or to an increase in their permeability.

10. In half the cases, there was collapse of the cochlear duct by depression of the vestibular membrane. This may be the result of loss of endolymph.

REFERENCES

1. Alexander, I.E. and F.J. Githler, 1951, J. Comp. and Physiol. Psychol. 44:513-524.

2. Brown, J.L. and M.G. Lechner, 1955, NADC-MA-5503 Johnsville, Pa., U.S. Naval Development Center.

3. Covell, W.P., 1936, Arch. Otolaryngol. 23:633-64.

4. Covell, W.P., 1938, Ann. Otol., Rhin. & Laryngol. 47:342-346.

5. Covell, W.P., 1938, Arch. Otolaryngol. 27:438-443.

6. Covell, W.P.,1953, J. Comp. Neurol. 99:43-59.

7. Covell, W.P. and D.H. Eldredge, 1951, U.S.A.F. Technical Report No. 6561, Pt. 1:1-33, Air Research and Development Command, Wright-Patterson Air Force Base, Ohio.

8. Covell, W.P. and D.H. Eldredge, 1952, U.S.A.F. Technical Report No. 6561, Pt. 2:1-67, Air Research and Development Command, Wright-Patterson Air Force Base, Ohio.

9. Covell, W.P. and D.H. Eldredge, 1954, U.S.A.F. Technical Report No. 6561, Pt. 3:1-19, Air Research and Development Command, Wright-Patterson Air Force Base, Ohio.

10. Davis, H., 1952, J. Acoust. Soc. Am. 25:1180-1189.

11. Davis, H., C.T. Morgan, J.E. Hawkins, Jr., R. Galambos and L.N. Smith, 1950, Acta. Otolaryngol. Suppl. 88:57 pp.

12. Davis. H., H.O. Parrack & D.H. Eldredge, 1949, Ann. Otol., Rhinol. Laryngol. 58:732-738.

13. de Kleyn, A. and C. Versteegh, 1933, Pflug. Arch. ges Physiol. 232:454-465.

14. Dickson, E.D. and D.L. Chadwich, 1951, J. Laryngol. and Otol. 65:154-165.

15. Duane, T.D., E.L. Beckman, J.E. Ziegler and H.N. Hunter, 1953, NADC-MA-5305, Johnsville, Pa.: U.S. Naval Air Development Center.

16. Eldredge, D.H., N.P. Covell and H. Davis,1957, Laryngoscope 67:66-84.

17. Frankel, O.M., 1940, Bull. Biol. Med. U.S.S.R., 9:69-72.

18. Gell, C.F., 1961, Aerospace Med. 32:1109-1111.

19. Guild, S.R., 1919, J. Lab. & Clin. Med. 4:153.

20. Hamberger, C. and H. Hayden, 1945, Acta Otolaryngol. Suppl. 61:1.

21. Hamberger, C., H. Hayden and G. Nillson, 1949, Acta Otolaryngol. Suppl. 75: 124-133.

22. Hammer, G., 1956, Acta Otolaryngol. Suppl. 127:1.

23. Hasegawa, T., 1963, Arch. Ohr-Nas-Kehlkopfheilk, 182:555-559.

24. House, E.L., B. Pansky, M.S. Jacobs & B.M. Wagner, 1964, Technical Documentary Report No. ARL-TOR-64-1;1-339.

25. Lawrence, M., 1958, U.S. Army Med. Research, Lab. Report No. 358, Part 3.

26. Lawrence, M. and C.L. Blanchard, 1954, Industrial Med. and Surg. 23:193-200.

27. Lawrence, M. and P.A. Yantes, 1957, Ann. Otol., Rhinol. & Laryngol. 66:593-621.

28. Lurie, M.H., H. Davis and J.E. Hawkins, 1944, Laryngoscope 54:375-386.

29. McCabe, B.T. and M. Lawrence, 1958, Acta Otolaryngol. 49:147-157.

30. Mangabeira-Albernaz, P.L., W.P. Covell and D.H. Eldredge, 1959, Laryngoscope 69:1478-1493.

31. Miller, E.L., R.S. Kellogg and A. Graybiel, 1964, Thirty-fifth annual meeting Aerospace Medical Assoc., Miami Beach.

32. Riopelle, A.J., M. Hines and M. Laurence, 1958, U.S. Army Medical Research Lab. Report No. 358:1-57.

33. Ruedi, L., 1954, Ann. Otol., Rhinol. & Laryngol. 63:702-720.

34. Ruedi, L. and W. Turner, 1951, Arch. Otolaryngol. 54:534-541.

35. Schuknecht, H.F., 1950, Ann. Otol., Rhinol, and Laryngol. 59:330-358.

36. Smith, C.A., W.P. Covell and D.H. Eldredge, 1954, U.S.A.F. WADC Technical Report No. 54:21:1-31.

37. Smith, K.R., 1947, J. Exper. Psychol. 37:304-317.

38. Spoendlin, H., H.T. Schuknecht and A. Graybiel, 1964, Bureau Med. & Surg. Report No. 102, NASA No. R-93:1-23.

39. Wever, E.M. and M. Laurence, 1955, J. Acoustical Society of America, 27:853-858.

40. Wittmaach, J., 1909, Verh. dtsch. otol. Ges. 19:150-156.

A P P E N D I X

PRECEDING PAGE BLANK NOT FILMED.

G R O S S A S P E C T S

BRAIN

Figures 1-6

Tympanic Membrane

Figures 7-10

PRECEDING PAGE BLANK NOT FILMED.

Figure 1. Basal aspect of brain from animal A63-031 showing blood along the sides of the upper medulla (arrows).

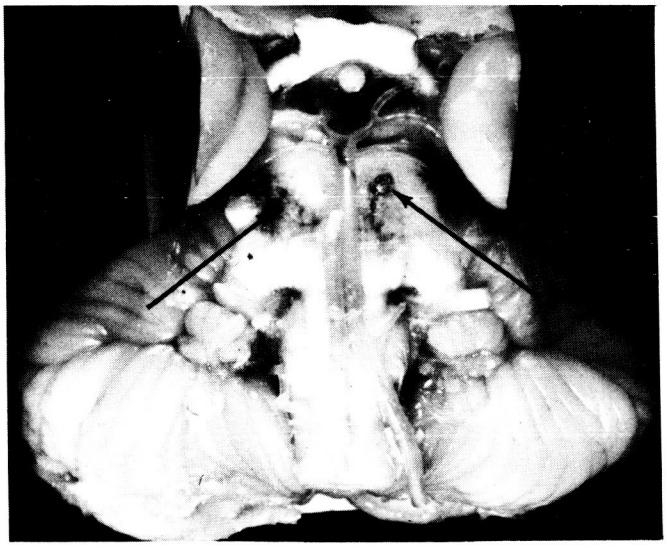

Figure 2. A similar view of brain from animal A63-036. Some discoloration is seen on the base of the pons bilaterally (arrows).

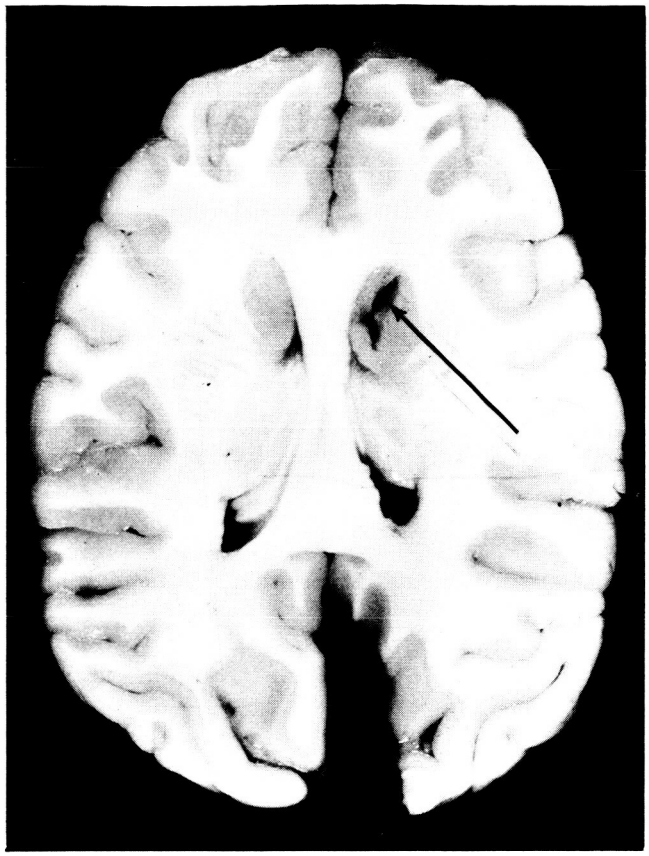

Figure 3. A coronal section of the brain from animal A63-032 showing a cavity (arrow) in the head of the right caudate nucleus.

Figure 4. The superior aspect of the brain of animal A63-033 showing congestion of the vessels in both frontal and parietal lobes.

Figure 5. A basal view of brain A63-033 showing a clot in the region of cisterna (arrow).

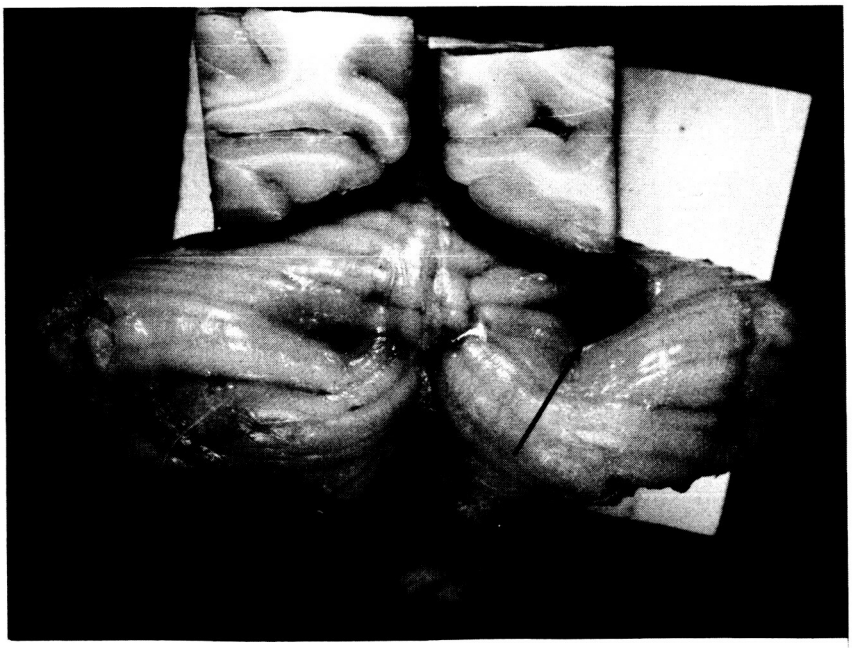

Figure 6. The superior aspect of the cerebellum of animal A63-035 showing a marked depression in the right lobe (arrow).

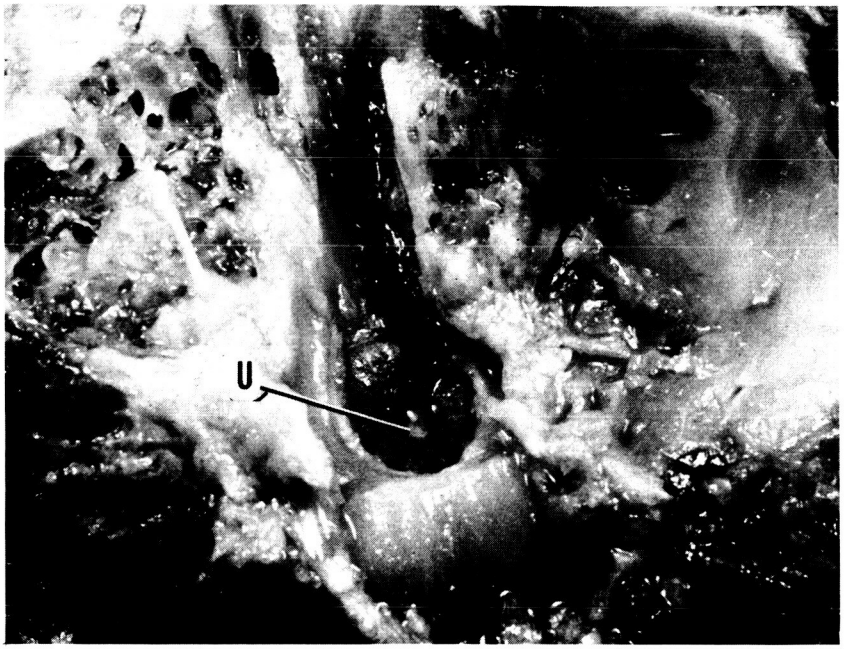

Figure 7. Intact tympanic membrane of left ear in animal A63-031 (U=umbo).



Figure 8. Tympanic membrane of left ear of animal A63-032 showing the absence of lower part of the membrane (arrow).

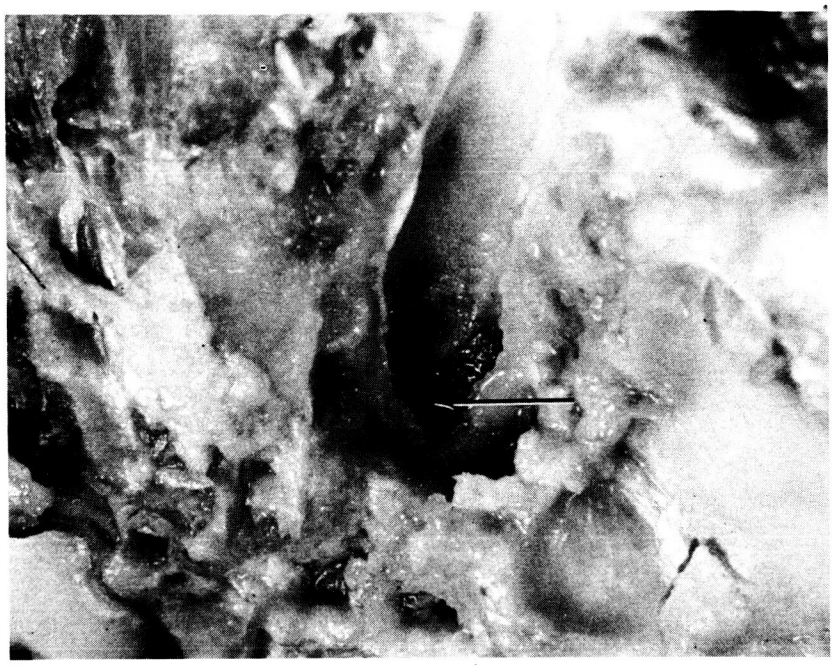

Figure 9. Right tympanic membrane of animal A63-035 showing piece torn out.

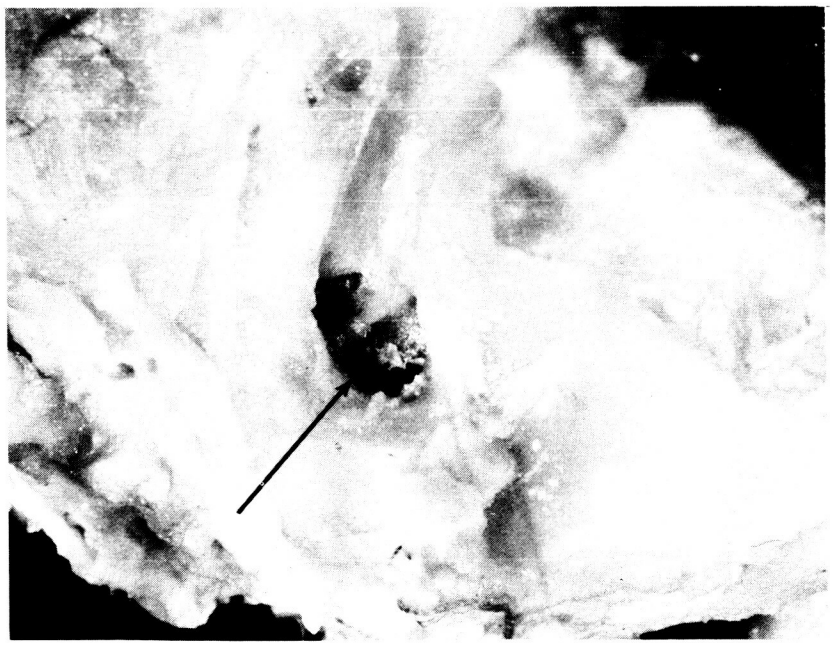

Figure 10. Tympanic membrane from right ear of animal A63-036 showing tear in the lower portion (arrow).

M I C R O S C O P I C A S P E C T S

SERIES A63-031R

Figures 11-22



Figure 11. A63-031R, sl. 26. One of the air spaces loaded with debris. The darkest pieces are bone fragments. X49

Figure 12. A63-031R, sl. 105. One of the air cells containing a dense homogeneous intensely acidophilic substance (arrow). X49

Figure 13. A63-031R, sl. 70. A portion of the wall of the carotid A. (A) lying in its bony canal (B) showing the engorgement of the venous plexus (J). X49

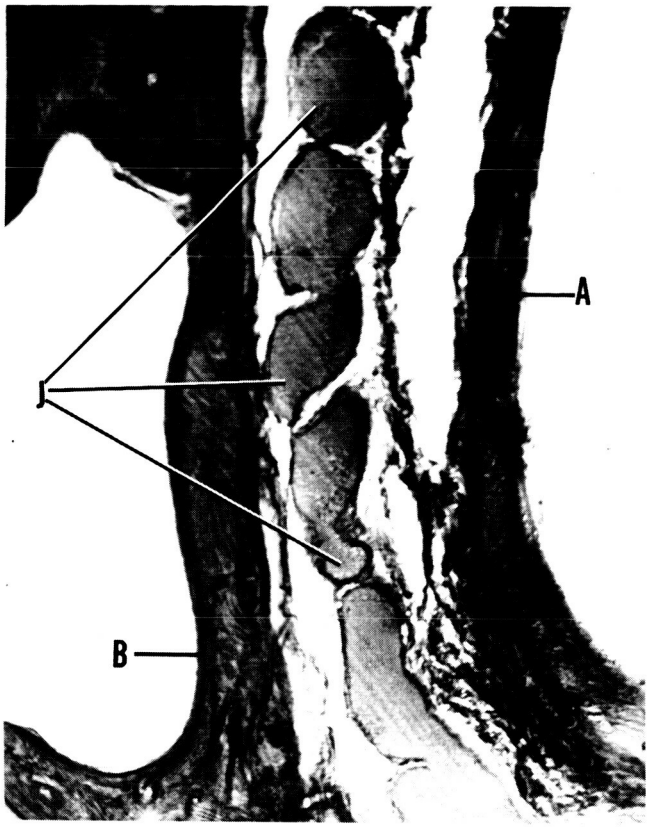

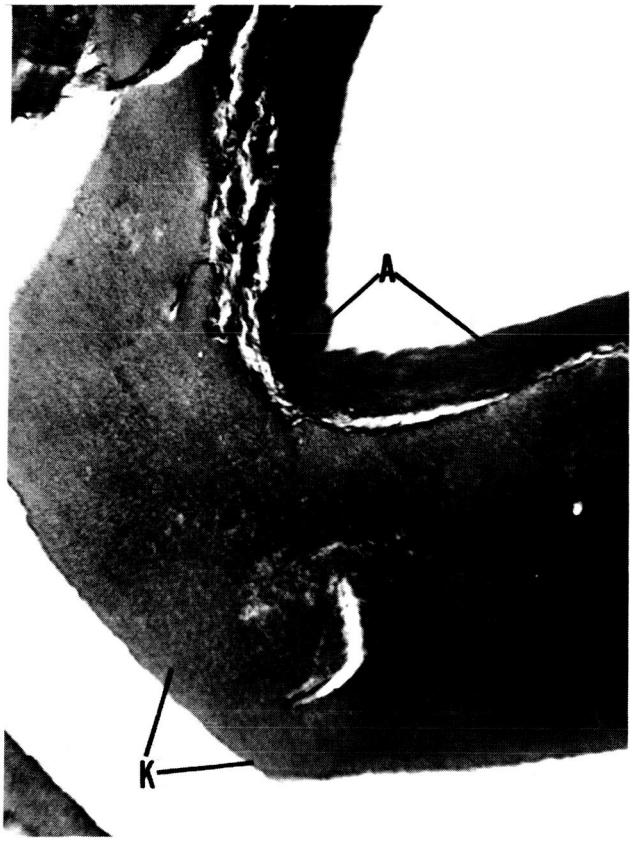

Figure 14. A63-031R, sl. 410. This section passes through the carotid canal showing a mass of blood (K) outside the vessel (A). X49

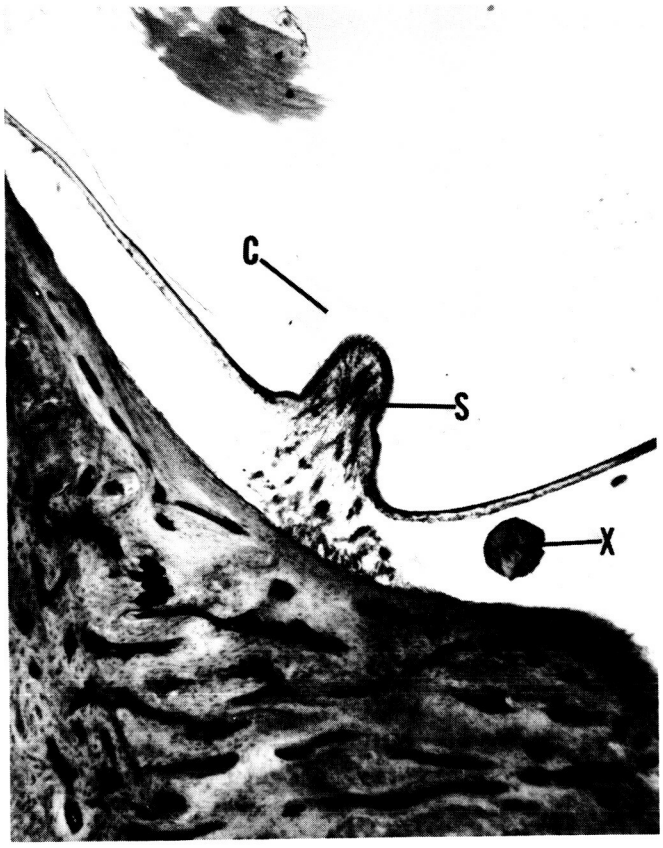

Figure 15. A63-031R, sl. 85. Crest of superior canal (S) with its fragmented cupula (C) lying at some distance above. X = resin crystal. X49

Figure 16. Same section as figure 15 at higher magnification. X140

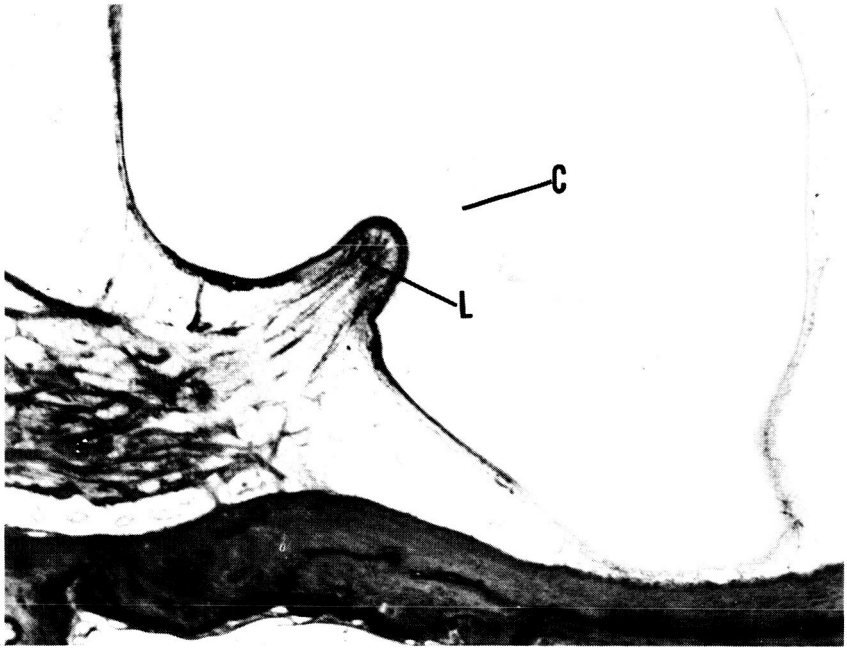

Figure 17. A63-031R, sl. 145. Crest of lateral canal (L) showing the "cloud-like" cupula (C) almost completely pulled away from the apex. X49

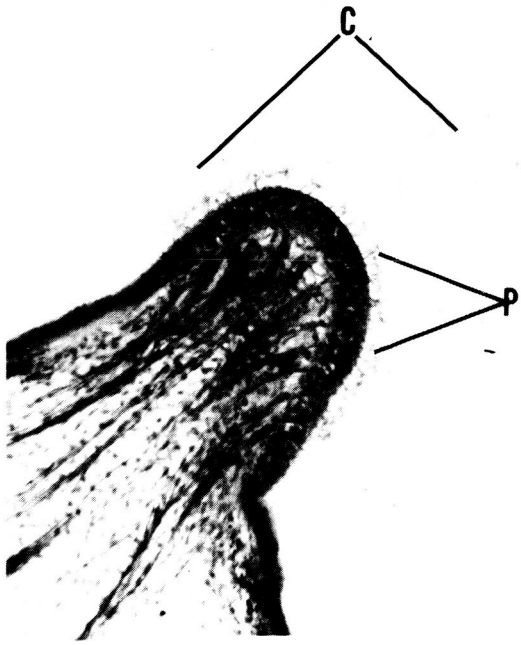

Figure 18. Same slide (145) at higher magnification showing the hair processes (P) pulled out of the cupula. X110

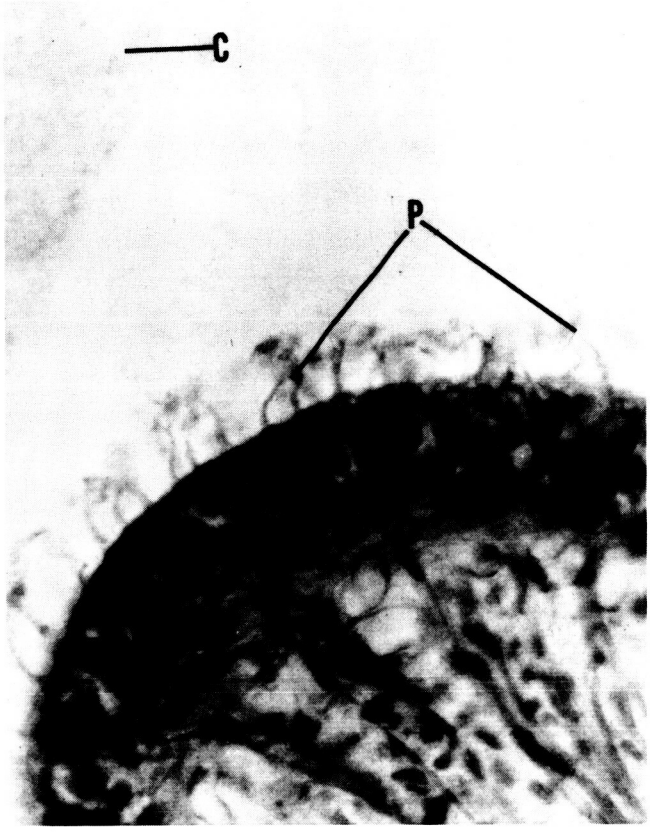

Figure 19. A63-031R, sl. 145. A still higher power photograph showing the hair cells of the same crest. X602

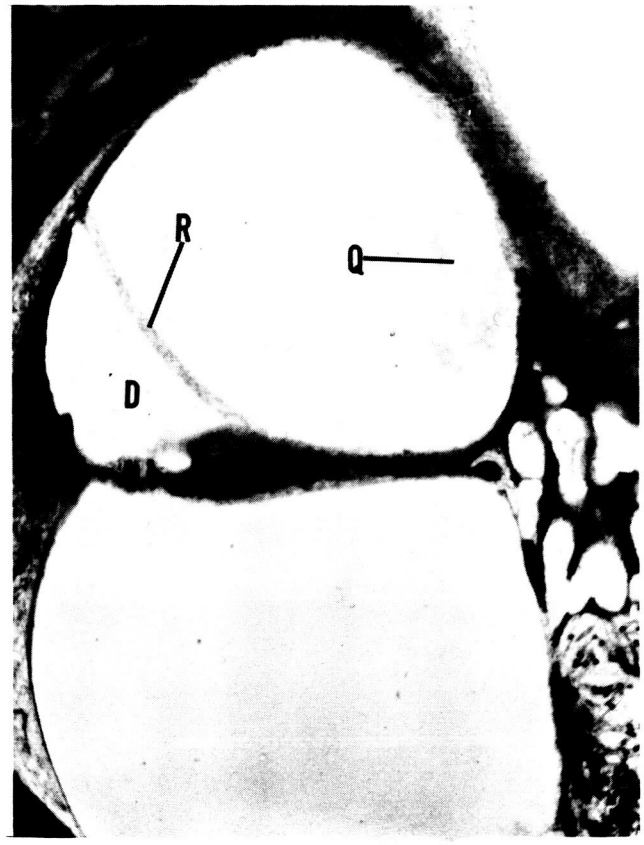

Figure 20. A63-031R, sl. 180. This section passes through one side of the basal coil of the cochlea showing a considerable amount of precipitate (Q) in the scala vestibuli. R= vestibular membrane: D= cochlear duct. X49

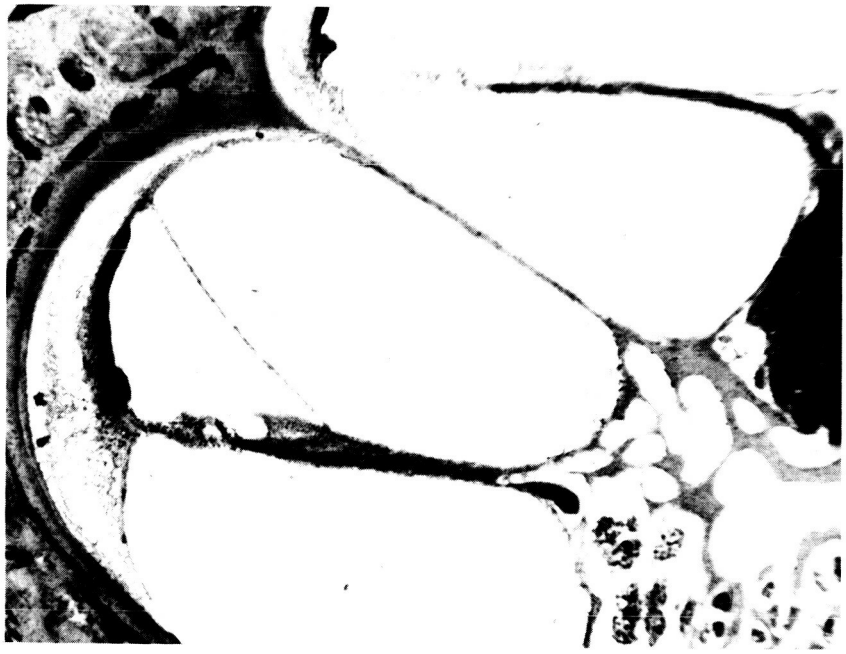

Figure 21. A63-031R, sl. 200. Section similar to the preceding showing much less precipitate. In both slides the cochlear structure in general seems normal. X49

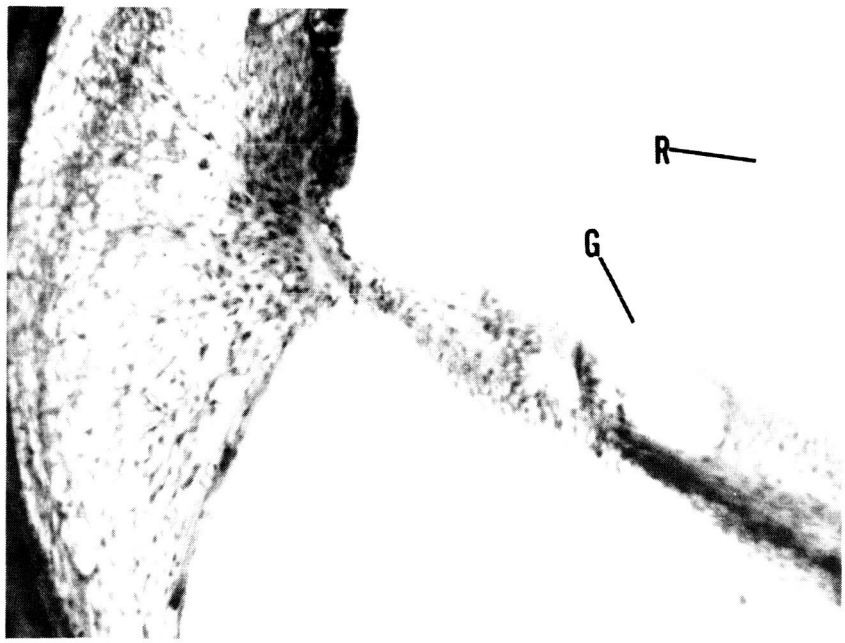

Figure 22. A63-031R, sl. 200. This section at higher power shows a normal configuration of the organ of Corti. G= tectorial membranes: R= vestibular membrane. X140

M I C R O S C O P I C A S P E C T S

SERIES A63-032R

Figures 23-30

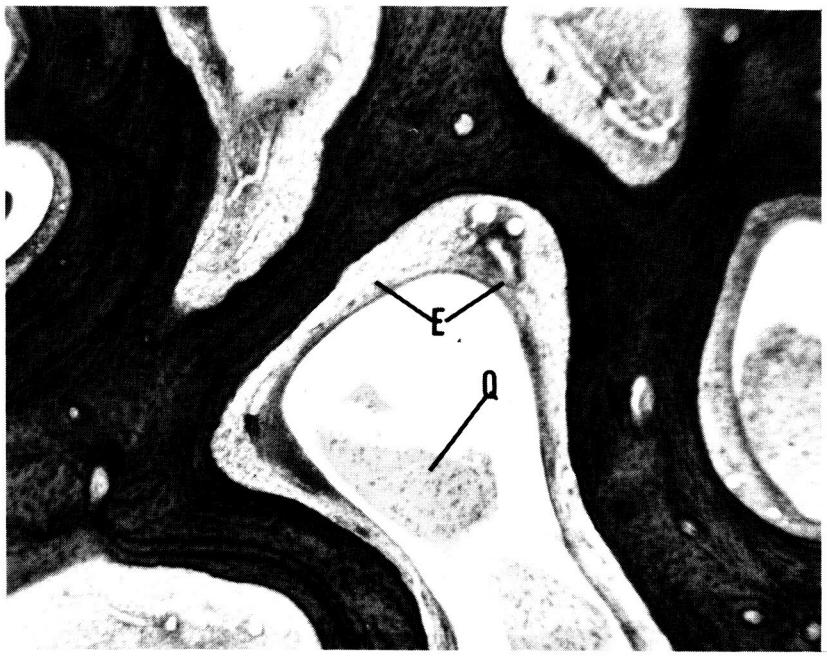

Figure 23. A63-032R, sl. 200. A section through some of the air cells showing greatly thickened linings (E) with a cell-rich faintly acidophilic substance (Q) contained therein. X49

Figure 24. A63-032R, sl. 150. Section of the posterior canal near its origin from the common crus. One side is flattened (arrow). The rippled effect in the celloidin indicates the direction of the knife, thus indicating that the flattening was not a technical artefact. X49

Figure 25. A63-032R, sl. 165. Section of the posterior canal showing marked distortion. X49

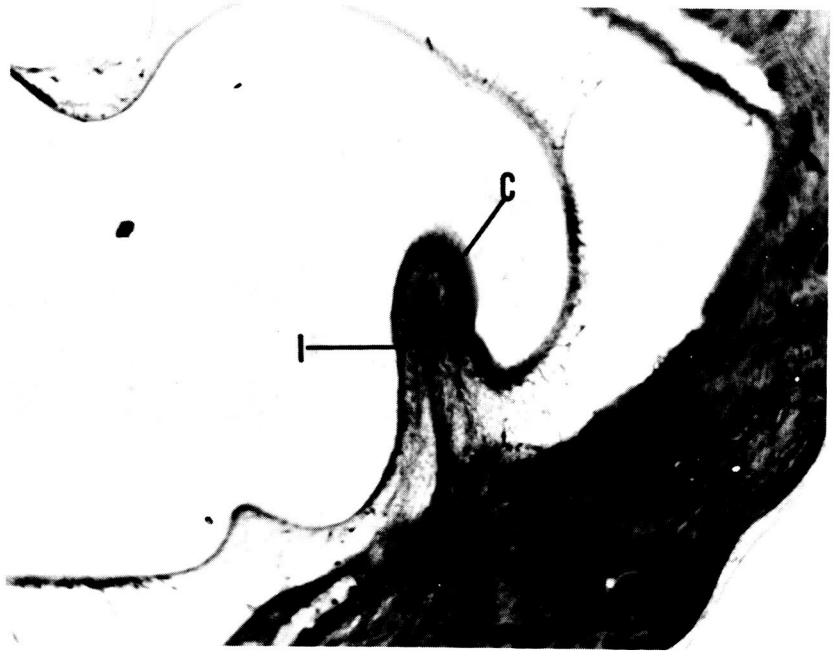

Figure 26. A63-032R, sl. 170. Section near the apex of the crest (I) of the posterior canal with its cupula (C) shifted to one side. X49

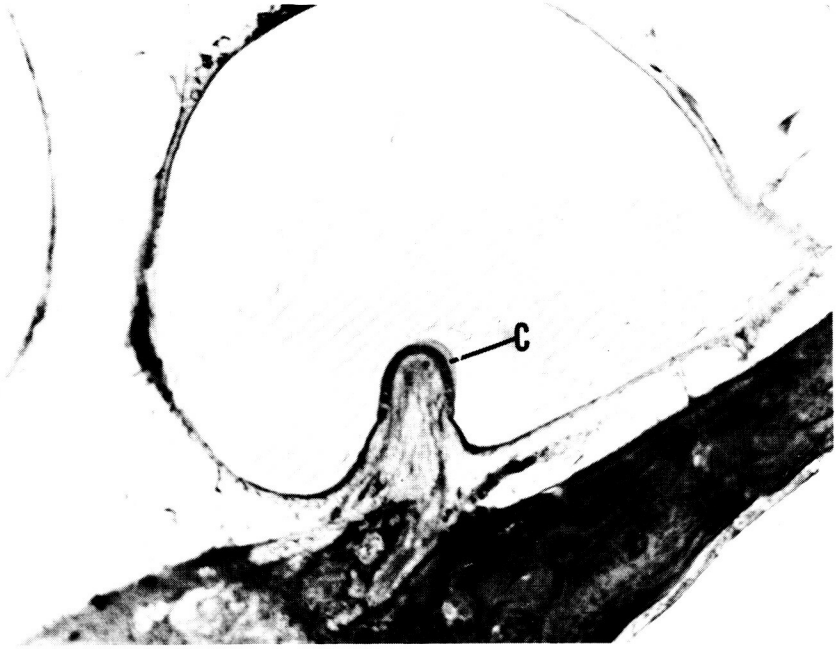

Figure 27. A63-032R, sl. 185. Section below the apex of the crest shown in the preceding, showing the shift in the cupula (C). X49

Figure 28. A63-032R, sl. 190. Section showing the partial collapse of the wall (W) of the saccule against its macula (M) at arrow. X49



Figure 29. A63-032R, sl. 190. A section showing the region of contact between saccular wall and macula at higher magnification. X140

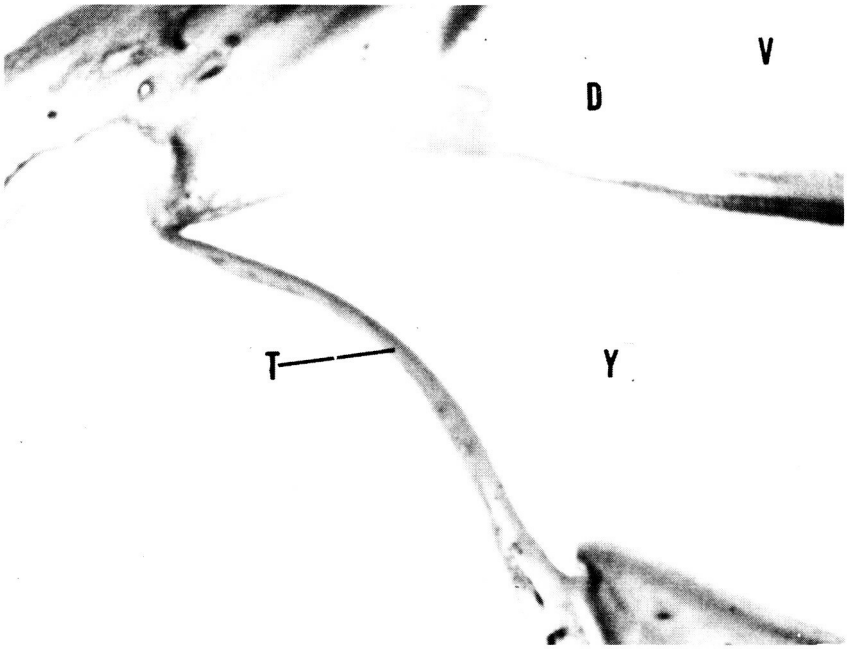

Figure 30. A63-032R, sl. 300. This section is through the intact secondary tympanic membrane (T) showing the middle ear (F) scala tympanic (Y), cochlear duct (D) and scala vestibuli (V). X49

M I C R O S C O P I C A S P E C T S

SERIES A63-032L

Figures 31-42

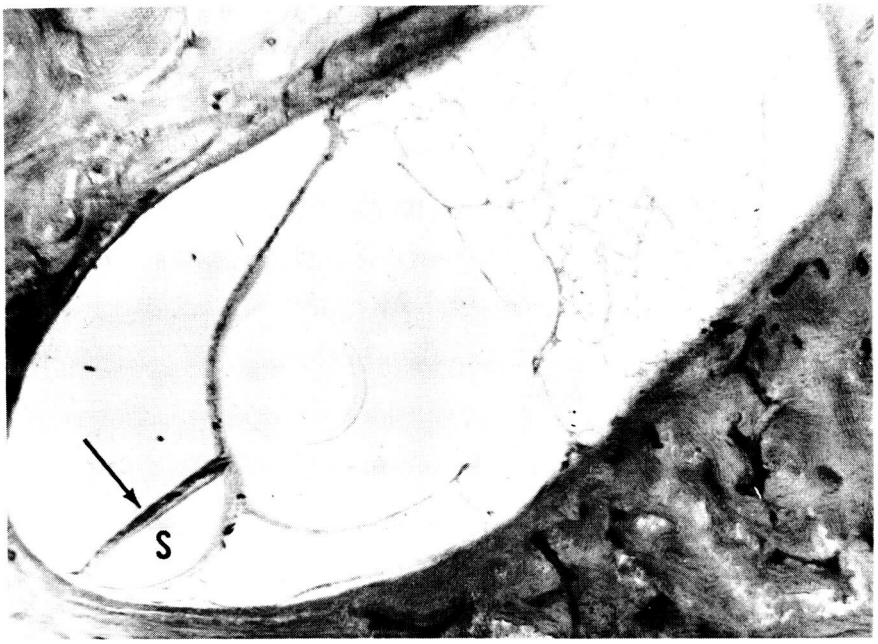

Figure 31. A63-032L, sl. 95. Section showing the superior canal (S) flattened on one side (arrow). The plane of sectioning was oblique to this flat zone and thus it was not the result of cutting. X49

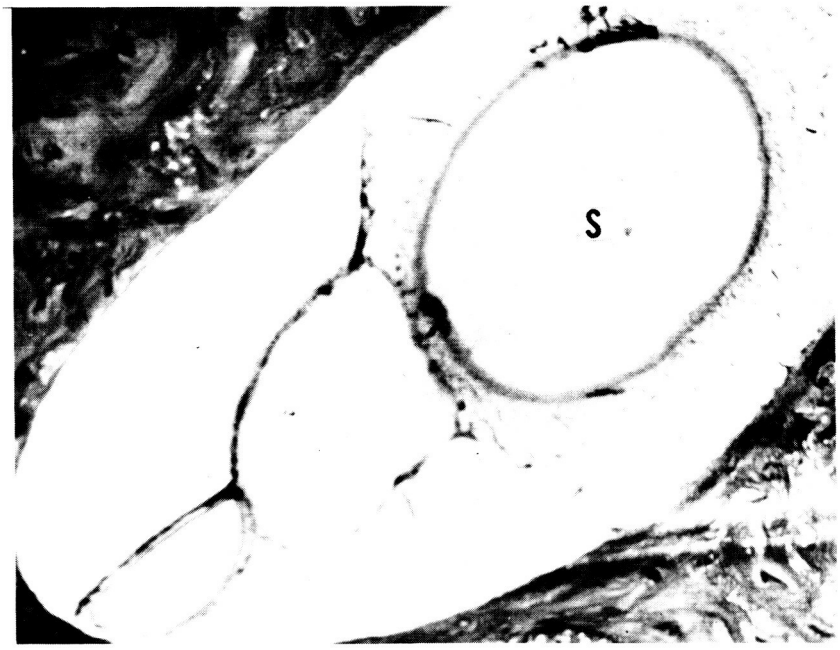

Figure 32. A63-032L, sl. 106. A section farther down near its ampulla (S) showing that one side is still flat. X49

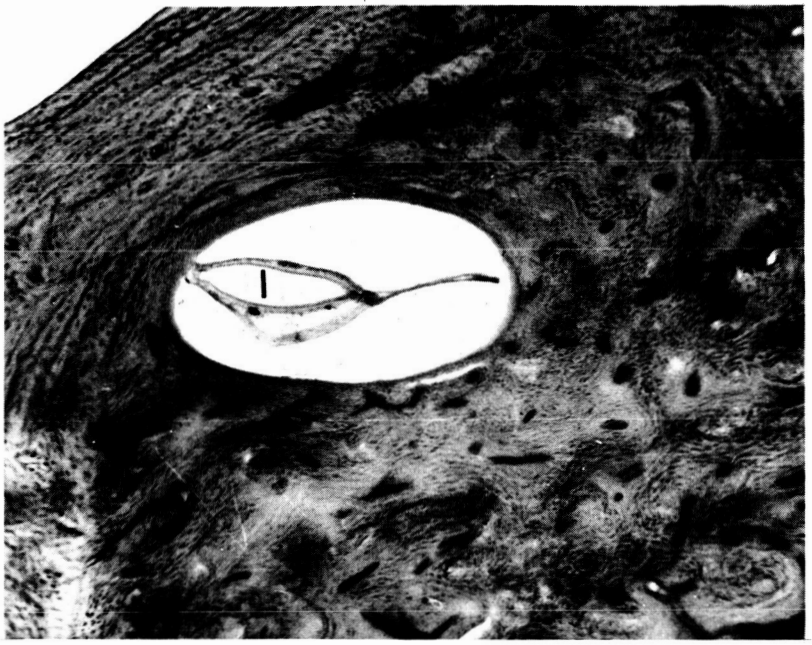

Figure 33. A63-032L, sl. 111. Section through the posterior canal (I) showing that it has been compressed. X49

Figure 34. A63-032L, sl. 124. Section of the crest of the superior canal (S) with the cupula (C) distorted and pulled away. X49

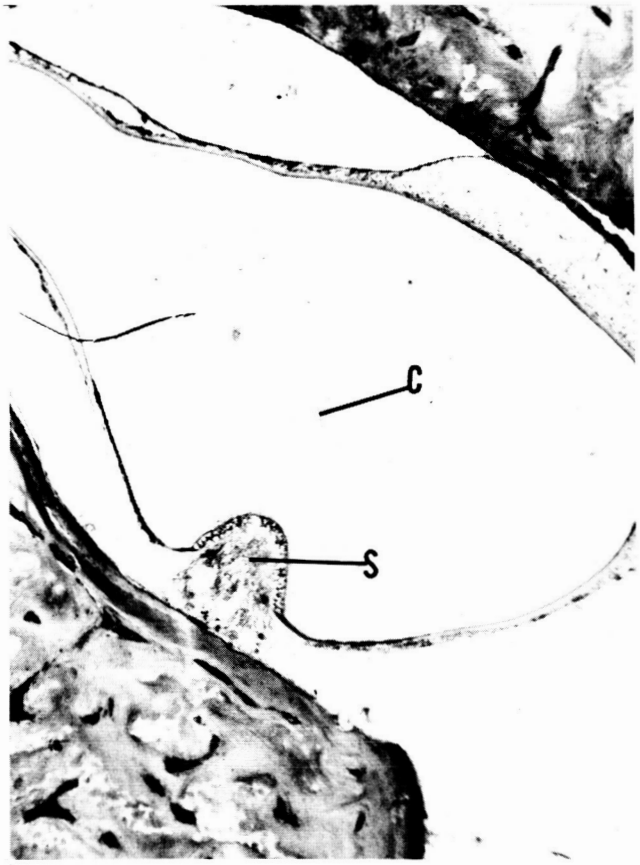

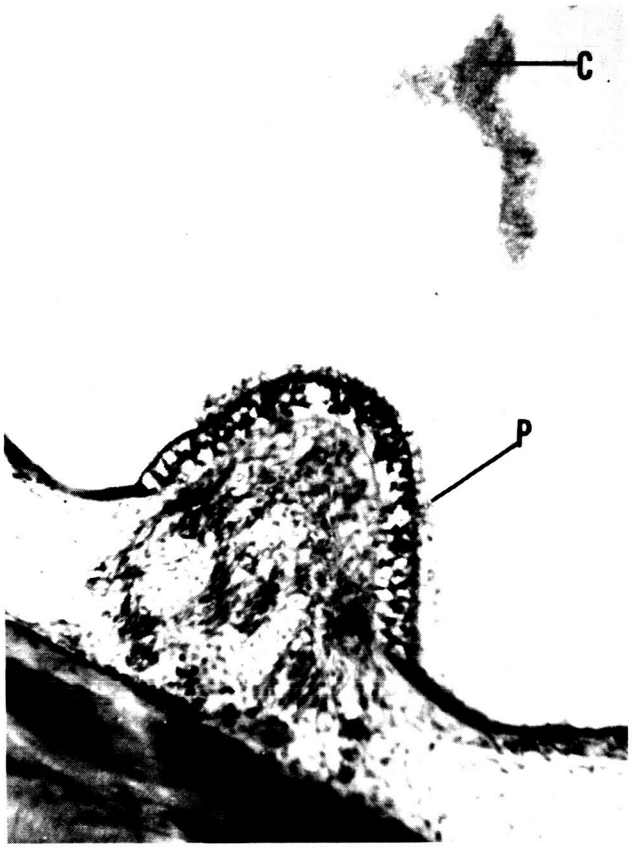

Figure 35. A63-032L, sl. 124. An intermediate power photomicrograph of the same crest shown in the preceding figure, showing the naked hair processes (P) with the cupula (C) pulled away. X140

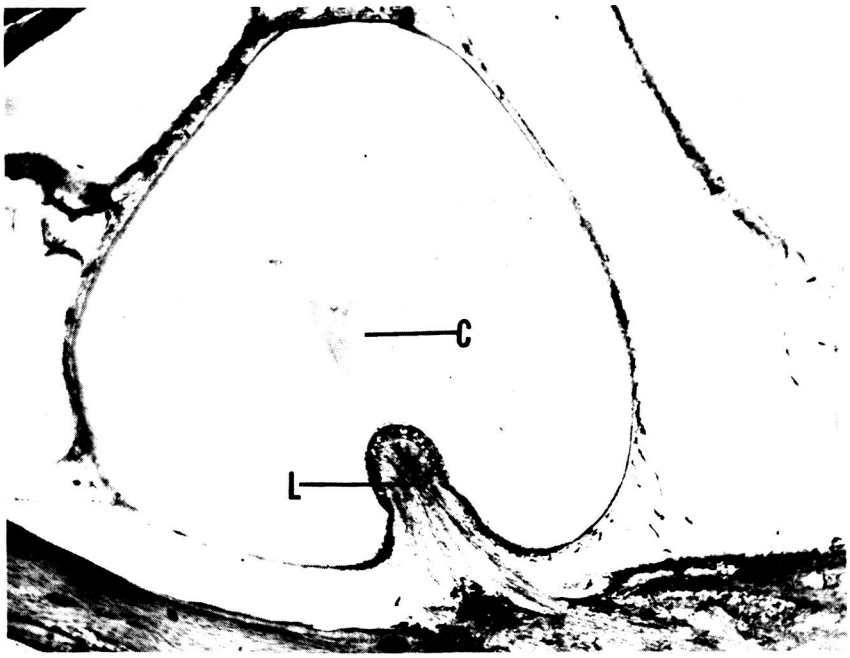

Figure 36. A63-032L, sl. 185. Section through the crest (L) of the lateral canal showing the "cloud-like" cupula (C). X49

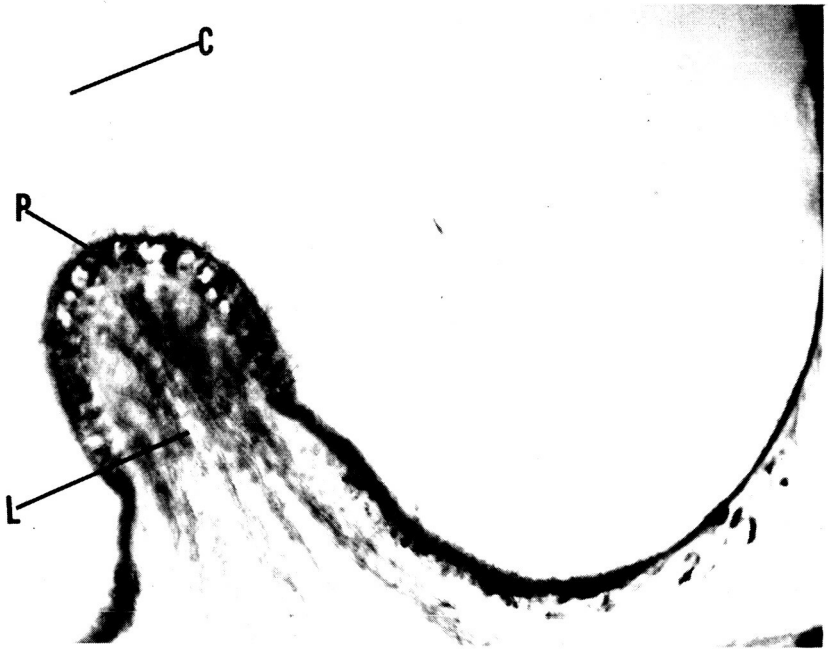

Figure 37. A63-032L, sl. 185. Same section as in figure 36, under higher magnification. C= cupula; P= hair cell processes; L= crest. X140

Figure 38. A63-032L, sl. 160. Section through the macula (M) utriculi with the otolithic membrane (0) intact. X49

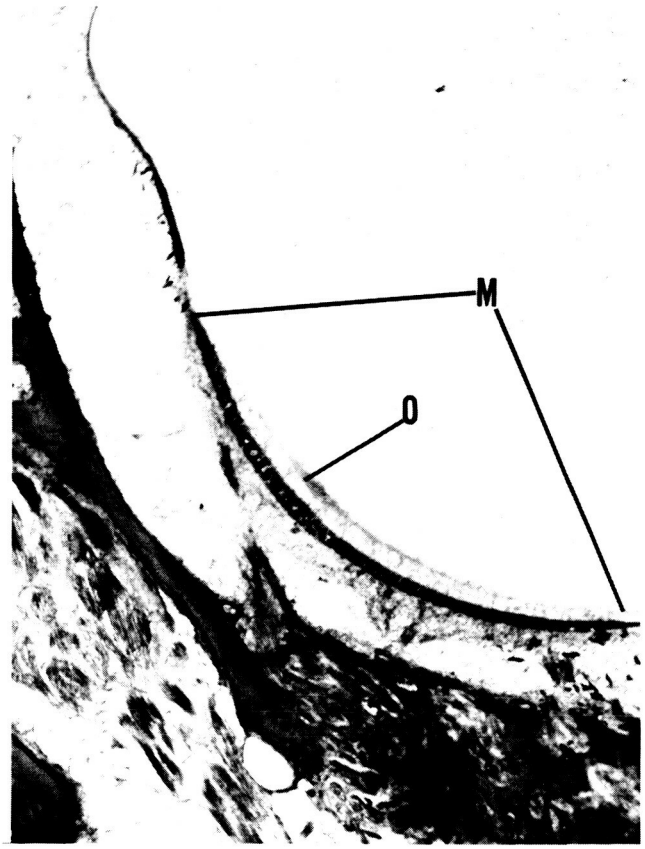

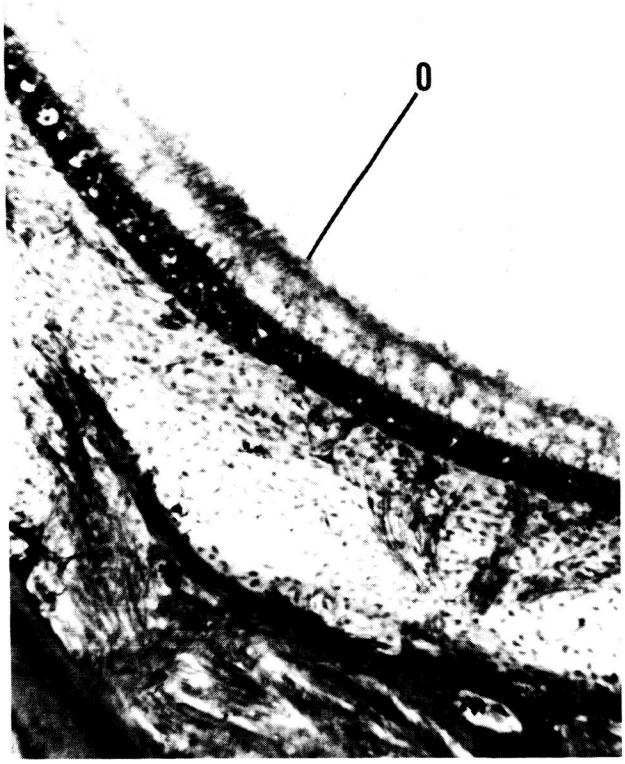

Figure 39. A63-032L, sl. 160. Section through the same macula as in figure 38 using higher magnification. O= otolithic membrane. X140

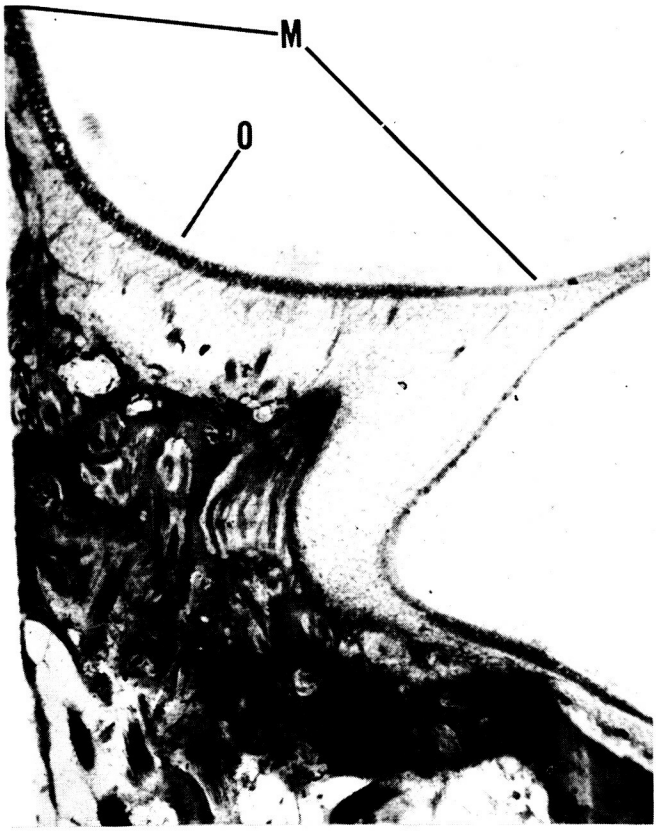

Figure 40. A63-032L, sl. 171. Section through the macula (M) utriculi with the otolithic (o) membrane intact but slightly elevated. X49



Figure 41. A63-032L, sl. 275. Section through a normal coil of the cochlea. Some material may be seen (arrow) in the scala tympani (Y). D= cochlear duct; V= scala vestibuli. X49

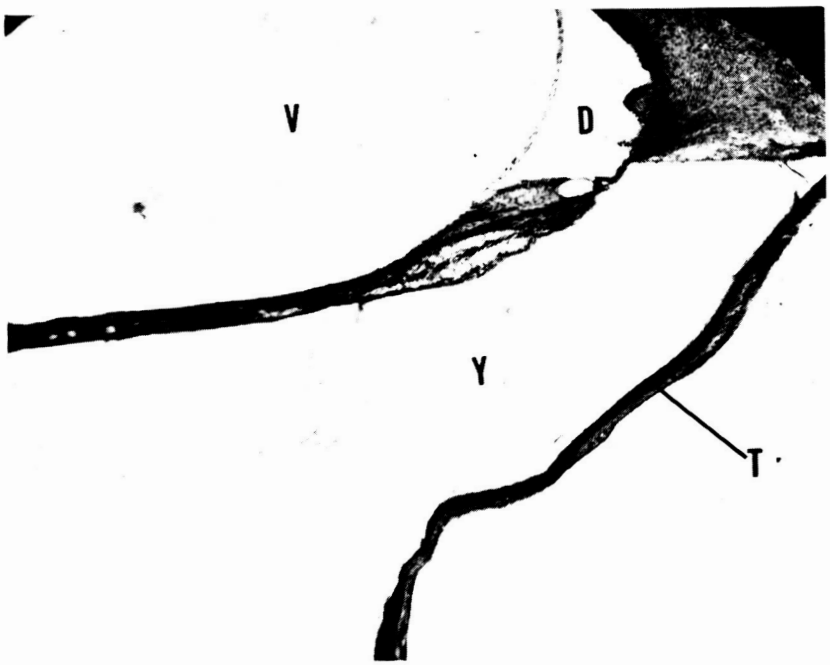

Figure 42. A63-032L, sl. 275. Section showing an intact secondary tympanic membrane (T) in the round window. Y= scala tympani; V= scala vestibuli; D= cochlear duct. X49

M I C R O S C O P I C A S P E C T S

SERIES A63-033R

Figures 43-49

Figure 43. A63-033R, sl. 35. Section showing a large air space filled with a light acidophilic granular substance with a large group of mononuclear cells (arrow). Blood vessels (A) are seen at the edge of one of the spaces. X49

Figure 44. A63-033R, sl. 420. Section through one large, irregular air space showing this granular, lightly acidophilic substance with groups of mononuclear cells (at arrow). X49

Figure 45. A63-033R, sl. 420. Section through one of the cell groups seen in the preceding section, but at a higher magnification. X140

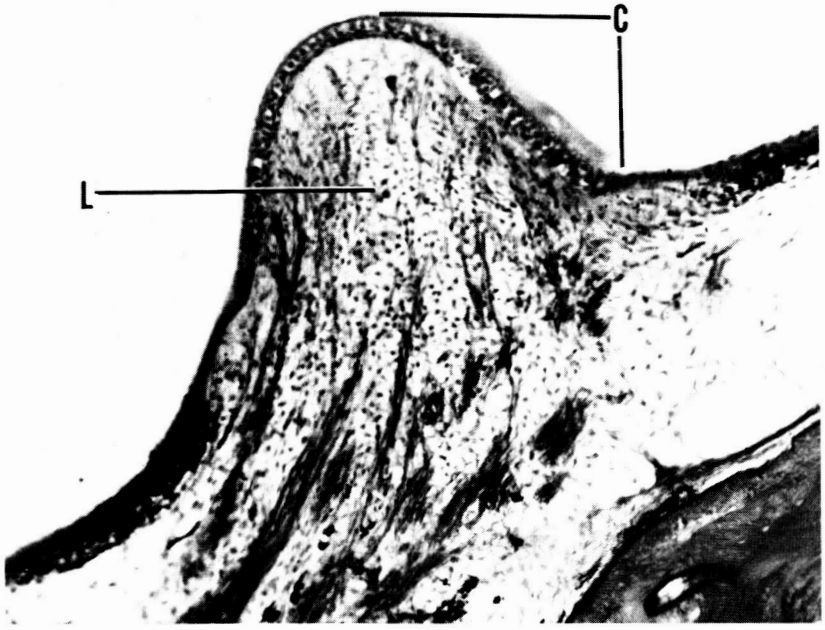

Figure 46. A63-033R, sl. 216. Crest of the lateral canal (L) showing an atypical cupula (C). X140

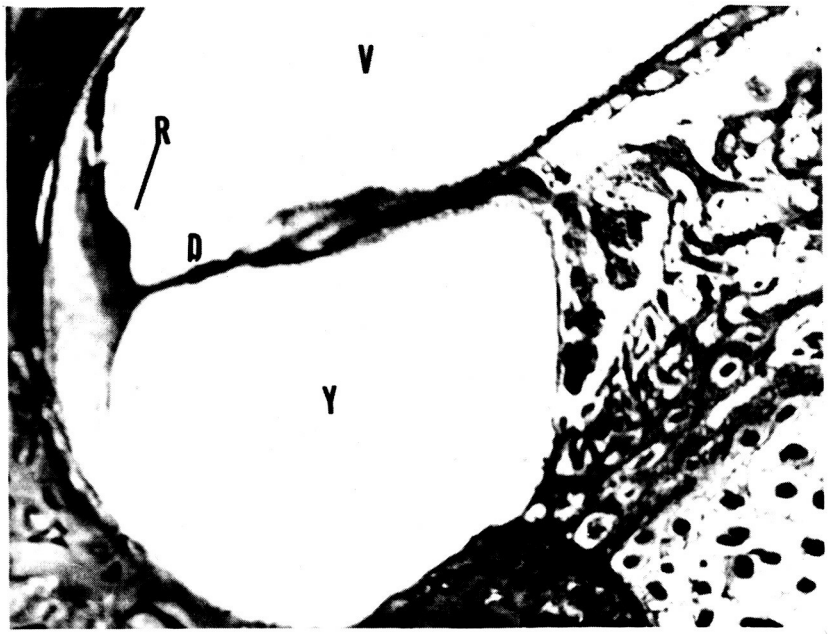

Figure 47. A63-033R, sl. 235. Section through one side of one coil of the cochlea showing a very irregular vestibular membrane (R). D= cochlear duct; V= scala vestibuli; Y= scala tympani. X49

Figure 48. A63-033R, sl. 251. This is the same coil of the cochlea with the vestibular membrane compressed against the organ of Corti which has completely collapsed. X49



Figure 49. A63-033R, sl. 350. Section through the round window showing an intact secondary tympanic membrane (T). X= resin granule. X49

M I C R O S C O P I C A S P E C T S

SERIES A63-033L

Figures 50-65

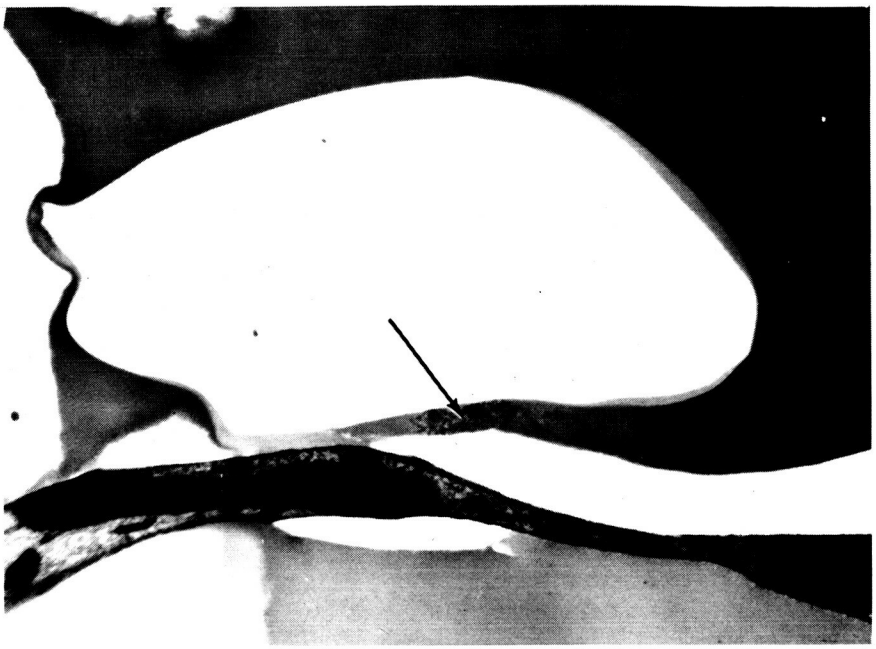

Figure 50. A63-033L, sl. 2. Section through one large air space and a part of another. This material is homogeneous and deeply acidophilic. It is darker in one space than in the other. A few cells are scattered in one area (arrow). X49

Figure 51. A63-033L, sl. 365. Section through two and parts of two other spaces. They are full of deeply acidophilic granular material. X49

Figure 52. A63-033L, sl. 15. This section shows the posterior canal (I) greatly indented on one side (at arrow). X49

Figure 53. A63-033L, sl. 20. This section lies about 100 microns below the preceding showing the indentation and a mass of cells in the lumen. X49

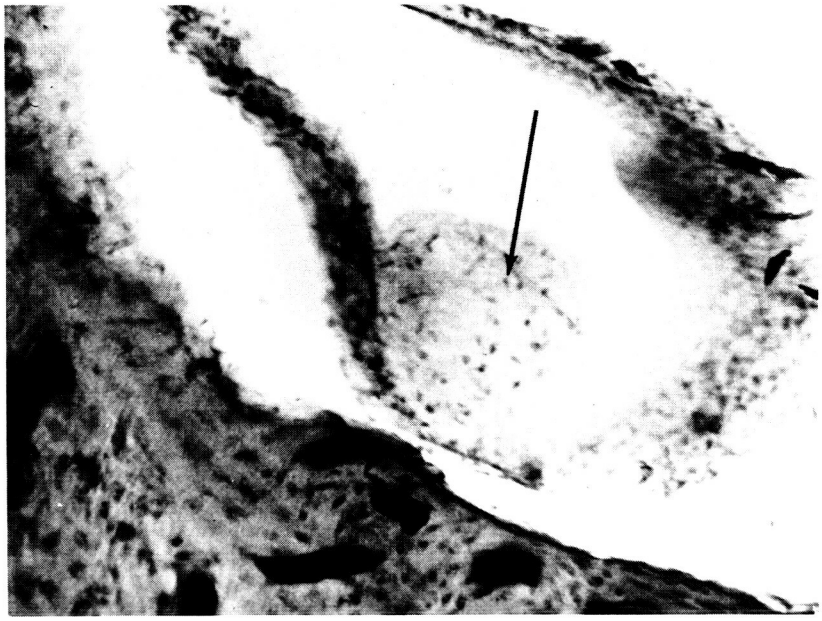

Figure 54. A63-033L, sl. 20. A higher power photomicrograph of the same area as the posterior canal shown in figure 53. The abnormal cell mass is at the arrow. X140

Figure 55. A63-033L, sl. 84. A section of the posterior canal (I) showing the great compression. X49

Figure 56. A63-033L, sl. 74. This shows the common crus flattened on one side (arrow). An unusual amount of granular precipitate is seen within its lumen (arrow). X49

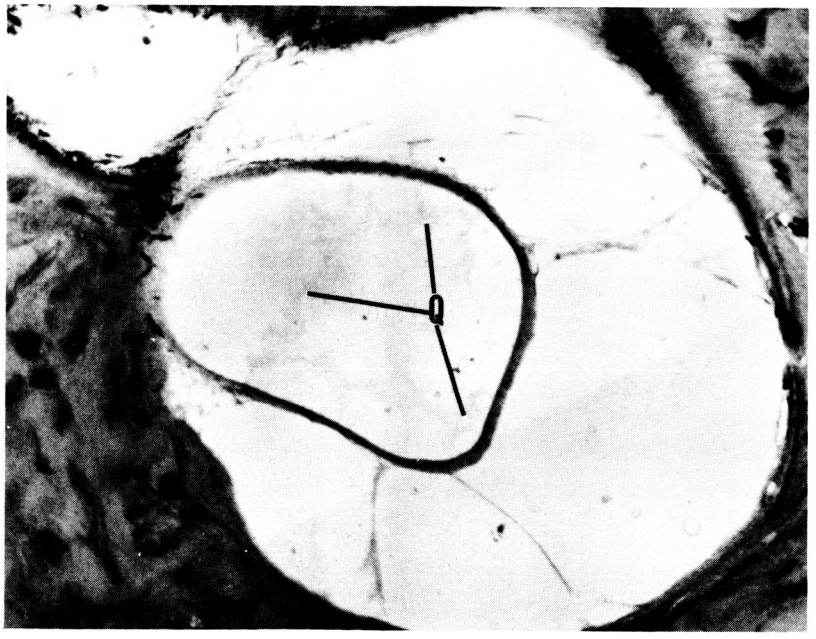

Figure 57. A63-033L, sl. 95. This section is farther caudal along the common crus than the one shown in figure 56. It contains an unusually large amount of precipitated material (Q) and one side is still flat. X49

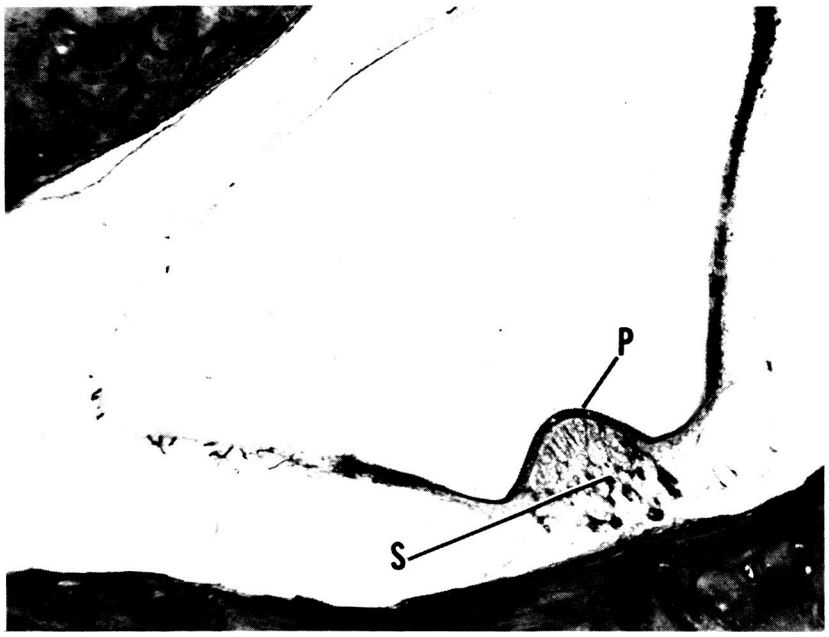

Figure 58. A63-033L, sl. 125. This section passes through the crest of the superior canal (S). Although hair cells can be seen (P) no cupula is visible. X49

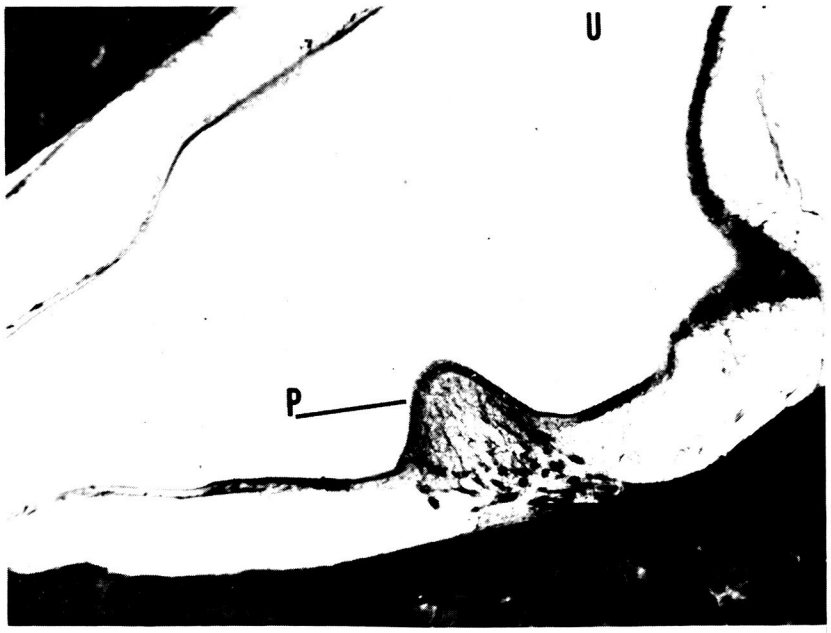

Figure 59. A63-033L, sl. 135. Another section showing the ampulla of the superior canal as it opens into the utricle (U). Again hair cells (P) but no cupula may be seen. X49



Figure 60. A63-033L, sl. 135. The same crest shown in figure 59, at higher magnification. X140

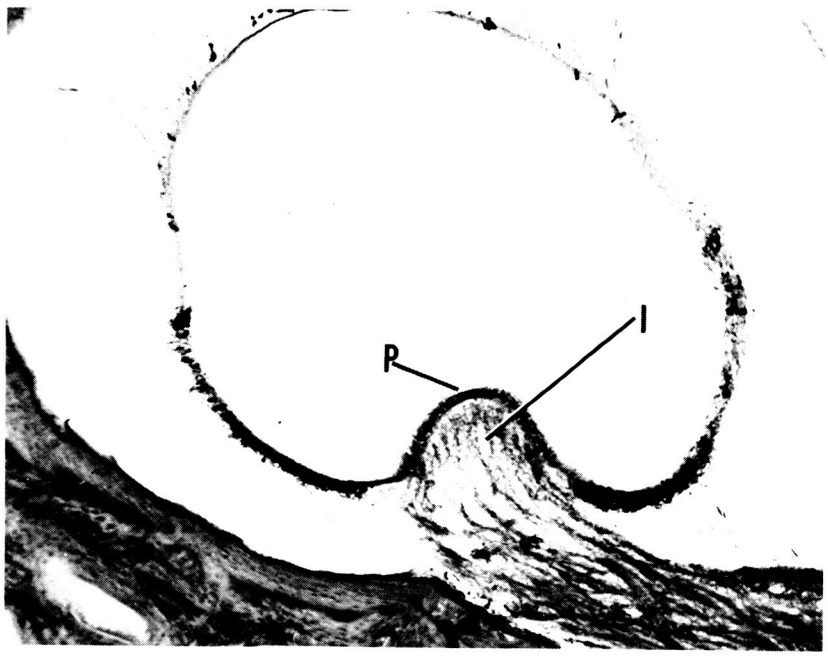

Figure 61. A63-033L, sl. 183. This is the crest of the posterior canal (I) showing sparse hair processes (P) but no cupula. X49

Figure 62. A63-033L, sl. 183. This section shows the almost complete collapse of the saccule. X49

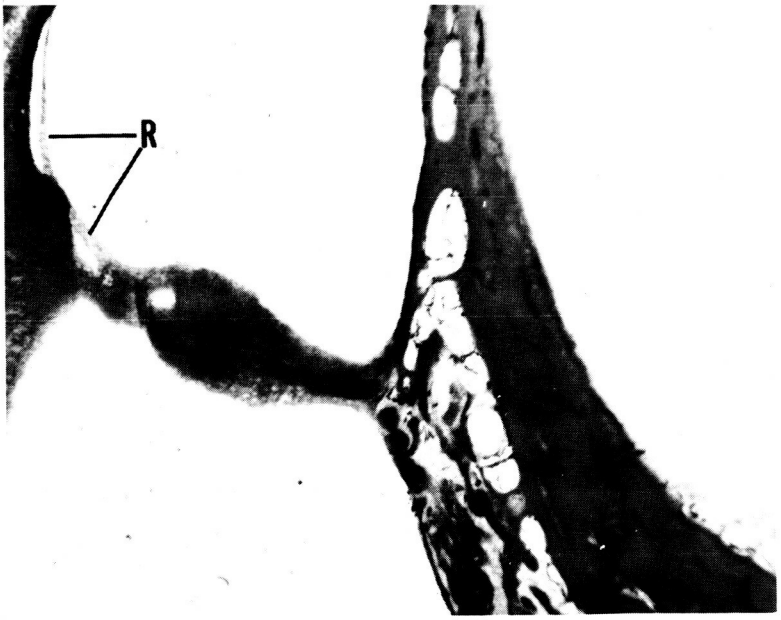

Figure 63. A63-033L, sl. 200. This section is through the left side of the middle coil of the cochlea showing the collapse of the vestibular membrane (R) obliterating most of the lumen of the duct and the organ of Corti. X49

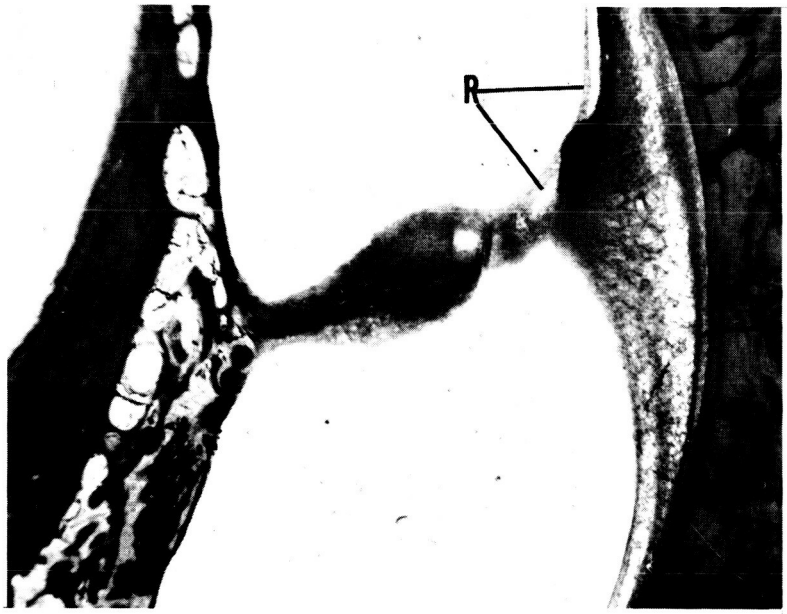

Figure 64. A63-033L, sl. 200. This is a section of the right side of the same coil shown in figure 63 with the same extreme depression of the vestibular membrane (R). X49

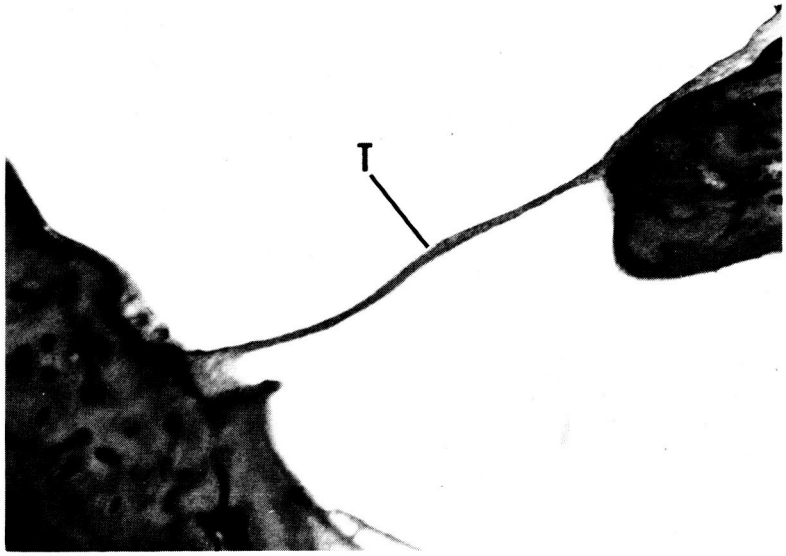

Figure 65. A63-033L, sl. 295. Section through the round window showing the intact secondary tympanic membrane (T). X49

M I C R O S C O P I C A S P E C T S

SERIES A63-035R

Figures 66-73

Figure 66. A63-035R, sl. 350. Section through the crest of the superior canal showing an elevated cupula (C). X140

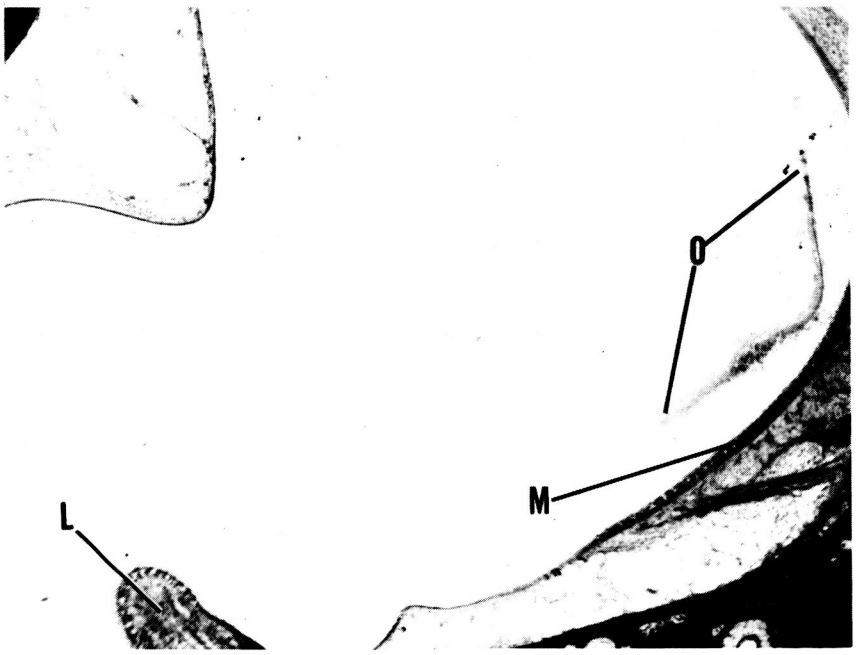

Figure 67. A63-035R, sl. 410. Section through the ampulla of the lateral canal as it opens into the utricle. The crest (L) without cupula is shown together with the otolithic membrane (O) which has lifted off the macula (M). X49

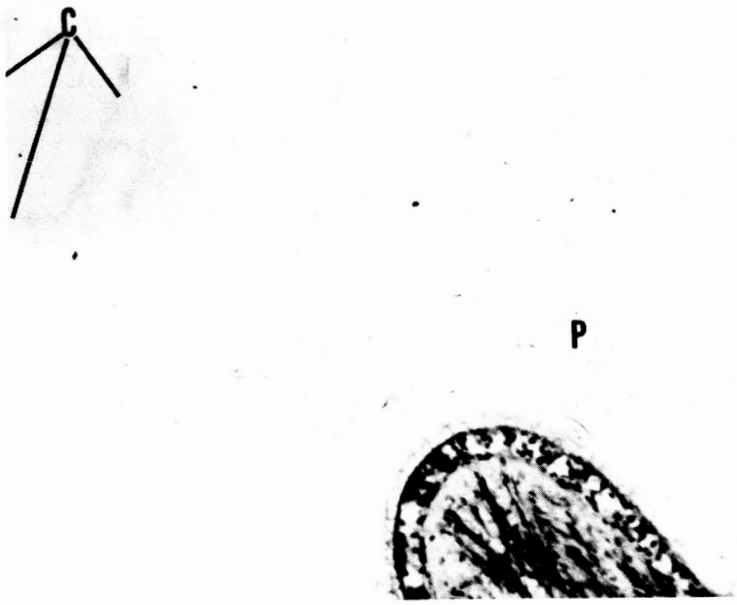

Figure 68. A63-035R, sl. 425. Section near the apex of the crest of the lateral canal showing the cupula (C) greatly elevated. Hair processes (P) are visible. X140

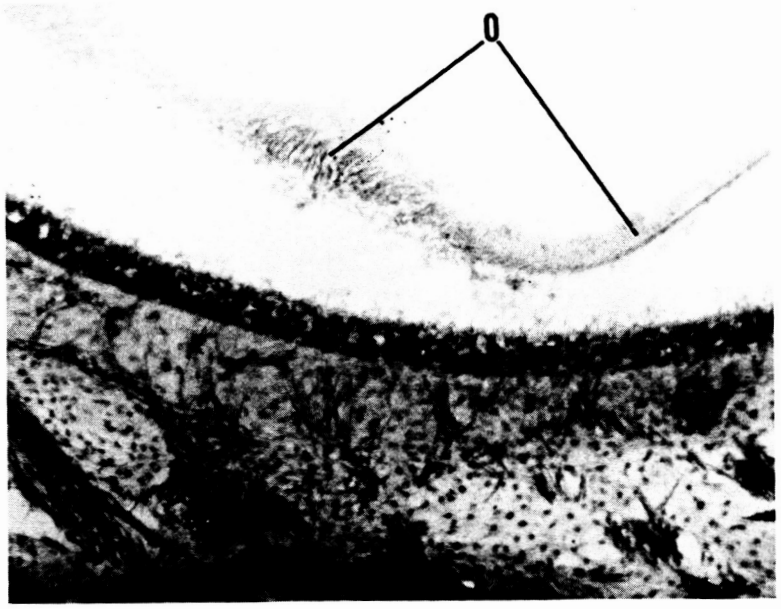

Figure 69. A63-035R, sl. 410. Section through the macular region shown in figure 67 at higher magnification. O= otolithic membrane. X140

Figure 70. A63-035R, sl. 370. Section of the upper coil of the cochlea showing the compression of the vestibular membrane (R). X49

Figure 71. A63-035R, sl. 430. Section through the cochlea showing accumulation of material (arrow) in cochlear duct. X140

Figure 72. A63-035R, sl. 470. A section through the side of one coil of the cochlea not only showing the compression of the vestibular membrane but also a large amount of acidophilic substance (arrow). X49

Figure 73. A63-035R, sl. 575. Section through an intact secondary tympanic membrane (T). X49

M I C R O S C O P I C A S P E C T S

SERIES A63-035L

Figures 74-81

Figure 74. A63-035L, sl. 120. Section through an air space showing a deeply acidophilic substance with a scattering of cells. The compressed superior canal (S) is also seen. X49

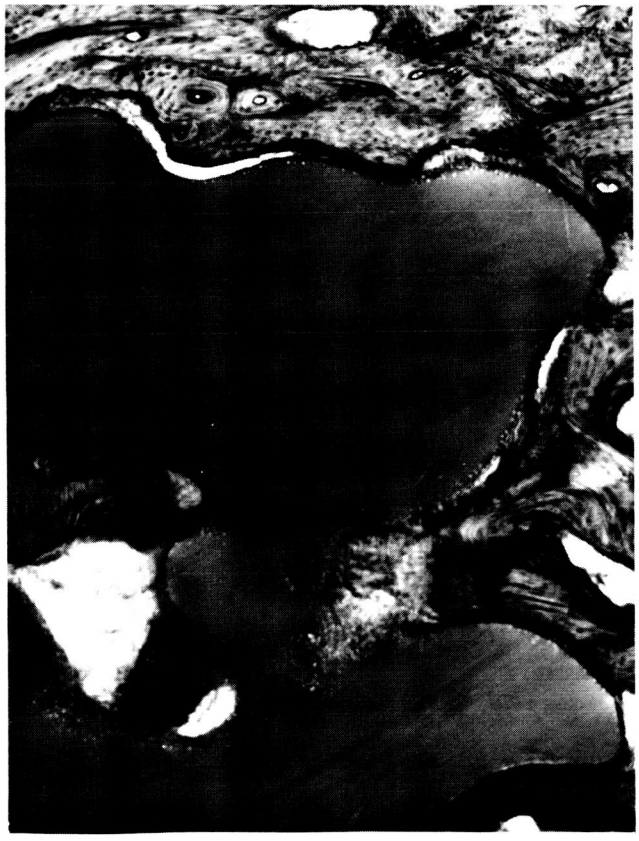

Figure 75. A63-035L, sl. 400. Section showing parts of two interconnecting air spaces completely filled with a very dense, homogenous, heavily acidophilic substance. X49

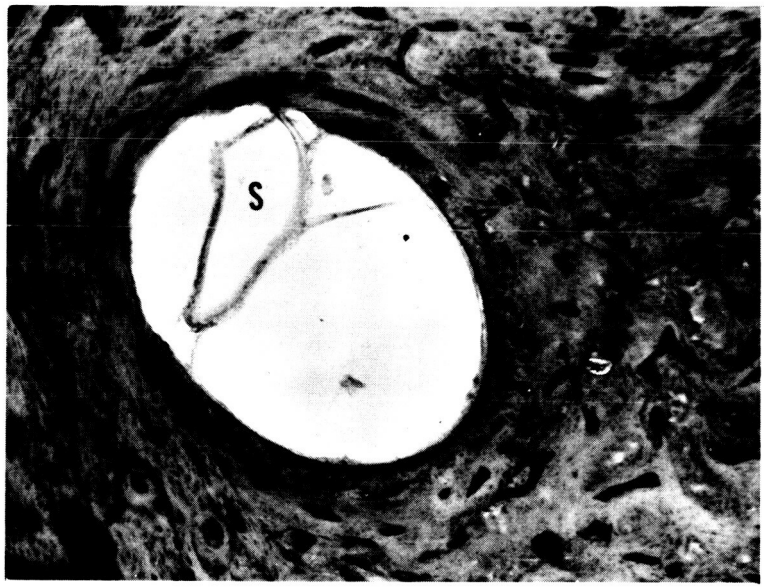

Figure 76. A63-035L, sl. 35. Section showing compression of the medial end of the superior canal (S). X49

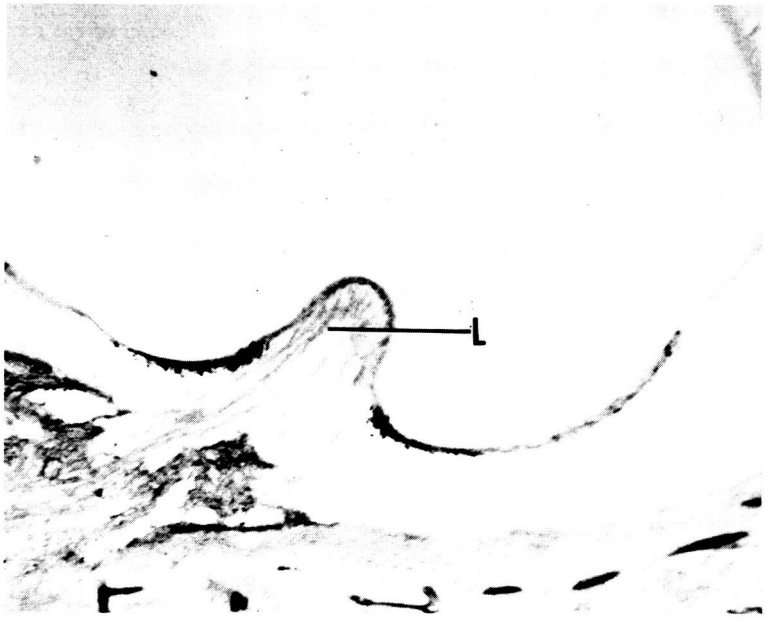

Figure 77. A63-035L, sl. 190. Section of the crest of the lateral canal (L) showing absence of a cupula and hair cells. X49

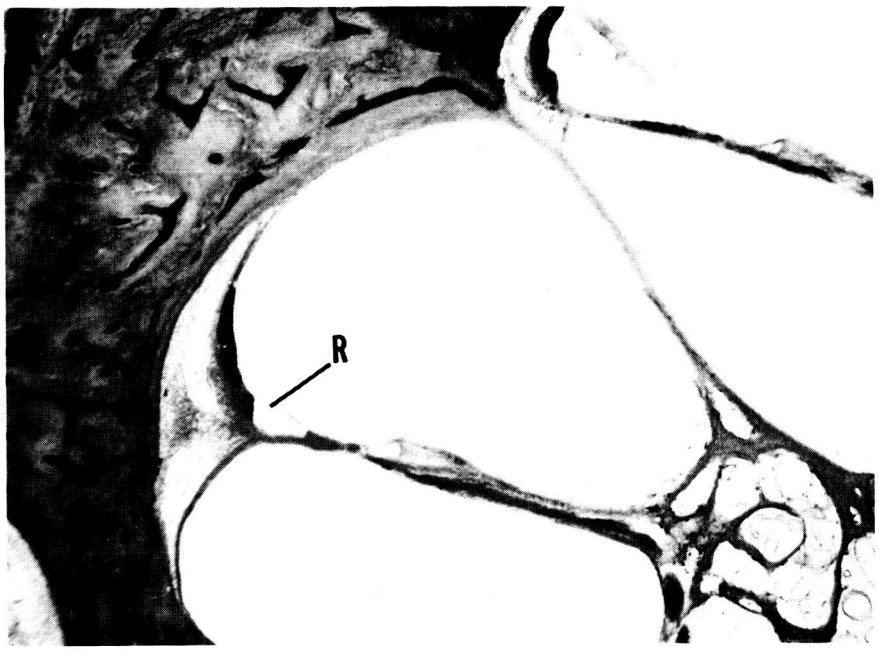

Figure 78. A63-035L, sl. 155. A section through the cochlea showing the great depression of the vestibular membrane (R). X49

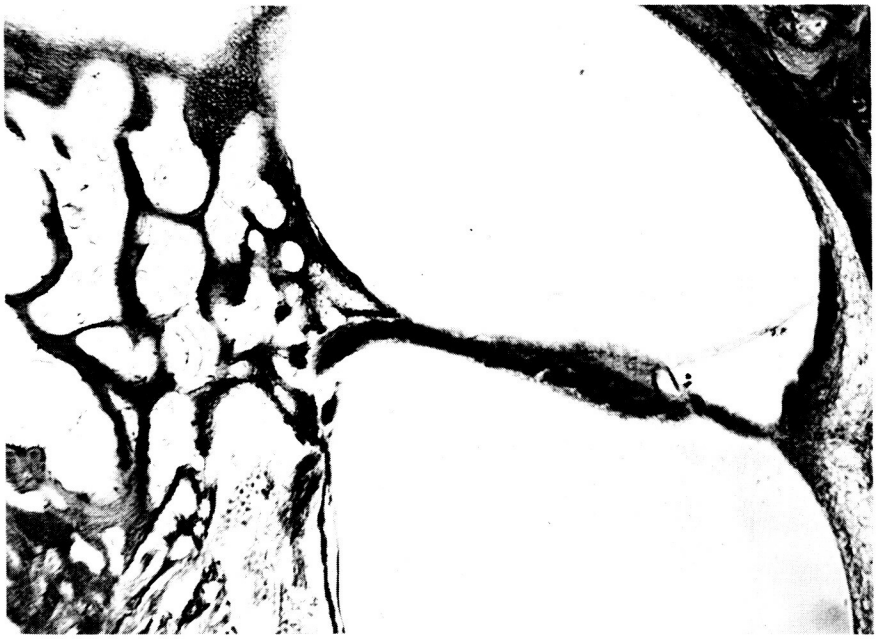

Figure 79. A63-035L, sl. 155. This section shows the other side of the same coil shown in figure 78. X49

Figure 80. A63-035L, sl. 195. A section showing parts of two coils of the cochlea. In the lower portion, the cochlear duct (D) is almost obliterated, in the upper, the vestibular membrane (R) is less markedly depressed. X49

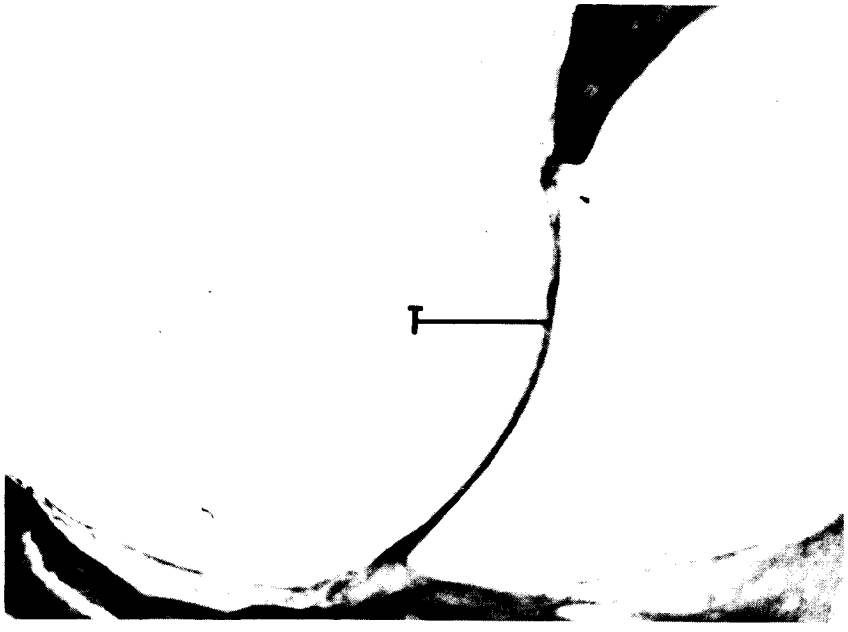

Figure 81. A63-035L, sl. 345. Section through the intact secondary tympanic membrane (T). X49

M I C R O S C O P I C A S P E C T S

SERIES A63-036R

Figures 82-93

Figure 82. A63-036R, sl. 260. A section through the ampulla of the posterior canal (P) showing one end invaginated. The crest is without a cupula, which may be represented by the material at the arrow. There is heavy precipitate (Q) to the right of the crest. X49



Figure 83. A63-036R, sl. 150. A section of the crest of the superior canal (S) with a "cloud-like" cupula (C). X49

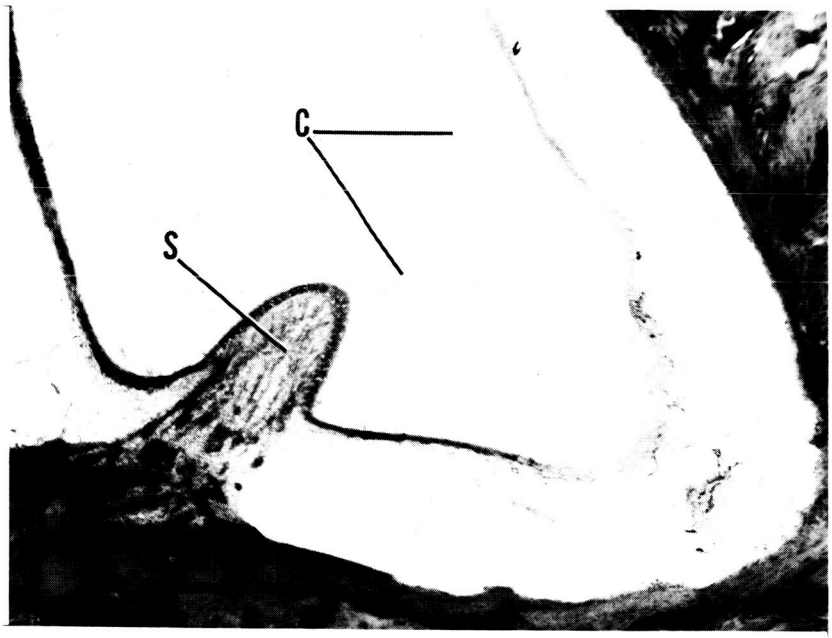

Figure 84. A63-036R, sl. 160. A section at the apex of the crest of the superior canal (S) with the cupula (C) lifted and deflected to one side. X49

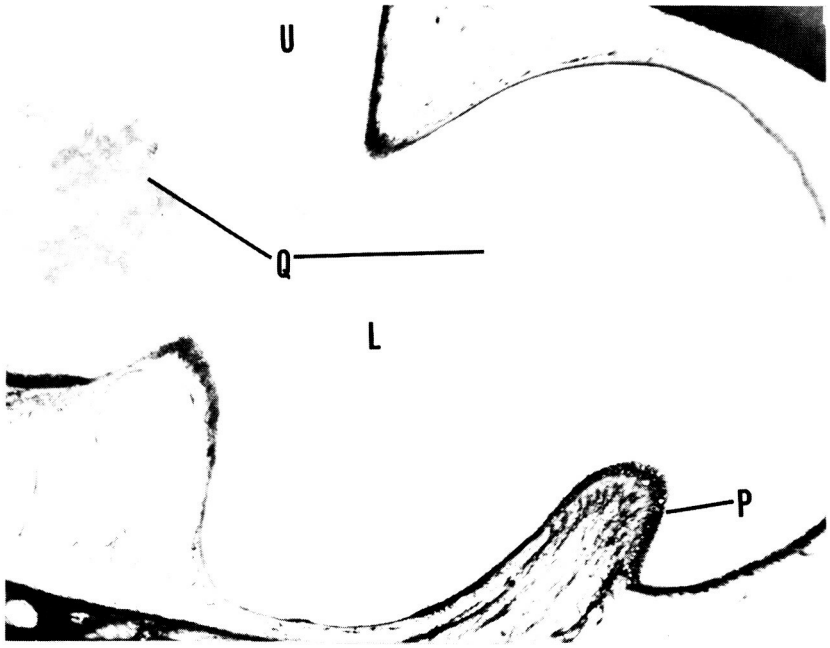

Figure 85. A63-036R, sl. 220. This section passes a point where the ampulla of the lateral canal (L) joins the utricle (U) showing a large amount of granular acidophilic material (Q) both in the utricle and ampulla. The cupula is absent from the crest but the hair processes (P) are visible on its surface. X49

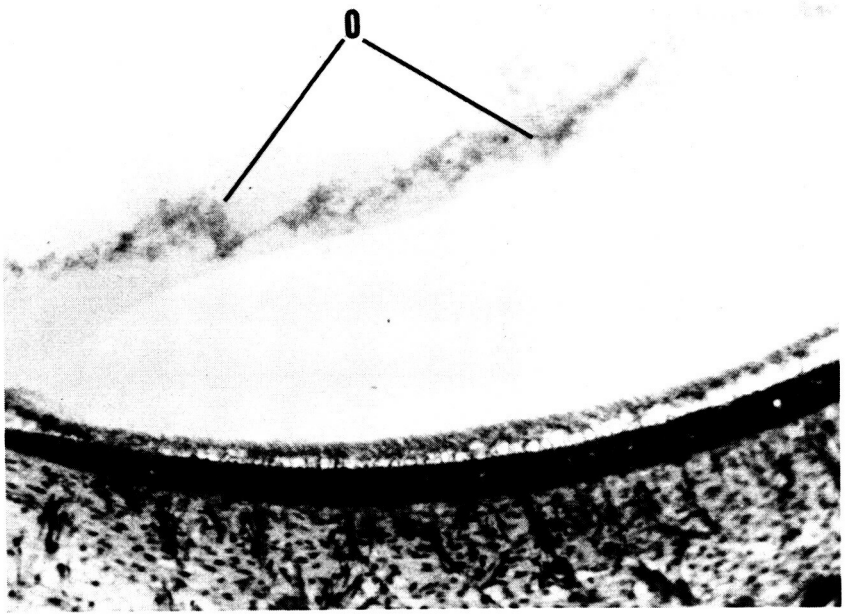

Figure 86. A63-036R, sl. 200. An intermediate power photomicrograph of the macula utricli, showing the otolithic membrane (O) partially elevated. X140

Figure 87. A63-036R, sl. 214. Section through the macular region of the utricle with an unusually large amount of precipitate in the lumen. The otolithic membrane (O) is only slightly raised. X= artefact. X49

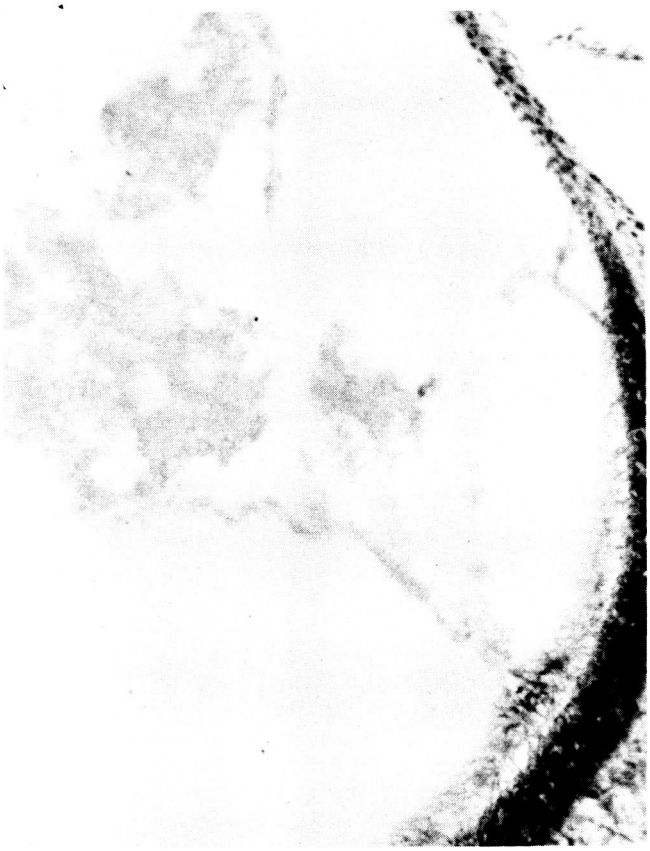

Figure 88. A63-036R, sl. 214. A higher magnification of the macular region of the preceding section. X140

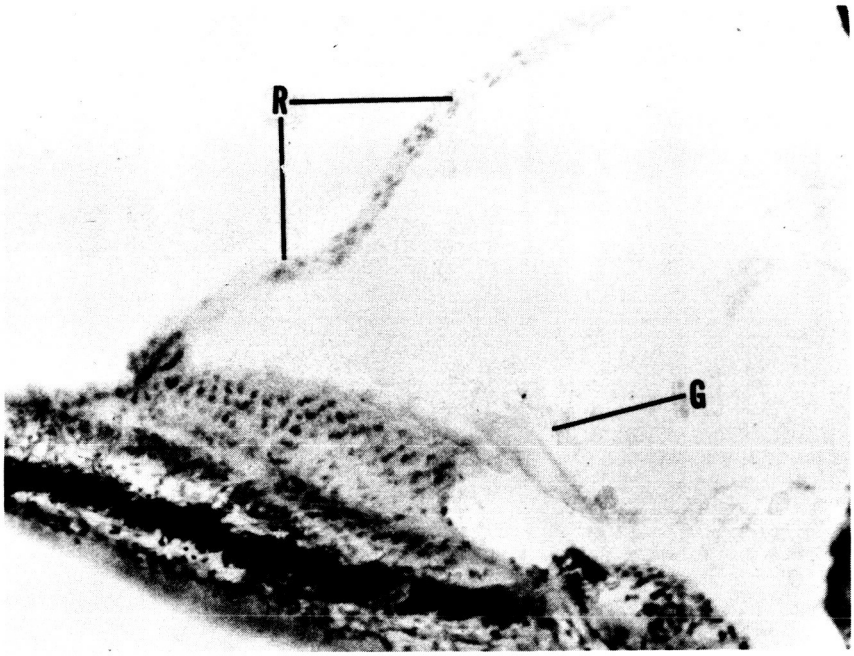

Figure 89. A63-036R, sl. 180. A section through an essentially normal cochlea. G= tectorial membrane; R= vestibular membrane. X140

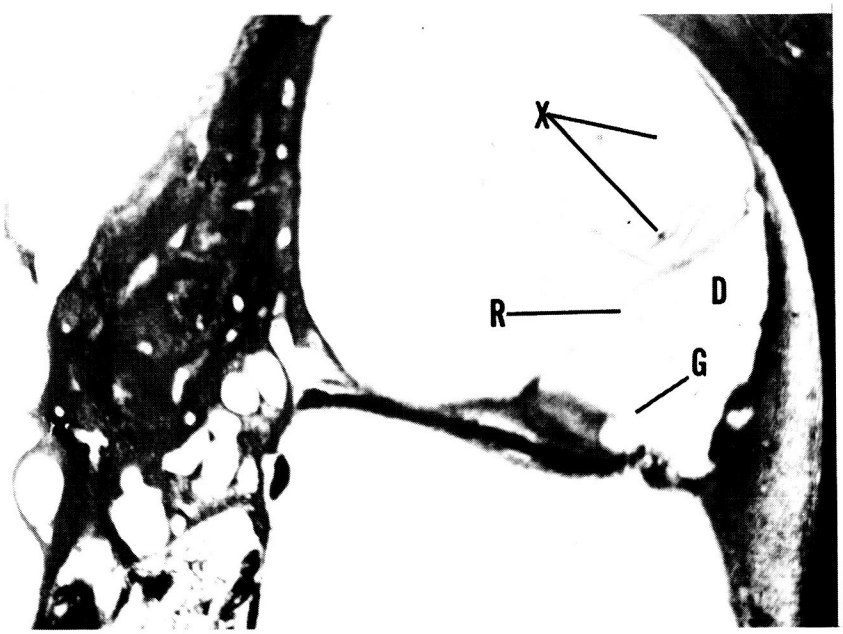

Figure 90. A63-036R, sl. 220. A section through a coil of the cochlea showing an essentially normal cochlear duct (D) except for some precipitate. R= vestibular membrane; G= tectorial membrane; X= artefact. X49

Figure 91. A63-036R, sl. 220. An intermediate power photomicrograph of the cochlear duct of the preceding figure. X140

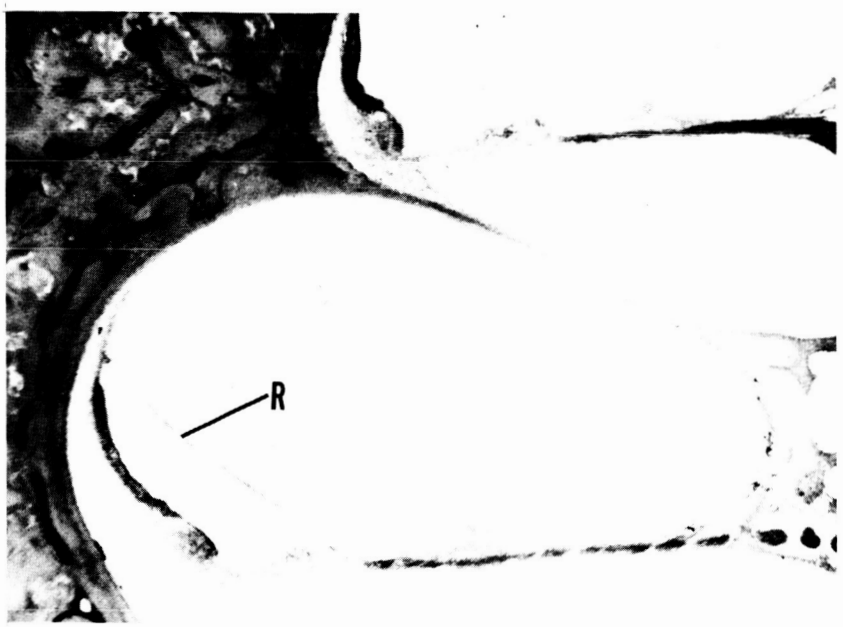

Figure 92. A63-036R, sl. 250. A relatively normal cochlea showing some compression of the vestibular membrane (R). X49



Figure 93. A63-036R, sl. 350. A section through the round window showing an intact secondary tympanic membrane (T). Y= scala tympani; V= scala vestibuli. X49

M I C R O S C O P I C A S P E C T S

SERIES A63-036L

Figures 94-107

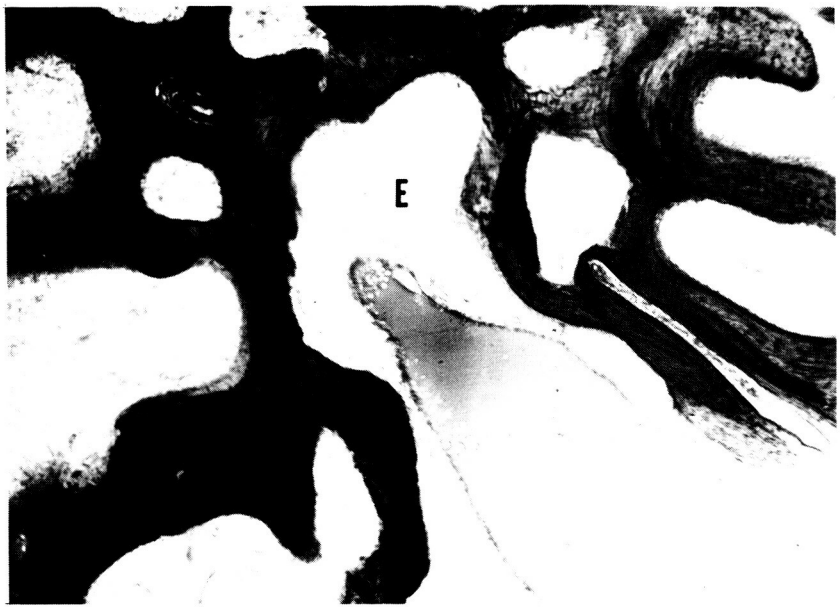

Figure 94. A63-036L, sl. 100. Section through some of the air spaces, one of which contains a large amount of highly granular, faintly acidophilic substance. The endosteum (E) is also thickened. X49

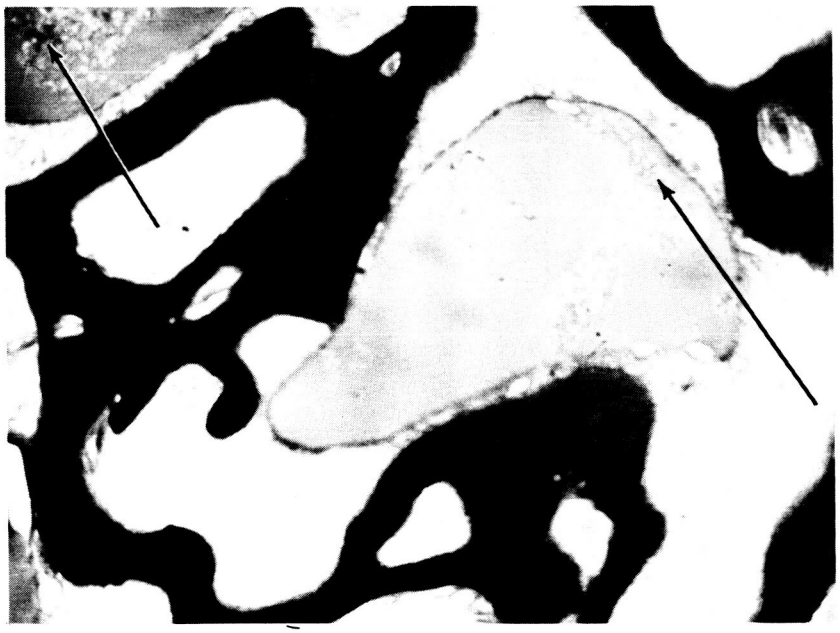

Figure 95. A63-036L, sl. 290. A section through the petrous air spaces showing the accumulation of acidophilic material which contains areas of vacuolization and some mononuclear cells (at arrows). X49

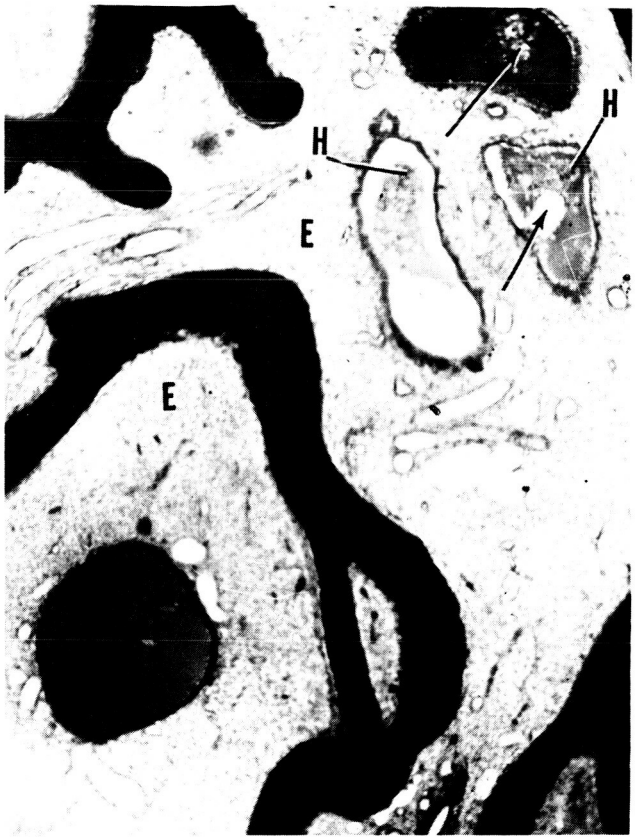

Figure 96. A63-036L, sl. 430. In this area, the lining membrane of the petrous air spaces has greatly thickened (E). In their much reduced lumena is a strongly acidophilic material in which vacuolated areas may appear (at arrows). A few cells (H). B= bony trabeculae. X49

Figure 97. A63-036L, sl. 430. A higher power photomicrograph of the acidophilic substance seen in figure 96. X140

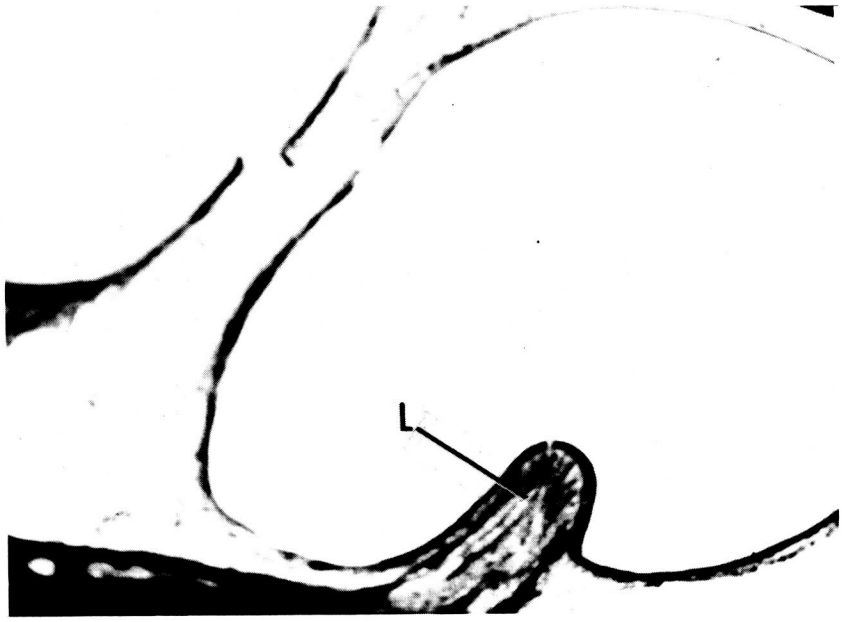

Figure 98. A63-036L, sl. 255. Section of the ampulla with a crest (L) of the lateral canal. The cupula and the hair processes are not evident. X49

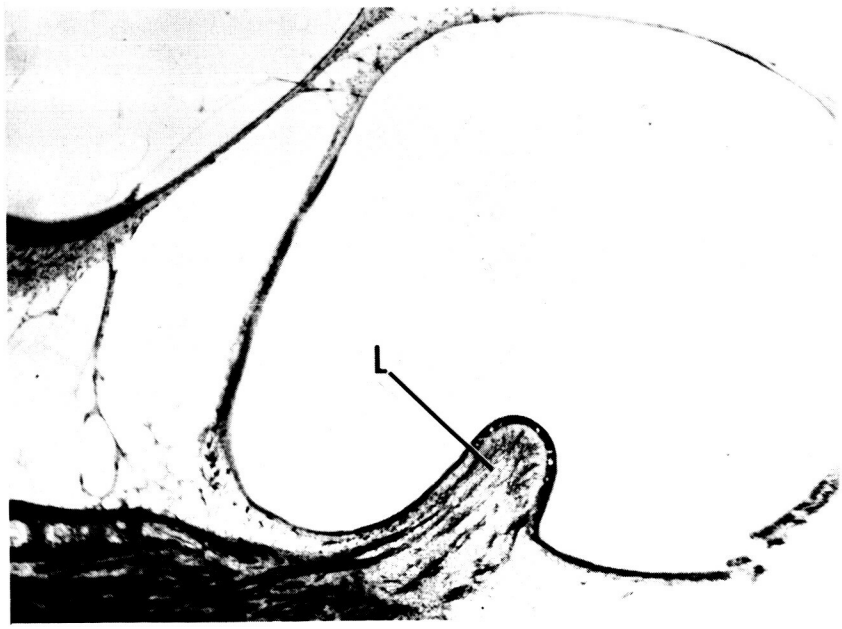

Figure 99. A63-036L, sl. 260. Another area of the crest (L) of the lateral canal showing absence of both hair cells and cupula. X49

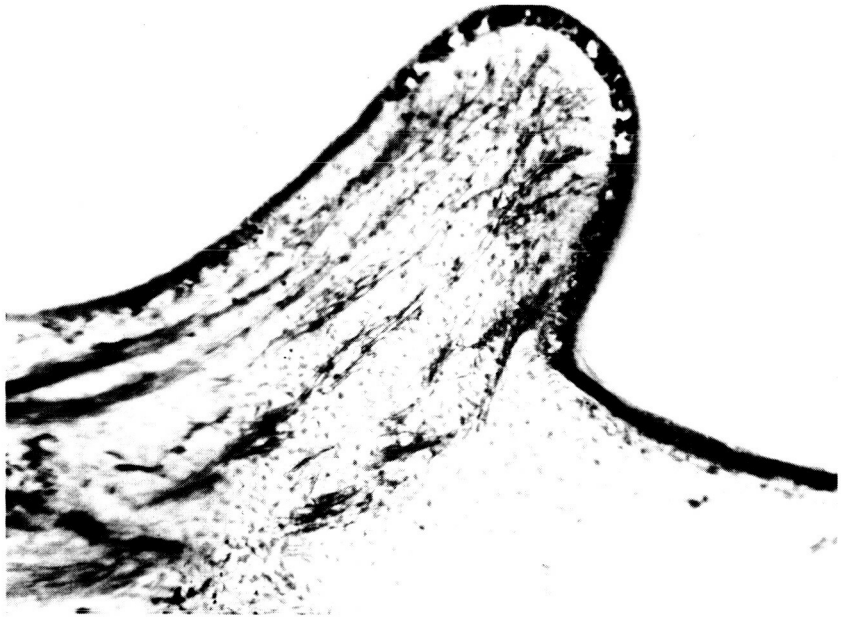

Figure 100. A63-)36L, sl. 260. The same crese seen in figure 99 at higher magnification. X140

Figure 101. A63-36L, sl. 270. This section passes through another area of the same lateral crest. The shadowy material (arrow) may represent the cupula. X49

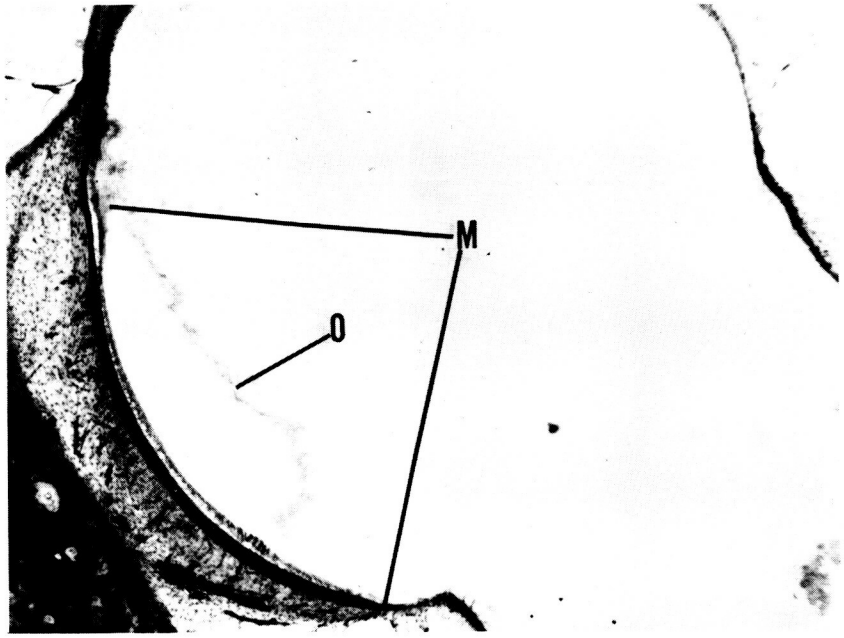

Figure 102. A63-036L, sl. 200. A section through the utricle showing the elevated otolithic membrane (0). M= macula. X49

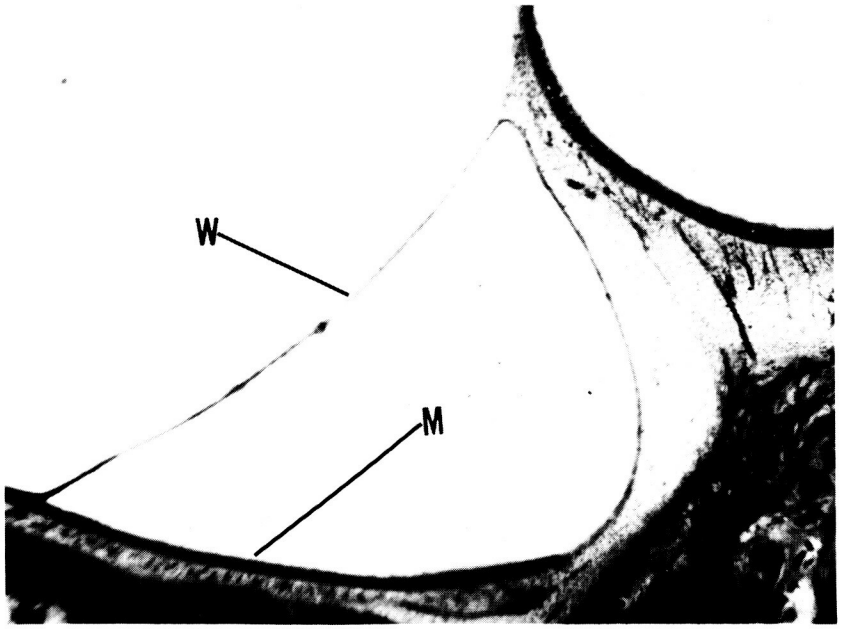

Figure 103. A63-036L, sl. 240. A section through the macular region of the saccule and part of the utricle. The wall of the saccule (W) has partially collapsed upon its macula (M). No otolithic membranes are apparent. X49

Figure 104. A63-036L, sl. 240. A higher magnification of the area where the wall of the saccule lies on the macula (arrow). X140

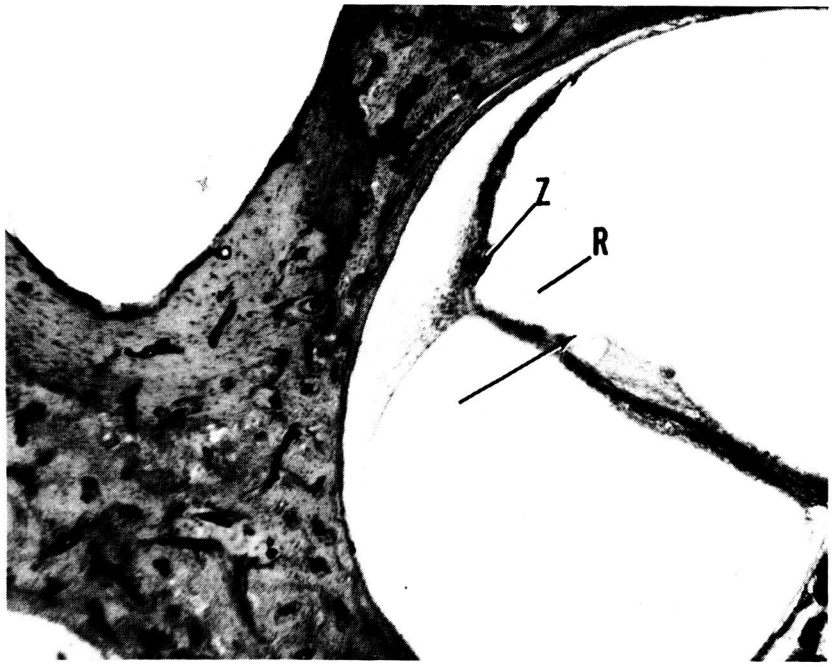

Figure 105. A63-036L, sl. 255. Section through one coil of the cochlea showing the vestibular membrane (R) depressed all the way against the vascular stria (Z) and on top of the organ of Corti (arrow). X49

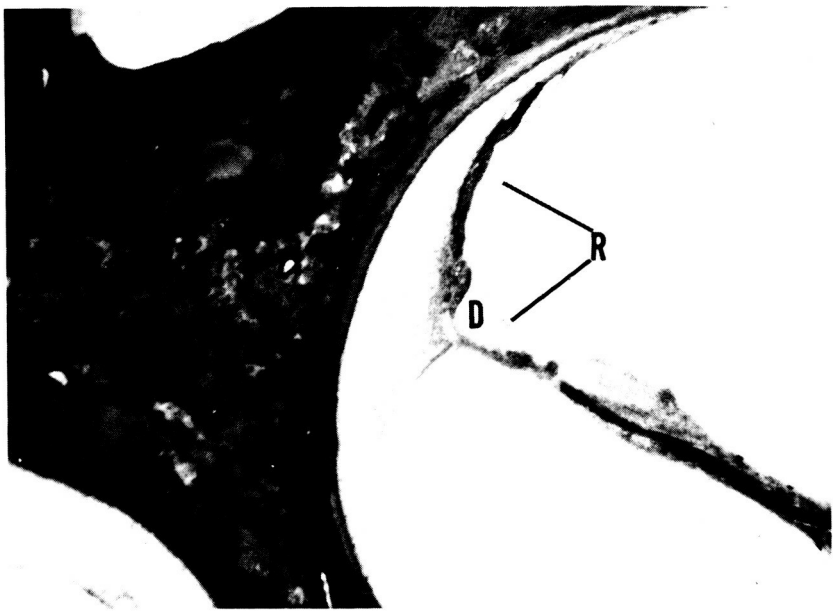

Figure 106. A63-036L, sl. 270. A section through part of one coil of the cochlea showing the continued collapse of the vestibular membrane (R) of the cochlear duct (D). X49

Figure 107. A63-036L, sl. 270. A higher power photomicrograph of the cochlea showing its collapse. X140

M I C R O S C O P I C A S P E C T S

SERIES A63-038R

Figures 108-111

Figure 108. A63-038R, sl. 20. Section through one of the large air spaces containing a heavily granular, deeply acidophilic substance. B= bone. X49

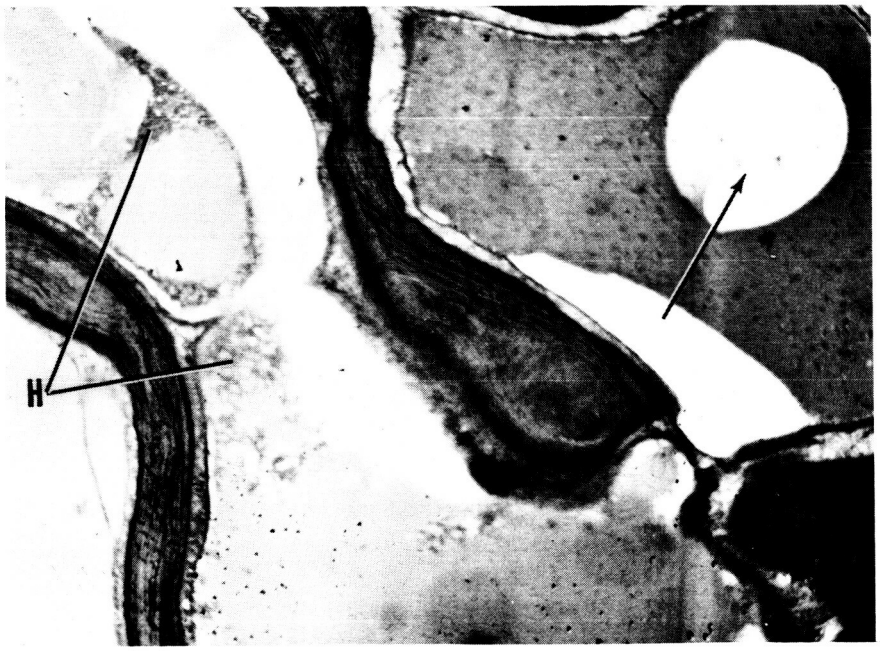

Figure 109. A63-038R, sl. 160. This section passes through parts of two spaces. Below to the left is a material similar to that seen in the preceding section, while the large area on the right is more pale, less dense and contains vacuolated areas (at arrow) and cells (H). B= bone. X49



Figure 110. A63-038R, sl. 230. Section to show compression and a pulling away of the lateral canal (L) from the bony wall (B). X= artefact. X49

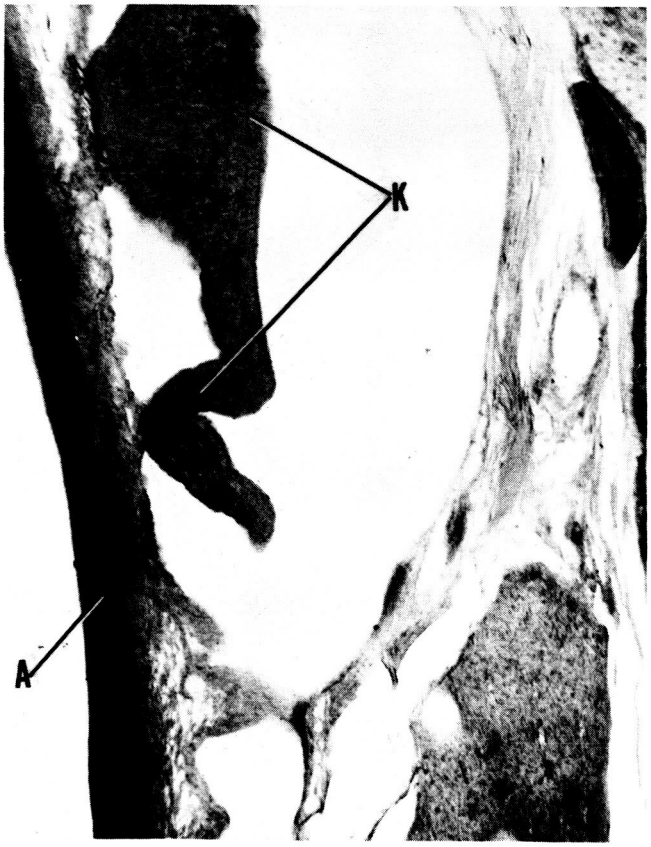

Figure 111. A63-038R, sl. 300. Section showing a retracted clot (K) along the carotid artery (A). X49

M I C R O S C O P I C A S P E C T S

SERIES A63-038L

Figures 112-119

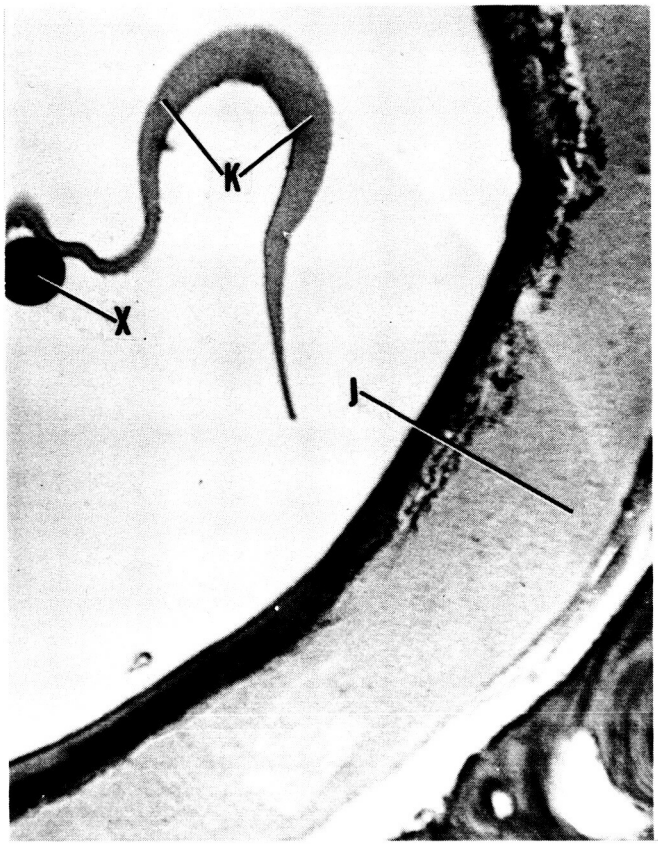

Figure 112. A63-038L, sl. 160. A section showing the congestion of the venous plexus (J) around the carotid artery. K= clot in artery; X= resin crystal. X49

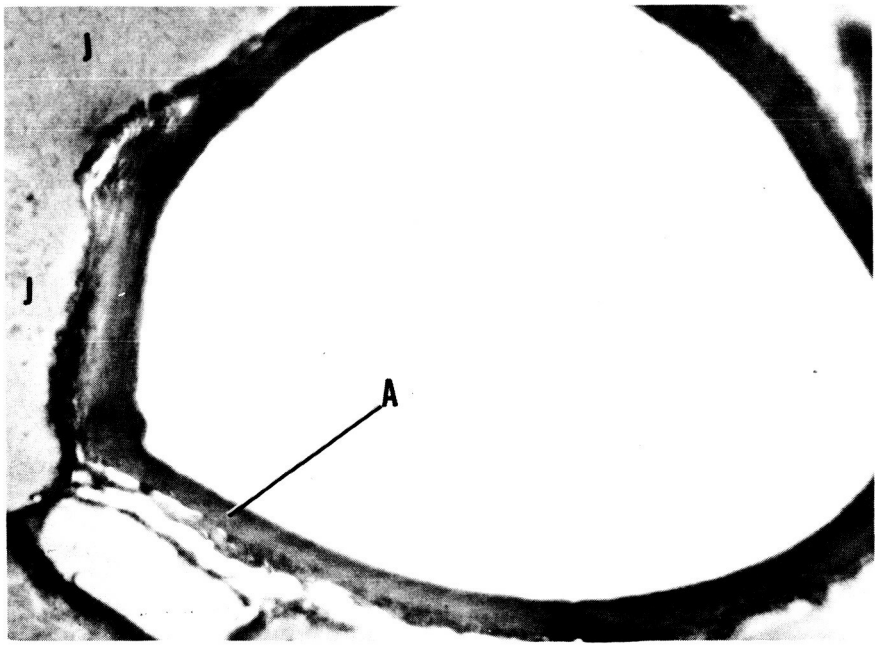

Figure 113. A63-038L, sl. 242. Section through the carotid artery (A) showing congestion of veins (J). X49

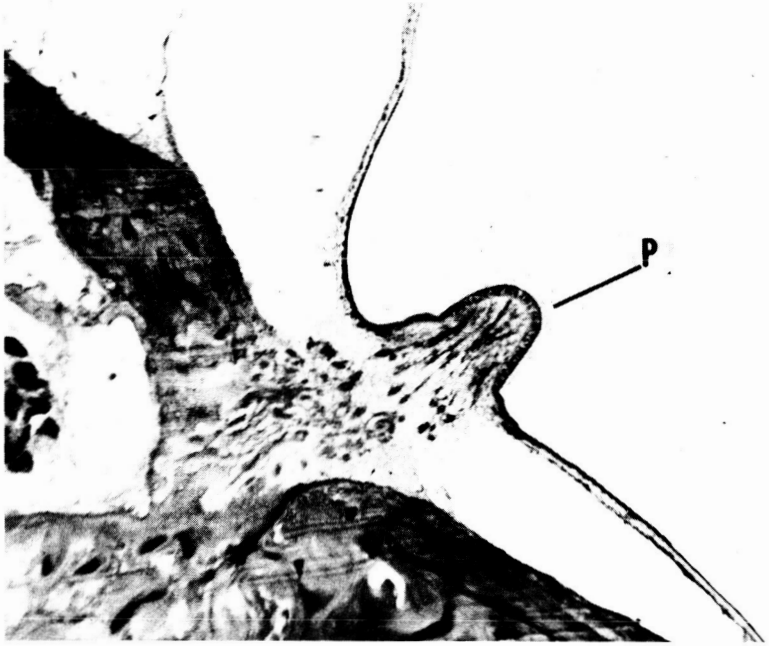

Figure 114. A63-038L, sl. 213. A section approaching the apex of a crest showing hair processes (P) without cupula. X49

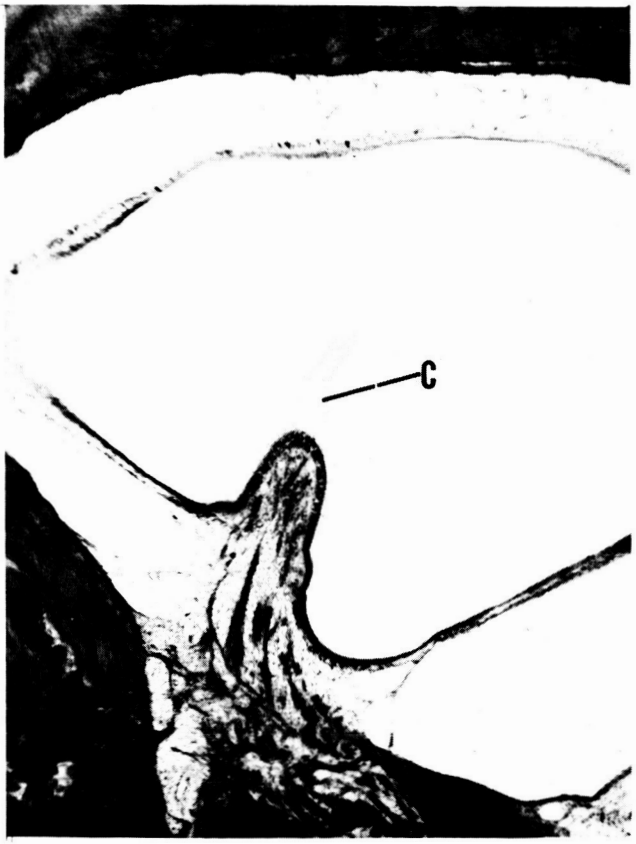

Figure 115. A63-038L, sl. 226. A section at the apex of the crest of the superior canal showing a normal cupula (C). X49

Figure 116. A63-038L, sl. 226. A high power photomicrograph of the same crest and cupula seen in the preceding figure. C= cupula. X140

Figure 117. A63-038L, sl. 242. A section through the macula (M) utriculi with a relatively normal otolithic membrane (0). X49



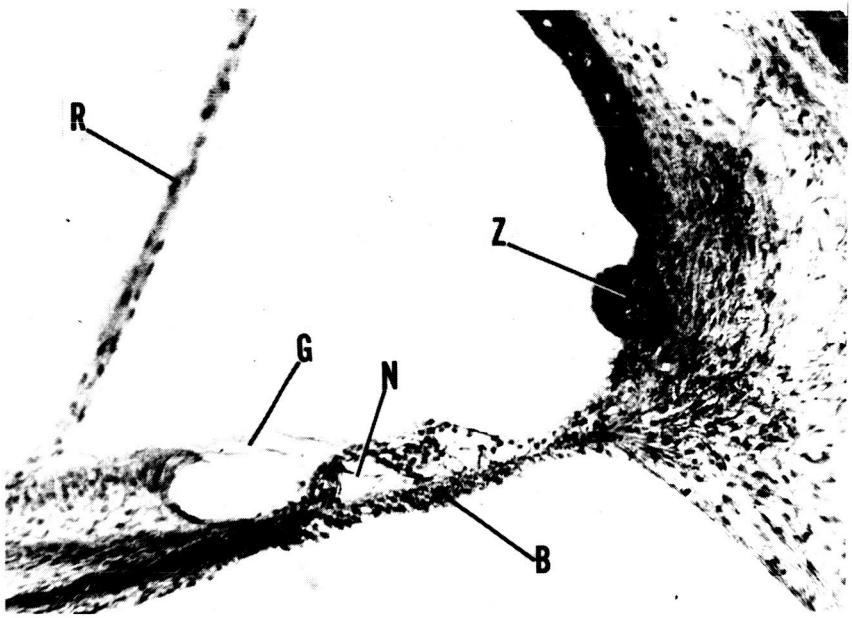

Figure 118. A63-038L, sl. 213. A section through the cochlea which appears about normal. R= vestibular membrane; B= basilar membrane; N= tunnel; G= tectorial membrane; Z= vascular stria. X140

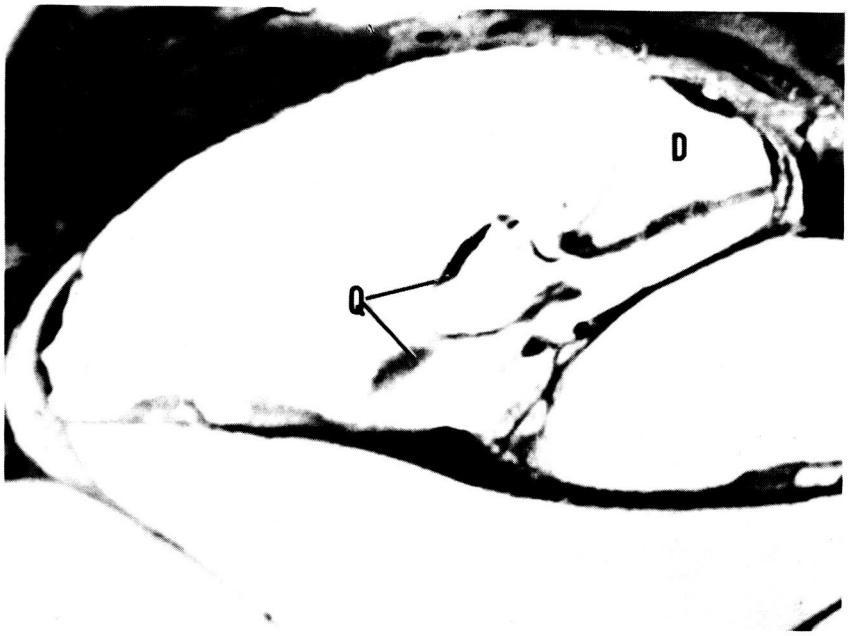

Figure 119. A63-038L, sl. 310. A section near the apex of the cochlea in the area of the helicotrema showing an abnormally large amount of precipitated material (Q) and tissue fragments. D= cochlear duct. X49

Unclassified

Security Classification

DOCUMENT CONTROL DATA - R&D

(Security classification of title, body of abstract and indexing annotation must be entered when the overall report is classified)

1. ORIGINATING ACTIVITY *(Corporate author)*
New York Medical College

2a. REPORT SECURITY CLASSIFICATION
Unclassified

2b. GROUP

3. REPORT TITLE
HISTOPATHOLOGY OF THE CHIMPANZEE EAR

4. DESCRIPTIVE NOTES *(Type of report and inclusive dates)*
Final, 1 March 1964 - 31 December 1965

5. AUTHOR(S) *(Last name, first name, initial)*
House, E.L. Jacobs, M.E. Pansky, B. et al.

6. REPORT DATE
June 1966

7a. TOTAL NO. OF PAGES
111

7b. NO. OF REFS
40

8a. CONTRACT OR GRANT NO.
AF 29(600)-4563

b. PROJECT NO.
6892

c.

d.

9a. ORIGINATOR'S REPORT NUMBER(S)
ARL-TR-66-15

9b. OTHER REPORT NO(S) *(Any other numbers that may be assigned this report)*

10. AVAILABILITY/LIMITATION NOTICES This document is subject to special export controls and each transmittal to foreign governments or foreign nations may be made only with prior approval of the 6571st ARL, Holloman AFB, NM.

11. SUPPLEMENTARY NOTES

12. SPONSORING MILITARY ACTIVITY
6571st Aeromedical Rsch Lab.
Holloman AFB, NMex

13. ABSTRACT Four female and two male chimpanzees were secured in various positions on a Daisy Decelerator and subjected to forces ranging from 54 to 180 F. It was found that forces in excess of 54 G may rupture the tympanic membranes and cause subepithelial hemorrhages in the middle ear. The majority of cases showed proteinaceous material, with or without cells in the petrous air spaces. When exposed to forces above 119 G, there was engorgement and often rupture of the pericarotid venous plexus. When supine, distortion of both superior and posterior semicircular canals was found. With forces in excess of 54 G, the cupulae of the cristae ampullaris were either elevated or destroyed. The hair processes were also often broken off. The otolithic membranes, especially of the maculae utriculi were also elevated or otherwise distorted and the saccule was often partially collapsed. In several instances, there was an overabundance of a proteinaceous substance in the lumina of the vestibular apparatus and in the cochlear ducts with their associated scalae. In half the cases, the cochlear duct was narrowed by the depression of the vestibular membrane. Although there seems to be considerable individual variation in ability to withstand these forces, neither age, sex nor weight appear to directly influence the results. The possible sources for the materials found both in the air cells and labyrinth are discussed.

DD FORM 1 JAN 64 1473

Unclassified

Security Classification

Unclassified
Security Classification

14. KEY WORDS	LINK A ROLE	LINK A WT	LINK B ROLE	LINK B WT	LINK C ROLE	LINK C WT
Primate						
Chimpanzee						
Ear						
Gravitational Forces						

INSTRUCTIONS

1. ORIGINATING ACTIVITY: Enter the name and address of the contractor, subcontractor, grantee, Department of Defense activity or other organization *(corporate author)* issuing the report.

2*a*. REPORT SECURITY CLASSIFICATION: Enter the overall security classification of the report. Indicate whether "Restricted Data" is included. Marking is to be in accordance with appropriate security regulations.

2*b*. GROUP: Automatic downgrading is specified in DoD Directive 5200.10 and Armed Forces Industrial Manual. Enter the group number. Also, when applicable, show that optional markings have been used for Group 3 and Group 4 as authorized.

3. REPORT TITLE: Enter the complete report title in all capital letters. Titles in all cases should be unclassified. If a meaningful title cannot be selected without classification, show title classification in all capitals in parenthesis immediately following the title.

4. DESCRIPTIVE NOTES: If appropriate, enter the type of report, e.g., interim, progress, summary, annual, or final. Give the inclusive dates when a specific reporting period is covered.

5. AUTHOR(S): Enter the name(s) of author(s) as shown on or in the report. Enter last name, first name, middle initial. If military, show rank and branch of service. The name of the principal author is an absolute minimum requirement.

6. REPORT DATE: Enter the date of the report as day, month, year; or month, year. If more than one date appears on the report, use date of publication.

7*a*. TOTAL NUMBER OF PAGES: The total page count should follow normal pagination procedures, i.e., enter the number of pages containing information.

7*b*. NUMBER OF REFERENCES: Enter the total number of references cited in the report.

8*a*. CONTRACT OR GRANT NUMBER: If appropriate, enter the applicable number of the contract or grant under which the report was written.

8*b*, 8*c*, & 8*d*. PROJECT NUMBER: Enter the appropriate military department identification, such as project number, subproject number, system numbers, task number, etc.

9*a*. ORIGINATOR'S REPORT NUMBER(S): Enter the official report number by which the document will be identified and controlled by the originating activity. This number must be unique to this report.

9*b*. OTHER REPORT NUMBER(S): If the report has been assigned any other report numbers *(either by the originator or by the sponsor)*, also enter this number(s).

10. AVAILABILITY/LIMITATION NOTICES: Enter any limitations on further dissemination of the report, other than those imposed by security classification, using standard statements such as:

(1) "Qualified requesters may obtain copies of this report from DDC."

(2) "Foreign announcement and dissemination of this report by DDC is not authorized."

(3) "U. S. Government agencies may obtain copies of this report directly from DDC. Other qualified DDC users shall request through _____."

(4) "U. S. military agencies may obtain copies of this report directly from DDC. Other qualified users shall request through _____."

(5) "All distribution of this report is controlled. Qualified DDC users shall request through _____."

If the report has been furnished to the Office of Technical Services, Department of Commerce, for sale to the public, indicate this fact and enter the price, if known.

11. SUPPLEMENTARY NOTES: Use for additional explanatory notes.

12. SPONSORING MILITARY ACTIVITY: Enter the name of the departmental project office or laboratory sponsoring *(paying for)* the research and development. Include address.

13. ABSTRACT: Enter an abstract giving a brief and factual summary of the document indicative of the report, even though it may also appear elsewhere in the body of the technical report. If additional space is required, a continuation sheet shall be attached.

It is highly desirable that the abstract of classified reports be unclassified. Each paragraph of the abstract shall end with an indication of the military security classification of the information in the paragraph, represented as *(TS)*, *(S)*, *(C)*, or *(U)*.

There is no limitation on the length of the abstract. However, the suggested length is from 150 to 225 words.

14. KEY WORDS: Key words are technically meaningful terms or short phrases that characterize a report and may be used as index entries for cataloging the report. Key words must be selected so that no security classification is required. Identifiers, such as equipment model designation, trade name, military project code name, geographic location, may be used as key words but will be followed by an indication of technical context. The assignment of links, rules, and weights is optional.