NASA-TM-111184

REPRINT
7N-52-TM
7166
23

Multiple coronary arterial loops as a cause of myocardial ischemia

Tali T. Bashour, MD, Nagi N. Mansour, PhD, and Damon Lee, MD *San Francisco, Daly City, and Moffett Field, Calif.*

Coronary arterial loops have been suspected of causing or aggravating myocardial ischemia.[1] However, the extent and significance of the ischemia produced by this mechanism remains to a large extent unknown. It seems logical that if a reduction in flow exists, it would be proportionate to the completeness of coils, their proximity and multiplicity in one artery, and the number of coronary arteries involved. We report a case of long-standing angina with ischemia documented by exercise testing and thallium scintigraphy in a patient who had multiple proximal loops in all three major coronary arteries in the absence of luminal stenosis.

A 60-year-old woman was evaluated because of effort-induced midsternal chest pain with radiation to the neck. She had a 10-year history of similar pain. Coronary arteriography had been performed 5 years earlier and was reported to have shown "extreme tortuosity" without obstructive lesions. She was treated with nifedipine for a presumptive diagnosis of coronary spasm. Less than complete relief was achieved, but she was satisfied with her mildly limited life style. The recent evaluation was prompted by an increase in the severity and frequency of the chest pain. The only risk factor for coronary atherosclerosis was mild hypertension, which was controlled with metoprolol at a daily dose of 50 mg. Physical examination revealed a blood pressure of 140/80 mm Hg. No abnormalities were found on pulmonary and cardiovascular examinations. An electrocardiogram was consistent with lateral wall ischemia in that it showed symmetric T wave inversion. Results of low-level exercise test were positive, with 2 mm horizontal ST depression (Fig. 1, *A*) in the left precordial leads and 1 mm depression in the inferior leads. Thallium scintigraphy revealed a largely reversible perfusion defect in the distal

From the Western Heart Institute, St. Mary's Hospital and Medical Center; The San Francisco Heart Institute at Seton Hospital; and NASA Ames Research Center.

Reprint requests: Tali T. Bashour, MD, Western Heart Institute, St. Mary's Hospital and Medical Center, 450 Stanyan St., San Francisco, CA 94117.

AM HEART J 1993;126:219-221

Copyright © 1993 by Mosby-Year Book, Inc.

0002-8703/93/$1.00 + .10 **4/4/46416**

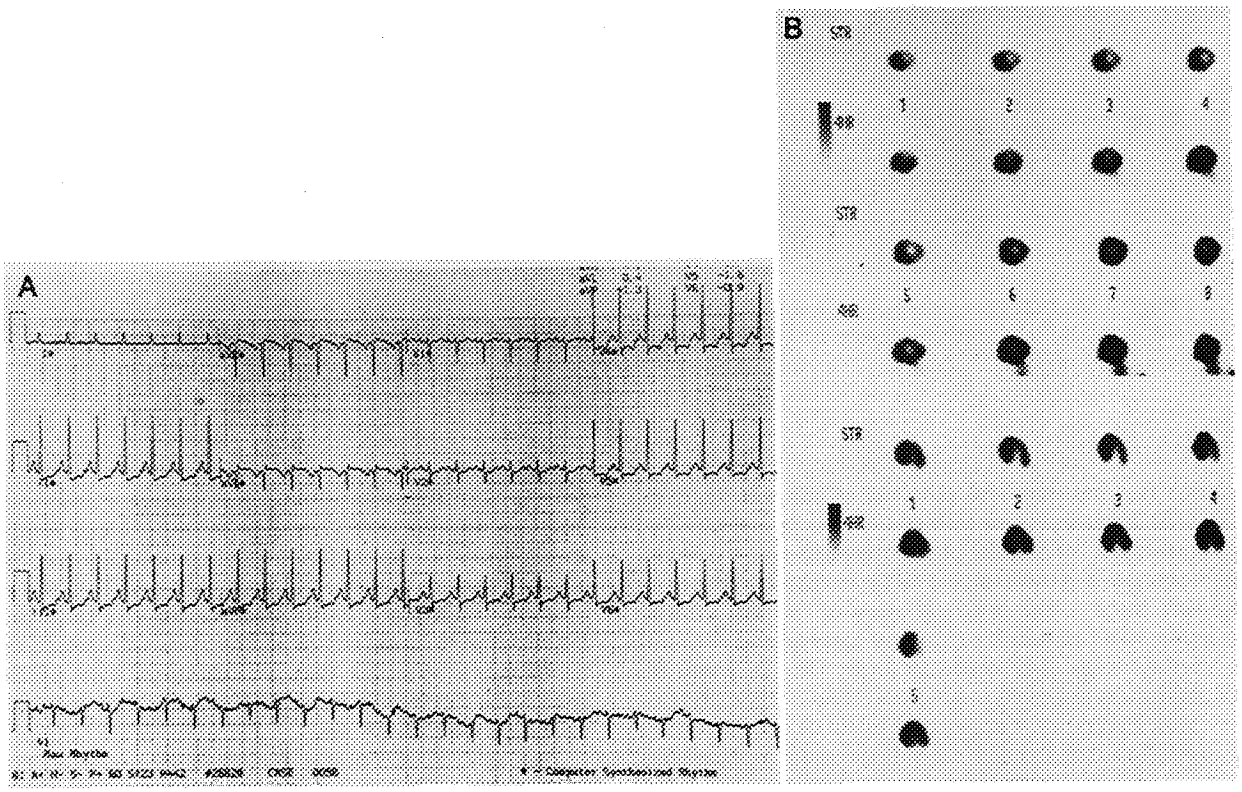

Fig. 1. A, Twelve-lead ECG during exercise showing ST changes suggestive of inferolateral ischemia. **B,** Single photon emission computed tomographic thallium images during stress *(STR)* and after 4 hours *(4HR)* revealing reversible anterolateral defects.

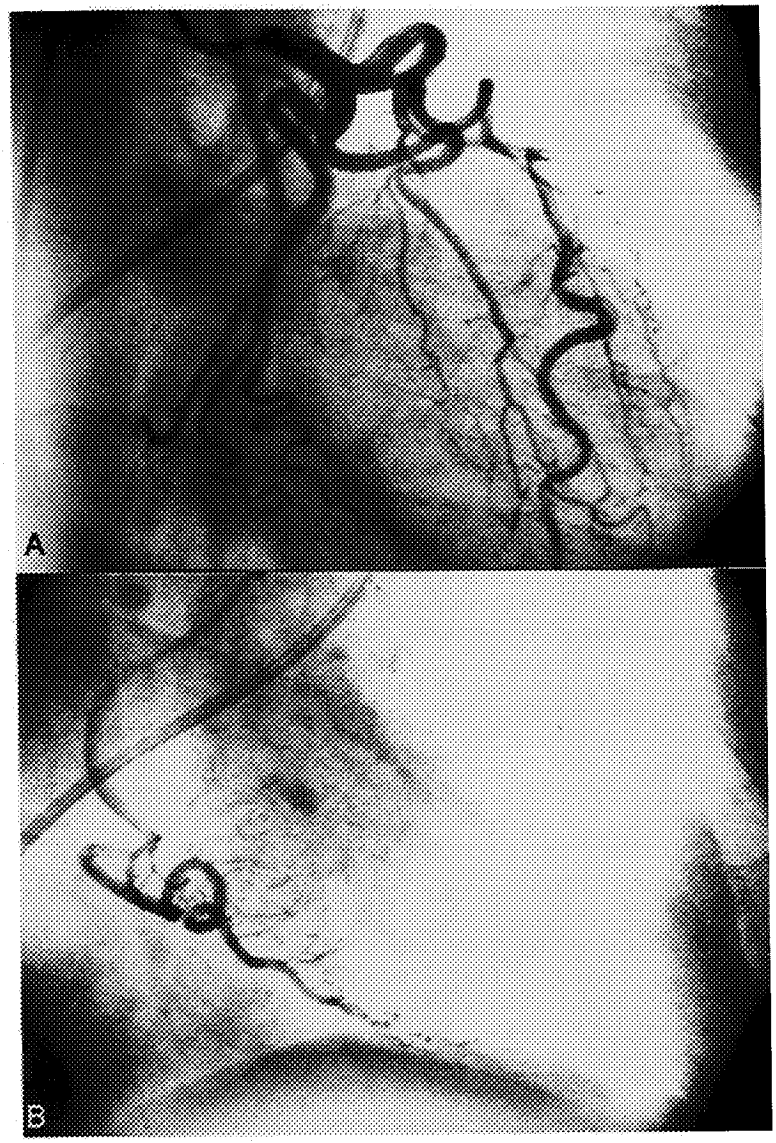

Fig. 2. A, Left coronary angiogram in right anterior oblique projection. Note multiple loops in proximal segments of left anterior descending and circumflex branches. **B,** Multiple loops in middle third of right coronary artery.

anterior and anterolateral portions of the left ventricle (Fig. 1, *B*). In view of these findings, cardiac catheterization was performed. No definite obstructive lesions were found. There was marked tortuosity of all three vessels with nearly complete loops in the proximal areas of the left anterior descending and circumflex coronary arteries and the middle portion of the right coronary artery (Fig. 2, *A* and *B*). Distal flow was observed to be slower than normal. Pulmonary artery pressure was elevated to 40/18 mm Hg (mean 28) and left ventricular end-diastolic pressure to 16 mm Hg. A left ventricular angiogram showed mild symmetric hypertrophy with good contractility. It was suspected that the ischemia was due to reduced flow during exercise resulting from impedance across the multiple proximal loops. Since no major artery was free of loops, collateral flow was presumably inadequate. β-Blockers, because of their direct influence on reduction of the oxygen demand, were thought to be more effective than vasodilators. The patient's symptoms did indeed improve markedly with metoprolol at a daily dose of 100 mg.

This case, in addition to a similar one reported previously, [1] suggests that myocardial ischemia can result from

extreme coiling of coronary arteries, especially when the anomaly is multiple, proximally located, and involves at least two or all three coronary arteries. To better understand this phenomenon, the laws of physics pertaining to flow of fluids in coiled pipes were reviewed. The effects of bends and branches are known to be important in a physiologic context, since they affect the decrease in pressure. In the extreme limit, where the arteries are completely coiled, the decrease in pressure can be significant and causes an important reduction in the flow rate for a given pumping pressure. The flow rate is proportional to the friction coefficient, which increases in the presence of coiling. The fully developed laminar flow through coiled pipes depends primarily on the dimensionless parameter (also known as the Dean number),

$$De = \frac{Ud}{v}\left(\frac{d}{D}\right)^{1/2}$$

where U is the bulk mean speed of the flow, d is the pipe diameter, D is the coiling diameter, and v is the kinematic viscosity.

In a study of the pressure drop in coiled pipes, Ramshankar and Sreenivasan[2] have shown that the ratio of a friction factor (fc) in the coiled pipe to that in the straight pipe (fs) for the same mass flux varies as (for $30 < De < 2000$), $fc/fs = 0.097\ De^{1/2} + 0.556$. The coiling effects are a function of the Dean number. For De <30 there is little effect. For a given diameter and viscosity, the mass flow rate is proportional to the Reynolds number ($Re = Ud/v$). We have plotted in Fig. 3 the ratio of the friction coefficients (fc/fs) as a function of the Reynolds number for various coiling (d/D). We find that the coiling effects can be significant even at low Reynolds numbers. For the present case a typical coil has $d/D = 0.5$; this will cause an increase in the pressure drop by a factor of 1.8 at $Re = 250$ compared to straight arteries. This degree of reduction may not be critical in the resting state. However, when the patient is exercising, the flow rate can increase by a factor of 2. At $Re = 500$ the friction coefficient increases by a factor of 2.4, which is significant and can induce the same symptoms as stenosis. In conclusion, myocardial ischemia can be related to severely coiled coronary arteries that are otherwise normal. Basic rules of flow dynamics in pipelike conduits tend to support these observations. This phenomenon may be more common than is generally appreciated. Although extreme forms can cause ischemia in the absence of luminal obstruction, milder forms may theoretically aggravate ischemia in the presence of fixed coronary artery stenosis.

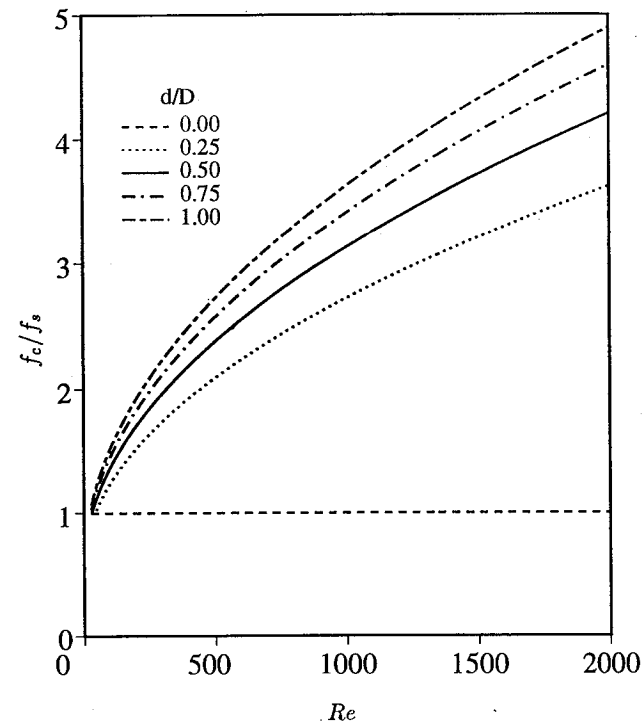

Fig. 3. Ratio of friction factor *(fc)* in curved pipe to that in straight pipe *(fs)* as function of Reynolds number *(Re)* (proportional to mass flow rate) for various coiling parameters. *d/D*, Ratio of pipe diameter to coil diameter.

REFERENCES

1. Barilla F, Romeo F, Rosano GMC, Valente A, Reale A. Coronary artery loops and myocardial ischemia. AM HEART J 1991;122:225-6.
2. Ramshankar R, Sreenivasan KR. Paradox concerning the extended Stokes Series Solution for the pressure drop in coiled pipes. Phys Fluids 1988;31:1339-47.