


7/11/02

576 25

348.

NASA/TP—2002—210779



## **Case Descriptions and Observations About Cutis Marmorata From Hypobaric Decompressions**

*Johnny Conkin, Ph.D., M.S.  
Lyndon B. Johnson Space Center  
Houston, Texas 77058-3696*

*Andrew A. Pilmanis, Ph.D., M.S.  
Air Force Research Laboratory  
High Altitude Protection / HEPR  
Brooks Air Force Base, Texas*

*James T. Webb, Ph.D., M.S.  
Wyle Life Sciences, Inc.  
Air Force Research Laboratory  
High Altitude Protection / HEPR  
Brooks Air Force Base, Texas*

## THE NASA STI PROGRAM OFFICE . . . IN PROFILE

Since its founding, NASA has been dedicated to the advancement of aeronautics and space science. The NASA Scientific and Technical Information (STI) Program Office plays a key part in helping NASA maintain this important role.

The NASA STI Program Office is operated by Langley Research Center, the lead center for NASA's scientific and technical information. The NASA STI Program Office provides access to the NASA STI Database, the largest collection of aeronautical and space science STI in the world. The Program Office is also NASA's institutional mechanism for disseminating the results of its research and development activities. These results are published by NASA in the NASA STI Report Series, which includes the following report types:

- **TECHNICAL PUBLICATION.** Reports of completed research or a major significant phase of research that present the results of NASA programs and include extensive data or theoretical analysis. Includes compilations of significant scientific and technical data and information deemed to be of continuing reference value. NASA's counterpart of peer-reviewed formal professional papers but has less stringent limitations on manuscript length and extent of graphic presentations.
- **TECHNICAL MEMORANDUM.** Scientific and technical findings that are preliminary or of specialized interest, e.g., quick release reports, working papers, and bibliographies that contain minimal annotation. Does not contain extensive analysis.
- **CONTRACTOR REPORT.** Scientific and technical findings by NASA-sponsored contractors and grantees.


- **CONFERENCE PUBLICATION.** Collected papers from scientific and technical conferences, symposia, seminars, or other meetings sponsored or cosponsored by NASA.
- **SPECIAL PUBLICATION.** Scientific, technical, or historical information from NASA programs, projects, and mission, often concerned with subjects having substantial public interest.
- **TECHNICAL TRANSLATION.** English-language translations of foreign scientific and technical material pertinent to NASA's mission.

Specialized services that complement the STI Program Office's diverse offerings include creating custom thesauri, building customized databases, organizing and publishing research results . . . even providing videos.

For more information about the NASA STI Program Office, see the following:

- Access the NASA STI Program Home Page at <http://www.sti.nasa.gov>
- E-mail your question via the Internet to [help@sti.nasa.gov](mailto:help@sti.nasa.gov)
- Fax your question to the NASA Access Help Desk at (301) 621-0134
- Telephone the NASA Access Help Desk at (301) 621-0390
- Write to:  
NASA Access Help Desk  
NASA Center for AeroSpace Information  
7121 Standard  
Hanover, MD 21076-1320

NASA/TP—2002–210779



# Case Descriptions and Observations About Cutis Marmorata From Hypobaric Decompressions

*Johnny Conkin, Ph.D., M.S.  
Lyndon B. Johnson Space Center  
Houston, Texas 77058-3696*

*Andrew A. Pilmanis, Ph.D., M.S.  
Air Force Research Laboratory  
High Altitude Protection / HEPR  
Brooks Air Force Base, Texas*

*James T. Webb, Ph.D., M.S.  
Wyle Life Sciences, Inc.  
Air Force Research Laboratory  
High Altitude Protection / HEPR  
Brooks Air Force Base, Texas*

National Aeronautics and  
Space Administration

Johnson Space Center  
Houston, Texas 77058-3696

---

April 2002

## Acknowledgment

We thank Mike Fox of Kelsey-Seybold's Manned Test Support at the Johnson Space Center for the photographs used in this report. Several colleagues contributed to the discussions about Cutis Marmorata: Michael R. Powell, Michael L. Gernhardt, Keena E. Acock, Philip P. Foster, Joseph P. Dervay, Karin C. Loftin, James M. Waligora, and William Collier. The National Aeronautics and Space Administration supported part of this work through the NASA Cooperative Agreement NCC 9-58 with the National Space Biomedical Research Institute.

Available from:

NASA Center for AeroSpace Information  
7121 Standard  
Hanover, MD 21076-1320

National Technical Information Service  
5285 Port Royal Road  
Springfield, VA 22161

This report is also available in electronic form at <http://techreports.larc.nasa.gov/cgi-bin/NTRS>

# CONTENTS

	<b>Page</b>
Acronyms and Nomenclature.....	iv
Abstract.....	1
Introduction.....	1
Anatomy and Control of Cutaneous Circulation.....	2
Description of Cutis Marmorata.....	4
Incidence of Altitude-Induced Cutis Marmorata.....	5
Case Descriptions of Cutis Marmorata.....	6
Pathophysiology of Cutis Marmorata.....	14
Categorization of Cutis Marmorata.....	18
Treatment of Cutis Marmorata.....	21
Conclusions and Recommendations.....	21
References.....	24

## Tables

Table I. Published and Personal Opinions about the Categorization of Cutis Marmorata ....	20
---	----

## Figures

Figure 1. Four views of Cutis Marmorata from case #7.....	15-16
---	-------

## ACRONYMS AND ABBREVIATIONS

AVA	arteriovenous anastomoses
BMI	body mass index
CM	Cutis Marmorata
CNS	central nervous system
DCS	decompression sickness
JSC	Johnson Space Center
O <sub>2</sub>	oxygen
psia	pounds per square inch absolute
SVP	subcutaneous venous plexus
USN TT V	United States Navy Treatment Table V
USN TT VI	United States Navy Treatment Table VI
VGE	venous gas emboli

## **Abstract**

There is disagreement about the pathophysiology, classification, and treatment of cutis marmorata (CM), so there is disagreement about the disposition and medical status of a person that had CM. CM is rare, associated with stressful decompressions, and may be associated with serious signs and symptoms of decompression sickness (DCS). CM presents as purple or bluish-red skin mottling, often in the pectoral region, shoulders, chest, or upper abdomen. It is unethical to induce CM in humans so all information comes from retrospective analysis of case reports, or from animal models. A literature search, seven recent case reports from the Johnson Space Center and Brooks Air Force Base Hypobaric DCS Databases, interviews with DCS treatment experts, and responses to surveys provided the factual information used to arrive at our conclusions and recommendations. The “weight of evidence” indicates that CM is a local, not centrally mediated or systemic response to bubbles. It is unclear whether obstruction of arterial or venous blood flow is the primary insult since the lesion is reported under either condition. Any neurological or cardiovascular involvements are coincidental, developing along the same time course. The skin could be the source of the bubbles due to its mass, the associated layer of fat, and the variable nature of skin blood flow. CM should not be categorized as Type II DCS, should be included with other skin manifestations in a category called cutaneous DCS, and hyperbaric treatment is only needed if ground level oxygen is ineffective in the case of altitude-induced CM.

## **Introduction**

CUTIS MARMORATA (CM), also called skin mottling or skin marbling, is a sign of decompression sickness (DCS) or, more specifically, a gas lesion disease<sup>1</sup>. CM is only one form of “skin bends,” and each form has occurred alone or in combinations with the others. The topic of skin bends is covered in several books about DCS<sup>2-7</sup>. CM has been observed for as long as humans have been diving or flying at high altitude. CM was even described in a subject surrounded in heliox while breathing a nitrox mixture at 7 ATA<sup>8</sup>. The purported mechanism was a gas-induced osmosis causing a water imbalance in the skin. Later, superficial cutaneous isobaric gas counterdiffusion was proposed as a mechanism for the gas supersaturation in the skin<sup>1,9,10</sup>. We focus this communication on a discussion of CM from hypobaric decompressions.

Case descriptions of CM from hyperbaric<sup>8</sup> and hypobaric<sup>5,11</sup> decompressions are available. The most detailed observations about CM come from recent studies of neurological DCS in a swine model<sup>12,13</sup>, and earlier studies of superficial cutaneous isobaric gas counterdiffusion, also in swine<sup>1</sup>.

Our method to understanding CM was to gather information from four sources: a) the scientific literature (journal reports, internal reports, and books); b) interviews with clinical experts in the treatment of DCS; c) solicited responses to surveys<sup>14,15</sup>; and d) recent information contained in the Johnson Space Center (JSC) and Brooks Air Force Base (AFB) Hypobaric DCS Databases. We summarize much of the CM literature, particularly CM associated with hypobaric exposures. Seven recent cases of CM from research in altitude chambers are described that, for the first time, include correlative information about circulating venous gas bubbles. Our aims are to document the limited understanding about the pathophysiology of CM, the opinions about categorizing CM, and to offer general recommendations for the treatment of CM associated with hypobaric exposures.

## **Anatomy and Control of Cutaneous Circulation**

A mechanism for CM is easier to postulate and the subsequent sections are better integrated if the basic anatomy and control of blood flow in the skin is first reviewed. The dermis and the subcutaneous layer receive nutritive blood flow and blood flow to regulate body temperature. The nutritive flow is a small component of total cardiac output. Normal blood flow under cool environmental conditions is about 400 ml/min, more than adequate to provide for proper oxygenation, and this perfusion can increase to 2.8 liter/min under warm conditions. The subcutaneous venous plexus (SVP) forms a large-capacitance reservoir for venous blood, and in some areas, such as the hands, feet, lips, nose, and ears, arteriovenous anastomoses (AVA) exist. The arms, legs, and body trunk do not have the anastomoses, but the vessels that provide for the nutritive blood flow and the SVP are also innervated.

Central nervous system (CNS) control, not local metabolic control, regulates cutaneous blood flow, which is in contrast to local metabolic control for muscle blood flow. The CNS controls the intensity of skin blood flow in response to hot or cold conditions. Under hot conditions, the sympathetic drive from the hypothalamus abates. As a result, a large volume of hot arterial blood



enters the SVP, assisted by blood flow through the AVA in the hands, feet, ears, nose, and lips. Under cold conditions, the smooth muscle in the AVA constricts due to an increase in sympathetic drive from the hypothalamus. Now much less blood gets to the ears, hands, feet, nose, and lips. Arterioles in the skin circulation in other parts of the body also constrict and limit arterial blood flow into the SVP. Excess stimulation of the sympathetic nervous system through the hypothalamus or adrenal glands in response to cold conditions can seriously reduce blood flow to the skin, as with Raynaud's disease. Cold conditions can also cause changes in the blood that induces aggregation of various blood-borne compounds that lead to solid emboli that block circulation in various organs, including the skin, for example cold agglutinins and cryoglobulinaemia. At times, test subjects in altitude chambers and pilots in modern aircraft are cool, especially if they are inactive during the hypobaric exposure. The anastomoses plus arterioles that regulate nutritive blood flow can constrict under any stress that increases the circulating levels of epinephrine and norepinephrine from the adrenal medulla. Finally, there is also spinal cord reflex control over local skin circulation modulated through temperature sensors in the skin. Local heating or cooling of the skin results in a local change in skin blood flow. Only local cord control over skin blood flow remains when the brain is isolated from the cord.

It is easy to alter blood flow through the skin. The skin can blush or appear pale depending on your emotional state, temperature, or condition of the circulatory system. Fast flow leads to blush, red or pink skin due to engorgement of the SVP. Sluggish flow leading to reduced blood volume causes bluish to purple skin. Total constriction of arterioles that provide even nutritive flow or loss of flow to the arteries causes pale skin color, which reflects the color of the underlying collagen connective tissue. Therefore it is difficult to diagnose a problem in the skin based just on skin color. Mechanical force can induce several changes. The White Reaction is seen when a pointed object is lightly drawn over the skin. The line becomes pale in about 15 seconds. Precapillary sphincters are thought to constrict, thus allowing blood to drain from capillaries and small veins. The Triple Response is seen if the pointed object is firmly drawn over the skin. A red reaction occurs in about 10 seconds, leading to a wheal (local edema) in a few minutes, and finally a flare due to arteriolar dilation. The Triple Response is a normal response to injury.

## Description of Cutis Marmorata

Dorland's Illustrated Medical Dictionary<sup>16</sup> states that CM is a transient form of *livedo reticularis*, which can also occur as a normal response to cold. It is a vascular response caused by dilatation of the subpapillary venous plexus as a result of increased viscosity of the blood, changes in the blood vessels themselves that delay blood flow away from the skin, and clinically characterized by the presence of a reticular cyanotic cutaneous discoloration surrounding pale central areas involving the extremities and trunk, which become more intense on exposure to cold and may disappear on warming. The most specific description of CM is *livedo reticularis symptomatica*, i.e., CM associated with other disorders. Here the morphology is in association with and paralleling various disorders related to changes in blood viscosity, gaseous or solid embolization—for example thrombocytopenia and cryoglobulinemia, or disease of the blood vessel wall.

Our summary descriptions on the morphology of CM associated with hypobaric decompressions are excerpted from several sources<sup>4,5,17,18</sup>. The lesion appears as a distinctive purple to bluish-red patch with adjacent areas of pallor that produce the mottled appearance. The lesion is not raised above the surrounding skin, at least initially. It is often observed in areas of subcutaneous fat, such as the pectoral region, shoulders, chest, and upper abdomen. It is sometimes associated with pruritus, and with serious symptoms of DCS such as chokes and sudden collapse. The lesion often goes unnoticed during the altitude exposure. Skin discoloration usually is discovered only after the altitude exposure, while the person is changing clothes. CM may be difficult to detect in all but Caucasians. CM in aviators responds well to repressurization to site pressure and to hyperbaric treatment if caught early, but may take days to resolve deep tissue tenderness in the most severe cases<sup>4</sup>.

Two detailed descriptions of CM by Ferris<sup>4</sup> and Fryer<sup>5</sup> are offered. Ferris reports that the lesions begin in a small area as a pale, cyanotic mottling of the skin. In order of frequency, CM appears near pectoral regions, shoulders, chest, upper abdomen, forearms, and thighs. The small area spreads in an irregular fashion. Pale areas later change to an erythematous mottling, which become 1°C to 2°C warmer. There is mild to moderate pain and slight tenderness over the involved area. Palpation does not reveal any crepitus. The lesion appears related to subcutaneous fat deposits. There is no anatomic distribution along blood vessels or peripheral nerves nor does

it suggest a cortical representation. After the return to site pressure, there is tenderness in 4 to 6 hours; after 24 hours, the area becomes tender to deep palpation and may take 2 or 3 days to clear. Fryer<sup>5</sup> documented three cases of skin bends, and then described CM in detail as itchy, purple blotches, not raised above the surrounding skin. There is tenderness of the underlying skin to touch, sharply localized and often acute. CM is common over the chest in established chokes with bluish-red patches that evolve into wheals if left long enough. Blood is still within the circulatory vessels since pressing the purple patch causes the color to fade, but it returns on release of pressure. Also, injection of adrenaline caused rapid and unequivocal blanching, and arteriolar and other vessels with smooth muscle retained their reactivity.

### **Incidence of Altitude-Induced Cutis Marmorata**

CM occurred one or more times in 23 of 49 subjects exposed to 3.46 psia (10,668 meters, or 35,000 feet) over the course of 796 altitude exposures<sup>4</sup>. Susceptible subjects tend to reacquire the lesion on repeated exposures. Older and obese subjects showed CM more often than younger and less obese subjects. CM appears often in conjunction with chokes, and precedes chokes. In tests that included exercise, symptoms of DCS occur first, and then CM appears. In tests without exercise, CM appears closer to the time of the DCS. Adler<sup>17</sup> notes, "It is of interest that mottling of the skin occurred in 8.3% of 314 cases of neurocirculatory collapse at altitude." Ryles and Pilmanis<sup>19</sup> recently published statistics about CM documented in the Brooks AFB Hypobaric DCS Database. Eleven cases of skin bends were discussed in a review of 447 cases of DCS. CM appeared seven times, three times without other signs or symptoms. The authors stress that their database has information on the initial signs and symptoms of DCS since their policy is to stop a test when DCS is first diagnosed. Therefore, 1.5% (7/447) of their DCS cases initially presented as CM. A 2001 review of the database by Pilmanis and Webb (personal communication) showed 1047 cases of DCS in 2762 exposures, with 57 cases presenting with skin manifestations. Their database lists four skin manifestations: urticaria (raised rash and itch), erythema (red rash, not raised), pruritus (itching), and CM (mottling). Of the 57 cases, 31 (3% of total DCS cases) were categorized as CM, and cleared with ground level oxygen, or hyperbaric treatment, or both. A 2000 review by Conkin of 549 altitude exposures documented in the JSC Hypobaric DCS Database uncovered 3 cases of CM in 85 cases (3.5%) of DCS, which are documented in this

communication. Finally, the most recent case of CM was reported in a U-2 pilot on two separate occasions<sup>20</sup>.

## Case Descriptions of Cutis Marmorata

We selected the following seven cases from the Brooks AFB and JSC Hypobaric DCS Databases to document that CM occurs under a range of experimental conditions. Cases 1–4 are from Brooks AFB, and 5–7 are from JSC. The descriptions include information about bubbles, called venous gas emboli (VGE), detected in the pulmonary artery or right heart using noninvasive Doppler ultrasound bubble detectors or echocardiography. The Spencer<sup>21</sup> five-point (0–IV) scheme was used to assign a bubble grade based on the audio or video signal from the detector. A trained observer assigned a VGE grade during multiple monitoring periods. All subjects were physically fit to participate in research tests, having passed the equivalent of a Class III Air Force Flight Physical. The body fat for males was computed from height, weight, and age data<sup>22</sup>, or from skin fold measurement from three sites. Body Mass Index (BMI) was computed as weight (kgs)/ht<sup>2</sup> (m).

---

### ***CASE #1 (Air Force Database ID# 2000001)***

A 37 yo Caucasian male, 68.2 kg, 173 cm, with 20.4% computed body fat from skin fold and 22.8 BMI, participated in an altitude exposure at Brooks AFB. The subject had two previous altitude exposures as a research subject, with the last exposure 42 days earlier. The subject initially performed 10 min of dual-cycle ergometry at 75% of maximum O<sub>2</sub> consumption at the beginning of a 100% O<sub>2</sub> prebreathe, followed by 15 min of rest, and then an 18 min ascent to 7.34 psia. The subject remained at 7.34 psia for 240 min while breathing 100% O<sub>2</sub>. At 213 min, the subject reported a “pins and needles” sensation (like an insect bite) on the lower portion of his left leg. He stated that it lasted a second or two and that he had experienced it two to three times in the previous 20 min period. Due to the fleeting nature of this report, the exposure was continued. Ascent from 7.34 to 3.46 psia took 17 min. At 3.46 psia, the subject performed three 4-min upper body exercises every 16 min while in a semi-recumbent position. Skin mottling was observed on the left upper chest 124 min into the exposure at 3.46 psia. The area was an irregular purple discoloration about 10 cm in diameter (estimated from a photo).

At this point, the subject had been breathing 100% O<sub>2</sub> for 424 min. The subject was unaware of the mottling until told of it, and there was no raised tissue in the area of the mottling. There were no VGE observed in a four-chamber Doppler echocardiogram of the heart prior to terminating the test. After discovery of the mottling, the subject was questioned about his awareness of other symptoms. The subject reported he had felt a slight "all over" tingling sensation while at 3.46 psia. It was strongest in the lower extremities (entire right and left leg). The tingling sensation resolved at 6.9 psia during repressurization of the chamber. Also during repressurization, the mottled area shrank to about 5 cm in diameter and the color went from purple to pink.

On further examination of the torso at site pressure, a pink area on the abdomen was discovered (also about 5 cm in diameter). The subject remained on 100% O<sub>2</sub> and Hyperbaric Medicine was consulted. The subject was treated with a United States Navy Treatment Table V (USN TT V). The mottling was almost gone at the start of the repressurization and resolved completely soon after. After the USN TT V, the subject was examined, released, and a follow up examination the next morning showed no residual symptoms. The subject returned to his normal duty. NOTE: In the report from Hyperbaric Medicine, the affected areas measured 7 x 6 cm (left pectoral) and 6 x 3 cm (right upper abdomen) at the time of the postflight examination.

---

---

### ***CASE #2 (Air Force Database ID# 2000003)***

A 23 yo Caucasian female, 74.5 kg, 173 cm, with 29.9% computed body fat from skin fold and 25.2 BMI, participated in an altitude exposure at Brooks AFB. The subject had two previous altitude exposures as a research subject, with the last exposure 21 days earlier. The subject initially performed 10 min of dual-cycle ergometry at 75% of maximum O<sub>2</sub> consumption at the beginning of a 100% O<sub>2</sub> prebreathe. This was followed by an additional 255 min of prebreathe prior to a 35 min ascent to 3.46 psia. At altitude, the subject performed various upper body exercises as in Case #1. Ninety-seven min into the exposure, the subject reported a constant "pins and needles", tingling sensation in both arms (entire) and both legs (entire) and in the chest and abdominal regions. No VGE had been observed in a four-chamber Doppler echocardiogram of the heart during the exposure. All reported symptoms resolved during repressurization at 4.8 psia.

During a visual examination at site pressure immediately following the exposure, a small pink area (erythematous) was observed on the left side of the chest. A diagnosis of skin mottling was made at site pressure. After a medical consult, it was determined that the subject should remain on 100% O<sub>2</sub> for 120 min postexposure.

The subject was asymptomatic during postbreathe and was released after a postflight briefing and examination.

---

***CASE #3 (Air Force Database ID# 2000038)***

A 23 yo Caucasian female, 51.6 kg, 165 cm, with 18.4% computed body fat from skin fold and 18.9 BMI, participated in an altitude exposure at Brooks AFB. The subject had two previous altitude exposures as a research subject, with the last exposure 51 days earlier. The subject completed a resting 90 min 100% O<sub>2</sub> prebreathe followed by an 8 min ascent to 2.73 psia. At altitude, the subject rested in a semi-recumbent position except for performing joint flexion of each limb at 10 min intervals to improve VGE detection during the exposure. Twenty-four min into the exposure, the subject reported a slight intermittent pain in the arch of her left foot (a 2 on a scale of 1 to 10—a 10 being the most severe pain ever experienced by the subject). Three min later, the pain became constant, moved into her entire foot, and was reported as a 3 on the same scale. Grade I VGE was observed in a four-chamber Doppler echocardiogram of the heart 11 min into the exposure, while Grades II and III VGE were observed 26 min into the exposure. All pain resolved during repressurization at 3.46 psia. During repressurization to 6.2 psia skin mottling was noticed on the left shoulder and upper chest of the subject. Skin mottling was diagnosed 2 min into repressurization after being exposed 27 min at 2.73 psia. Skin mottling remained visible at site pressure. After consulting with Hyperbaric Medicine, it was determined that the subject remain on 100% O<sub>2</sub> for 120 min postexposure. All mottling cleared approximately 10 min after reaching site pressure. The subject was asymptomatic during postbreathe and was released after a postflight briefing and examination.

---

***CASE #4 (Air Force Database ID# 2000044)***

A 22 yo Caucasian male, 86.6 kg, 186 cm, 16.7% body fat computed from Reference 22 data and 25.0 BMI, participated in an altitude exposure at Brooks AFB. The subject had no previous altitude exposure as a research subject. The subject completed a resting 60 min 100% O<sub>2</sub> prebreathe followed by a 6 min ascent to 4.37 psia. At altitude, the subject performed three, 4-min upper body exercises each 16 min and walked less than 10 steps between the each of the four exercise stations and the VGE monitoring station. Forty min into the exposure, the subject reported constant pain in his right shoulder (a 1 on a scale of 1 to 10—a 10 being the most severe pain ever experienced by the subject). Grades I and III VGE were observed

in a four-chamber Doppler echocardiogram of the heart 23 min into the exposure, while Grades III and IV VGE were observed at the onset of symptoms and repressurization. All right shoulder pain resolved during repressurization at 8.46 psia. During repressurization to 9.7 psia, skin mottling was noticed on the right shoulder of the subject. Skin mottling was diagnosed during the repressurization to site pressure. When questioned, the subject stated that he had noticed a "warm itchy" sensation (like a mild sunburn) on his right shoulder during descent (in the same area that the mottling was observed). At site pressure, the "warm itchy" feeling was gone but the mottling was still visible. After consulting with Hyperbaric Medicine, the standard 120 min 100% O<sub>2</sub> postbreathe was recommended. After 30 min into the postbreathe, the mottling had faded 50% but the area was still mildly swollen and hot, therefore Hyperbaric Medicine initiated a USN TT V treatment dive. The mottling completely resolved 10 min into the treatment. After the USN TT V, the subject was examined, released, and a follow up examination the next morning showed no residual symptoms. The subject returned to his normal duty. NOTE: In the report from Hyperbaric Medicine, the affected area measured 6x10 cm (right shoulder) at the time of the postflight examination and was described as a "bright red rash over entire superior shoulder area."

---

#### ***Case #5 (NASA Database ID# 1802)***

A 33 yo Hispanic male, 62.6 kg, 167 cm, with 15% computed body fat from Reference 22 data and 22.4 BMI, participated in an altitude exposure at JSC. The subject had one previous altitude exposure as a research subject to evaluate the effectiveness of a staged decompression protocol to prevent DCS during extravehicular activity from the Space Shuttle. A brief description of the first test is warranted. The subject ascended to 10.2 psia in about 2 min, and the chamber atmosphere was enriched to 26.5% O<sub>2</sub>. There was minimal physical activity, including sleep, during the 12 hr exposure. A 90 min O<sub>2</sub> prebreathe with a 4 min ascent preceded a 3 hr exposure to 4.3 psia. Exercise stressed the lower body since 4 min were spent flexing the ankle, knee, and hip joints by rhythmically stepping onto a 18.4 cm step once every 10 sec. This was followed by 4 min of flexing the wrist, elbow, shoulder joints by rhythmically lifting a 1.36 kg weight alternately every 5 sec from left to right hand. Finally, there was a 4 min period of rest and a 4 min period of bubble monitoring with the subject asked to flex each limb in turn while in a supine position. A Doppler Technician trained to detect the blood flow signal in the pulmonary artery provided bubble monitoring, at the precordial position, using an ultrasound Doppler bubble detector. The subject ambulated to the two exercise stations within the chamber. Grade IV VGE were detected 87 min into the test after

flexing the right leg, and again at 101 min when the right or left leg was flexed. The subject reported pain in the right knee at 116 min, and the test was aborted at 118 min for an unrelated reason. The pain in the right knee cleared at 7.3 psia during the repressurization to site pressure. Several changes were made to the staged decompression protocol, and the subject was willing to participate again.

Five months later, the subject again ascended to 10.2 psia in about 5 min, and the chamber atmosphere was once again enriched to 26.5% O<sub>2</sub>. There was minimal physical activity, including sleep, during the 12 hr exposure. A 40 min O<sub>2</sub> prebreathe with a 25 min ascent preceded a 4 hr exposure to 4.3 psia. Exercise stressed the upper body since 4 min were spent flexing the wrist, elbow, and shoulder joints while rhythmically rotating the wheel of a bicycle ergometer against a set resistance from a standing position, 4 min torquing fixed bolts with either the left or right hand from a standing position, and 4 min of rhythmically pulling against a set resistance from a seated position. Additional details about the exercises are available<sup>23</sup>.

Finally, there was a 4 min period of rest and a 4 min period of bubble monitoring with the subject asked to flex each limb in turn while in a supine position. The subject ambulated to the three exercise stations within the chamber. Grade I VGE was detected 1 min into the test after flexing the right leg. Grade IV VGE were detected at 17 min after flexing the right leg. Grade IV VGE was detected from all limbs at 52 min and at 92 min. The subject reported pain in the right knee after 57 min. At 103 min, the subject reported sudden onset of fatigue, and cold sweat. At the same time, red and white mottling or marbling appeared on the chest. Skin mottling was diagnosed 103 min into the exposure. The accumulation and rapid onset of signs and symptoms initiated the removal of the subject through a smaller transfer airlock at 115 min. Pain and feeling of fatigue cleared at 7.2 psia. Mottling disappeared in 10 min at site pressure on 100% O<sub>2</sub>. The subject was held in a horizontal position while on 100% O<sub>2</sub> for 2 hr and was under medical observation in a hyperbaric chamber overnight. There were no further symptoms or indication of neurological deficit.

---

---

#### ***Case #6 (NASA Database ID# 14901)***

A 40 yo Caucasian male, 80.9 kg, 174 cm, with 21% computed body fat from Reference 22 data and 26.7 BMI, participated in an altitude exposure at JSC. The subject had no previous altitude exposure as a research subject. The subject ascended to 6.5 psia for a 3 hr exposure while breathing 100% O<sub>2</sub> through a mask. Prior to the ascent, there was a brief ear and sinus check done by depressurizing the chamber atmosphere to the equivalent of 6,000 ft altitude in about one min (5,000 ft/min). The subject breathed air during this check, which took approximately



5 min for all subjects to be evaluated, primarily during the repressurization back to site pressure. The medical technician exited the chamber and an ascent on air to 10 psia at 6,500 ft/min was begun 6 min from the start of the initial ascent. About 2 min later the subject donned his O<sub>2</sub> mask at 10 psia and the chamber continued the ascent to 6.5 psia at 6,500 ft/min. The ascent time to 6.5 psia was 12 min with the subject breathing 100% O<sub>2</sub> for 10 min. Exercise stressed the upper body since 4 min were spent flexing the wrist, elbow, and shoulder joints while rhythmically rotating the wheel of a bicycle ergometer against a set resistance from a standing position, 4 min torquing fixed bolts with either the left or right hand from a standing position, and 4 min of rhythmically pulling against a set resistance from a seated position. The details of these exercises are available<sup>23</sup>.

Finally, there was a 4 min period of rest and a 4 min period of bubble monitoring with the subject asked to flex each limb in turn while in a supine position. The subject ambulated to the three exercise stations within the chamber. During the third VGE measurement period, at 45 min into the exposure, Grade III VGE were detected when the left leg was flexed. Grade IV VGE was detected from the left and right legs at 77, 92, and 108 min. The bubble signals were more intense during the 92 and 108 min times and were assigned a Grade IV+. Between 108 and 120 min, the subject described irritation and itching on the chest. There was blue and red marbling on the right side of the chest. Skin mottling was diagnosed 120 min into the exposure. The subject was removed through a transfer airlock at 126 min. Rash and mottling reduced on descent, with mild redness at site pressure. The subject was treated on a USN TT V, and the mottling resolved before the treatment ended.

---

---

#### ***Case #7 (NASA Database ID# 18201)***

A 52 yo Caucasian male, 80.6 kg, 179 cm, with 21% computed body fat from skinfold and 25 BMI, participated in an altitude exposure at JSC. The subject had no previous altitude exposure as a research subject. The subject ascended to 6.5 psia for a 3 hr exposure while breathing 100% O<sub>2</sub> through a mask. Prior to the ascent, there was a brief ear and sinus check done as described in Case #6. The ascent time to 6.5 psia was 12 min with the subject breathing 100% O<sub>2</sub> for 10 min. The subject was under strict bed rest conditions for three days prior to the ascent to simulate adaptation to microgravity. The subject stayed in a supine position during the altitude exposure. Exercise stressed the upper body, since 4 min were spent flexing the wrist, elbow, and shoulder joints while rhythmically rotating the wheel of an arm ergometer against a set resistance from a supine, 4 min torquing fixed bolts with either the left or right hand from a supine position, and 4 min of rhythmically pulling

against a set resistance from a supine position. The details of these exercises are available<sup>24</sup>.

Finally, there was a 4 min period of rest and a 4 min period of bubble monitoring with the subject asked to flex each limb in turn while in a supine position. The subject reported itching and burning across the chest (2 out of 10 from a discomfort scale) and axilla at 113 min into the exposure. The medical officer suspected contact dermatitis. At the second hour questioning period, the subject reported no problems other than the mild skin irritation. At 136 min, the Doppler Technician reported an increased size of the redness on the abdomen. The subject no longer reported itching, but reported that the areas felt hot. All agreed to monitor subject closely, but to continue the test. At 148 min, the Doppler Technician reported that the sizes of the patches had increased on the abdomen, with whitening of certain areas. No bubbles were detected from a precordial position using a 2 mHz Doppler probe, and since the symptoms were limited to slight burning, the decision was made to finish the test. However, the subject displayed a Doppler blood flow signal during the test that was different from that normally encountered in hypo- or hyperbaric decompressions. Normally, the presence of individual gas bubbles can be heard in the flow signal, but in this case, individual bubble signals were absent. Instead, when the limb movement maneuvers occurred, the intensity of the flow sound increased.

Our opinion is that this is indicative of an increased number of scattering sites; the absence of individual, audible bubbles would indicate that these were microbubbles. The best diagnosis at the time was still contact dermatitis. At the third (and last) hr questioning period, the subject reported that the skin irritation around the stomach was no worse than earlier. At site pressure, 189 min from start of exercise at 6.5 psia, the Doppler Technician reported that there was no change in the skin colors. The subject was allowed to remove his O<sub>2</sub> mask. A series of photographs were taken of the torso following the return to site pressure (exact time is unavailable).

The posttest comments in the logbook stated that the subject had minimal mottling on the return to site pressure. The subject also experienced postural hypotension and dizziness on standing, and it persisted after he left the chamber area. A decision was made to treat the subject on a USN TT V about 4.5 hr after the return to site pressure, at which time a rash was still evident. The treatment lasted 90 min, with no extensions since the dizziness was judged to have diminished. The subject was held for observation through the night. At 9:00 p.m., the rash was still evident. At 6:30 a.m. the following day, the rash was reported as almost cleared on the lower abdomen, and greatly diminished in the left axilla. The postural hypotension

confounds a proper characterization of DCS since prolonged bed rest was part of the study design.

---

What is remarkable about these seven cases is that nothing remarkable stands out as a common factor associated with the lesion. CM occurred in otherwise healthy and fit men and women from 22 to 52 years of age. CM occurred after extensive (case #1,2,3,5) or limited (case #4,6,7) prebreathe, and was observed with (case #3,4,5,6) and without (case #1,2,7) bubbles detected in the venous circulation. Case #7 (see Fig. 1) was unusual in this regard since the “typical” Doppler ultrasound bubble signals were not present. Case #5 is notable in that VGE were detected with right leg flexion at the beginning of the altitude exposure and the intensity of the bubble signal quickly reached a Grade IV classification (also see case #6), with the coincidental report of pain in the right knee, then mottling, and the onset of sudden fatigue and cold sweat. It appears that the entire body was reacting to the decompression insult, and the skin is a substantial organ of the body. Case #1 is in contrast to case #5 in that no VGE were detected and reports of tingling sensations in the legs were offered only after CM was observed. The chest and abdomen were the dominant locations for the lesion, but case #3 and #4 had CM restricted to one shoulder. CM was observed with (case #2,3,4,5) and without (case #1,6,7) other symptoms, but in all cases except #5 and #7 the tests were terminated once any DCS was diagnosed. Finally, all cases of CM and other symptoms rapidly improved on return to site pressure, or shortly thereafter. Hyperbaric treatment was used in cases #1,4,6, and 7. It is important to note that this was to treat the CM and no other residual symptoms in all but case #7. It can be argued that postural hypotension in case #7 was a residual symptom of DCS. But a lengthy period of bed rest before and during the test may have caused the persistent postural hypotension.


Figure 1 presents four views from case #7, taken shortly after (exact time not available) the return to site pressure. A USN TT V treatment, which was provided to improve the persistent report of dizziness and postural hypotension, was initiated 4.5 hours after the return to site pressure. The patchy discoloration of the abdomen and along the left axilla, left biceps near the elbow, and small area near the right axilla attest to an extensive involvement of the skin. The skin around the groin, buttocks, thighs, legs, and back was not affected. The additional time (approximately 67 min) after the first report of itching and burning across the chest and axilla to

the start of descent contributed to the evolution of the lesions. The rash did not appreciably clear during the hyperbaric treatment, but resolved over a 24-hour observation period. Although extensive, we feel the most likely explanation for the lesions is local embolic events in or near the cutaneous circulation. The secondary and persistent reactions (the rash) were likely mediated through local biochemical changes initiated by hypoxic conditions in the tissues.

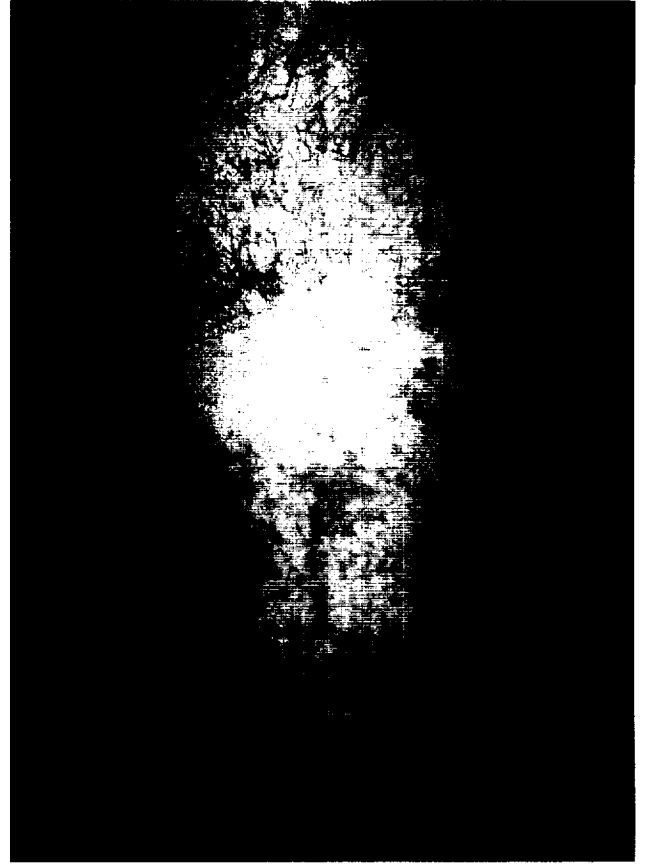
## **Pathophysiology of Cutis Marmorata**

For all the observation through the years in humans and animals, a clear understanding of the pathophysiology of CM has not emerged. One reason is that there is no ethical way to induce CM in humans due to the potential association with Type II DCS symptoms. A better understanding of the pathophysiology of CM would provide for better treatment approaches, better disposition of cases, and better documentation in the medical records. The absence of good data has resulted in a confusing array of classification and treatment schemes to manage CM in divers and aviators.

The skin, including subcutaneous fat, is a substantial organ (about 16% of body weight), and has a complex blood circulation, which responds to many conditions. Changes in skin color are of little diagnostic value. For example, the skin can blush in a hot environment or as a response to embarrassment, and without additional details one cannot identify the cause. Skin mottling is often observed as a response to mild cold exposure<sup>16</sup>, but this is not an embolic event. It is not yet possible to say that the skin is the origin of the gas emboli that lead to CM, or that the skin is the target for gas emboli that originate elsewhere. Wilmshurst<sup>25</sup> associated large right-to-left shunt through the atrial septum in divers as one cause of cutaneous DCS, including CM. However, he cannot attribute all cases to this mechanism and included microbubble transport through the lung circulation and autochthonous bubble formation as additional mechanisms for cutaneous DCS. Animal models may provide the best opportunity to understand mechanisms<sup>1,12,13</sup>.



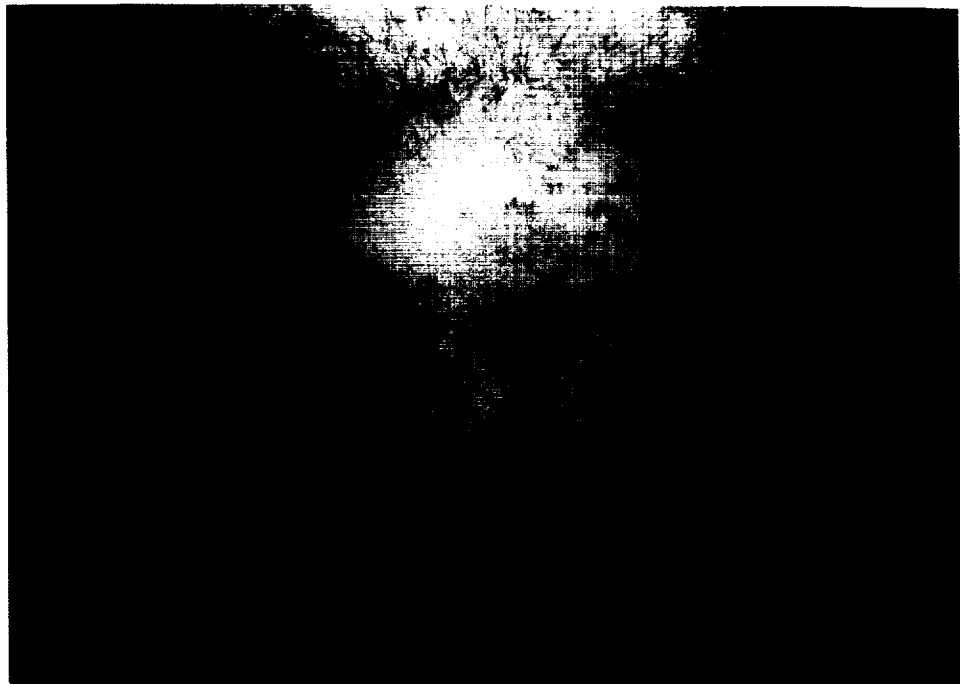
*Figure 1a*



*Figure 1b*



*Figure 1c*



*Figure 1d*

**Figure 1. Four views of Cutis Marmorata from case #7**

Ferris<sup>4</sup> concluded that CM indicates widespread tissue involvement, and more prebreathing reduces the likelihood of CM. He states that obstruction of terminal arterioles and venules is likely the cause of the lesion, and that an obstruction in a large artery would cause larger diffuse areas of pallor rather than mottling. He feels the transition from a pale (cool) to erythematous (warm) area is due to vasodilatation, similar to what is expected with reactive hyperemia. The deep tissue tenderness after the insult indicates that trauma to the underlying tissues has occurred. He states, "Although not conclusive, the indirect evidence cited above suggests that the mottled skin lesion is the result of intermittent transient spasm and secondary hyperemia of the superficial small vessels of the skin secondary to bubble formation and trauma to the deeper fatty layers of the skin."

A critical issue to resolve is whether CM is the result of a centrally mediated response, a systemic response, or a local reaction in the skin to gas emboli. We could find no information that trauma to the CNS leads to CM. Therefore, we do not believe that gas emboli within the CNS are expressed as CM. There are several cases of CM associated with neurocirculatory collapse, which suggests a systemic response to gas emboli is the mechanism. The mechanism might be through a cascade of biochemical reactions in response to gas emboli, or participation of the endocrine system as a generalized stress response. However, we find no description of CM-like morphology under "fight-or-flight" conditions; conditions where these stress hormones are at increased concentrations. It is important to note that only 4 of the 17 fatalities described by Fryer<sup>5</sup> had mottling as one of the signs of DCS. We do find information that solid emboli in the cutaneous circulation will cause CM<sup>16</sup>, and that gas emboli in the arterial and venous circulation of the skin will cause CM<sup>1,10,25-28</sup>.

Durant<sup>28</sup> described a case of arterial embolization where the person reported feeling "funny" and dizzy. Marbling of the skin was noted, and he states, "this interesting dermal manifestation is presumably due to embolism of the skin vessels, and is noted especially over those portions of the body that are superiorly located." Duff<sup>26</sup> infused the hand with air injected into the brachial artery. The skin showed patchy mottling, with red, white, and blue areas. Skin color changes due to arterial embolization by gas infusion do not have associated pain or itching, and are short-lived compared to CM caused by gas supersaturation. CM associated with superficial isobaric gas counterdiffusion also supports a mechanism of local circulatory insult<sup>1,8,10</sup>. Differences in the type and frequency of skin bends that present after "dry" and "wet" dives are also helpful to

understand the mechanism of CM. It was observed<sup>18</sup> that skin bends in dry-dives (exposures in a chamber or dry suit with gas surrounding the body) are more likely than wet-dives (exposure where water is in contact with the skin). The conclusion was that an excess of inert gas due to transcutaneous diffusion of gas during a dry-dive transformed into bubbles in the skin during the decompression, resulting in itching and rash. CM observed after wet-dives was attributed to embolic events in terminal arterioles and venules of the cutaneous circulation.

A swine model to study neurological DCS also appears to be useful to study skin lesions<sup>1,12,13</sup>. Buttolph<sup>13</sup> presents the most detailed histological evidence of CM. His first mention of a swine model to study neurological DCS also included a description of skin lesions associated with that model<sup>12</sup>. Here is the classic association between the skin lesion and neurological symptoms, now seen in an animal model. But association does not prove causation. Pigs with neurological symptoms had CM earlier (9.5 min) compared to CM in pigs with no neurological symptoms (17.9 min)<sup>13</sup>. The five pigs with no skin lesions were all unaffected by neurological DCS. Buttolph<sup>13</sup> suggests that CM is a local skin response to bubbles, either intra- or extravascular, or some biochemical product initiated by bubbles. His important contribution was to describe the lesion at the histological level. The violaceous color is due to congestion of deeper vessels in the dermis and subcutis with histopathology consistent with that seen in ischemia-reperfusion injury. The lesion was described as vasculitis.

## **Categorization of Cutis Marmorata**

It is impractical to cover the many issues related to categorization of DCS signs and symptoms in this communication. However, we will discuss the subject as it relates to a recent review about the categorization of CM at JSC. During World War II, aviator skin bends had a category all to itself<sup>4,17,29</sup>, separate from Type I and Type II DCS. With the exception of Adler<sup>17</sup>, CM was not categorized as Type II in diving or aviation<sup>3-5,30,31</sup>. Table I shows that the majority of opinions, both published and from personal communications, are not to categorize CM as Type II DCS. Many sources preferred to include CM as Type I DCS. A substantial number preferred not to classify CM at all, or to even provide a separate category just for cutaneous DCS. The current trend is to not categorize any sign or symptom<sup>19,32,33</sup>, and to treat each case as a unique event. However, CM is often, but not always, associated with stressful decompression



profiles and other serious signs and symptoms of DCS in humans<sup>11,18,19,31,34</sup>, and also in a swine model of neurological DCS<sup>12,13</sup>. Many say that CM is a “harbinger of doom” but, by itself, it is not a life-threatening condition. This empirical experience has caused CM to be treated as Type II DCS, even if it is not.

Placing a sign or symptom of hypobaric DCS into Type I or Type II DCS is artificial and causes problems if a sign or symptom does not conveniently fit into one or the other category<sup>32</sup>. The problem is acute when we attempt to categorize CM from a hypobaric exposure into Type I or Type II DCS. A categorization scheme only lends itself to quick and effective treatment strategies if the categorization is specific. CM does not lend itself to a specific category. CM was initially categorized as Type II DCS at JSC, based on the best medical advice at the time. CM was supposedly initiated by a disturbance within the CNS, or a whole-body systemic response linked to a large volume of evolved gas. Therefore, a proper clinical response was to initially treat with a USN TT V, even when no other symptoms were present. The aggressive treatment of CM resulted from an ignorance of the pathophysiology, and the observation that CM may be associated with serious Type II symptoms. In essence, hyperbaric treatment was provided to affect a serious symptom not yet expressed. The clinical response cannot be used as evidence that CM requires a Type II treatment protocol, but this practice only adds to the confusion about the true risk associated with just CM. There is no cause-and-effect relationship yet established that CM is a systemic response to a large bubble load, or a response mediated by damage to the CNS, which would be a rationale to provide a prophylactic hyperbaric treatment.

There are consequences to the misclassification of an illness. As a result, the United States Air Force no longer uses the terms Type I or Type II DCS. As recently as 1999, research subjects, aviators, or astronauts at JSC with CM would be documented to have Type II in their medical records, which could impact their careers. The JSC Institutional Review Board will not allow a research subject to participate in additional altitude tests if Type II DCS is ever diagnosed. The test of a promising prebreathe procedure would be discontinued if there were a case of Type II DCS. The return-to-duty or return-to-flight status depends on the existing JSC regulations about Type II DCS. There are also risks and costs associated with a hyperbaric treatment, so the rationale must be sound to initiate a treatment. After an extensive review of information about CM, all skin bends at JSC except CM are now categorized as Type I DCS, with CM categorized as a unique entity, but not as Type II DCS.

**Table I: Published and Personal Opinions About the Categorization of Cutis Marmorata**

<b>Source</b>	<b>Reference</b>	<b>Year</b>	<b>CM as Type II DCS</b>
Buttolph	*	1998	no
Pilmanis	*	1998	no
Waligora	*	1998	**
Norfleet	*	1999	**
Broome	12	1996	**
Arthur	29	1982	**
Hallenbeck	34	1982	**
Elliott	3	1982	no
Davis	11	1977	no
Hills	7	1977	no
Dennison	18	1971	no
Kidd	30	1969	no
Fryer	5	1969	no
Adler	17	1964	yes
Ferris	4	1951	no
Whitton	31	1992	no
Morris	35	1983	no
Katuntsev	*	1999	yes
Conkin	15	1999	no
Ryles	19	1996	**
Heimbach	6	1996	**
Flynn	*	1999	no
Collier	14	2000	no
Zwart	33	2000	**

\* From personal communication.

\*\* Indicated that categorization of CM was inappropriate, but that the association between CM and serious signs and symptoms of DCS should not be ignored.

## Treatment of Cutis Marmorata

The treatment of DCS is more an art than a science, and no single treatment can cover all situations. The physician will match treatment resources and best clinical judgment on a case-by-case basis. Our literature review and discussions with experts about CM treatment uncovered a wide range of options, depending on the situation, from simple monitoring of the recovery process to aggressive hyperbaric treatment with a USN TT VI. Davis<sup>11</sup> concluded that an aviator presenting with CM should be hospitalized for 24 hours and carefully observed for vasomotor instability or neurological manifestations, which would necessitate hyperbaric therapy. Whitton<sup>31</sup> states that hyperbaric treatment, or at least medical monitoring, is advised. If skin symptoms occur during flight, then immediate descent is required and the crewmember should see a Flight Surgeon. For divers, mild cases of CM are often untreated<sup>3,14</sup>, while others recommend the USN TT VI<sup>29</sup>. The USN Diving Manual (Rev. 4) categorizes CM as Type I DCS, but requires treatment with USN TT VI. The rationale is that CM may precede a symptom of serious DCS (personal communication with Dr. Edward Flynn). Hyperbaric treatment with USN TT V or VI and breathing 100% O<sub>2</sub> are the most effective interventions for CM<sup>33</sup>. It is difficult to justify lesser treatments if these options are available, certainly for divers. But recently, two hours of ground level oxygen was shown to be effective in some cases of hypobaric DCS<sup>36,37</sup> since the prompt return to site pressure is a significant increase in pressure to shrink bubbles.

## Conclusions and Recommendations

We conclude that the historical case descriptions<sup>4,5,17,26,28</sup>, recent animal research<sup>1,12,13</sup>, observations about the differences between skin bends in wet and dry dives<sup>18</sup>, observations with isobaric gas switching at depth<sup>1,8,10</sup>, and the case descriptions in this communication all implicate a local embolic insult to the skin circulation as the cause of CM. The observation that arterial embolization of the hand from gas in the brachial artery<sup>26,27</sup>, or introduced from other sources<sup>25,28</sup> can produce CM-like morphology supports our conclusion that gaseous emboli within the skin circulation can produce different shades of the red, white, and blue that are characteristic of CM. There is congestion of the circulation, and an inflammatory response as the insult progresses. The damage is similar to that seen in ischemia-reperfusion in other tissues. The color changes

are due to changes in blood flow, and the histological changes are due to secondary responses to the presence of the bubbles, which could be mediated through biochemical changes in the blood and tissues.

Our conclusions and recommendations about CM from hypobaric decompressions are based on the “weight of evidence” after a review of evidence and consultation with experts on DCS treatment. The indirect evidence indicates that CM is a manifestation of a local embolic insult within the cutaneous circulation, not an indication of an embolic event within the CNS. It is unclear whether CM is a consequence of a systemic response to gas emboli, much like the “hives” are a consequence of a systemic histamine release. A local release of histamine in response to cold-water contact on the skin is responsible for urticaria in sensitive individuals<sup>2</sup>. The presence of CM likely indicates significant intravascular gas embolization, although a few intra- or extravascular gas bubbles localized in the skin might produce the same effect. The evidence is unclear as to whether the arterial or venous circulation is compromised. We postulate that bubbles trapped in or near the extensive SVP could produce the full range of morphology attributed to CM. It is clear that other local embolic events within the cutaneous circulation cause CM-like morphology (see *livedo reticularis*). It is unclear whether the skin is the source of gas emboli, or is the target organ for gas emboli. The consensus of published opinion is to not categorize CM as Type II DCS, but the potential association between CM and serious DCS cannot be ignored. The association between Type II symptoms, such as chokes, sudden fatigue, collapse, disturbances in motor and sensory pathways, and CM is coincidental with both developing along the same time course.

We agree with others (see Table I) that CM not be categorized as Type II DCS, but as Type I, or given a separate category, or not categorized at all. Categorizing CM as Type II DCS when it is the only sign or symptom of DCS has a profound impact on the treatment options, and can adversely affect the career of the person. Occluding cutaneous circulation, either nutritive or thermoregulatory circulation, is undesirable, but for the short-term is not life threatening. Clinicians will always use their best judgment for treatment on a case-by-case basis<sup>33</sup>. Some recommendations are: a) immediate descent to site pressure once CM is recognized; b) if CM resolves at altitude, or if CM resolves within minutes at site pressure, then 2 hours of ground level oxygen is given with a medical monitor provided, plus follow-up consultation the next day; and c) if CM is unresolved during descent and is present with initial ground level oxygen, then

treat with a USN TT V or VI, plus follow-up consultation the next day. Finally, additional research, certainly in animals, is needed to understand more about the exact cause(s) of CM. A 1969 statement by Fryer<sup>5</sup> still applies today: “No fully satisfactory explanation has been established for the full range of skin manifestations which have been observed.”

## References

- <sup>1</sup> Lambertsen CJ. Relations of isobaric gas counterdiffusion and decompression gas lesion diseases. In: The physiological basis of decompression. Vann RD. ed. Bethesda: Undersea and Hyperbaric Medical Society, Inc., 1989; 87-103.
- <sup>2</sup> Edmonds C, Lowry C, Pennefather J. Diving and subaquatic medicine (second edition). Australia: Diving Medical Center, 1981; 150-151, 409.
- <sup>3</sup> Elliott DH, Kindwall EP. Manifestation of decompression disorders. In: The physiology and medicine of diving (third edition). Bennett PB, Elliott DH. eds. London: Bailliere, Tindall and Cassell, 1982; 463-64.
- <sup>4</sup> Ferris EB Jr., Engel GL. The clinical nature of high altitude DCS. In: Fulton JF, Ed. DCS. Philadelphia, PA: WB Saunders, 1951; 35-37.
- <sup>5</sup> Fryer DI. Subatmospheric DCS in man. Slough, England: Engelhard Hanovia International, Ltd., 1969; 44-65.
- <sup>6</sup> Heimbach RD, Sheffield PJ. Decompression sickness and pulmonary overpressure accidents. In: Fundamental of aerospace medicine (second edition). DeHart RL, Ed. Baltimore, MD: Williams and Wilkins, 1996; 141.
- <sup>7</sup> Hills BA. Decompression sickness, Vol. 1. The biophysical basis of prevention and treatment. New York: John Wiley and Sons, 1977; 30-31.
- <sup>8</sup> Blenkarn GD, Aquadro C, Hills BA, Saltzman HA. Urticaria following the sequential breathing of various inert gases at a constant ambient pressure of 7 ATA: A possible manifestation of gas-induced osmosis. *Aviation Med* 1971; 42:141-46.
- <sup>9</sup> Cowley JRM, Allegra C, Lambertsen CJ. Subcutaneous tissue gas space pressure during superficial isobaric counterdiffusion. *J Appl Physiol* 1979; 47:224-27.
- <sup>10</sup> Lambertsen CJ, Idicula J. A new gas lesion syndrome in man, induced by "isobaric gas counterdiffusion." *J Appl Physiol* 1975; 39:434-43.

- <sup>11</sup> Davis JC, Sheffield PJ, Schuknecht L, Heimbach RD, Dunn JM, Douglas G, Anderson GK. Altitude DCS: hyperbaric therapy results in 145 cases. *Aviat Space Environ Med* 1977; 48:722-30.
- <sup>12</sup> Broome JR, et al. Neurological decompression illness in swine. *Aviat Space Environ Med* 1996; 67:207-13.
- <sup>13</sup> Buttolph TB, et al. Cutaneous lesions in swine after decompression: histopathology and ultrastructure. *Undersea Hyper Med* 1998; 25:115-21.
- <sup>14</sup> Collier WM. Classification of skin marbling as decompression sickness [Masters Thesis]. Daytona Beach, FL: Embry-Riddle Aeronautical University, 1999.
- <sup>15</sup> Conkin J. How should cutis marmorata be treated? *Aviat Space Environ Med* 1999; 70:939-40.
- <sup>16</sup> Dorland WA. *Dorland's illustrated medical dictionary* (27<sup>th</sup> edition). Philadelphia: W.B. Saunders Co., 1988; 948-49.
- <sup>17</sup> Adler HF. Dysbarism. Review 1-64, USAF School of Aerospace Medicine, Brooks AFB, 1964; 80-81.
- <sup>18</sup> Dennison WL Jr. A review of the pathogenesis of skin bends. NSMRL rep. No. 660. Groton, CT. Naval Submarine Medical Research Laboratory, 1971.
- <sup>19</sup> Ryles MT, Pilmanis AA. The initial signs and symptoms of altitude decompression sickness. *Aviat Space Environ Med* 1996; 67:983-89.
- <sup>20</sup> Hankins TC, Webb JT, Neddo GC, Pilmanis AA, Mehm WJ. Test and evaluation of exercise-enhanced preoxygenation in U-2 operations. *Aviat Space Environ Med* 2000; 71:822-6.
- <sup>21</sup> Spencer MP. Decompression limits for compressed air determined by ultrasonically detected blood bubbles. *J Appl Physiol* 1976; 40:229-35.
- <sup>22</sup> Dembert ML, Jekel JF, Mooney LW. Weight-height indices and percent body fat among U.S. Navy divers. *Aviat Space Environ Med* 1984; 55:391-95.

- <sup>23</sup> Conkin J, Waligora JM, Horrigan DJ Jr., Hadley AT III. The effect of exercise on venous gas emboli and decompression sickness in human subjects at 4.3 psia. NASA Technical Memorandum 58278. Houston: Johnson Space Center, 1987.
- <sup>24</sup> Loftin KC, Freeman-Perez S, Beene D, Hnatt L. Metabolic rate measurements comparing supine with upright upper-body exercises. NASA Contractor Report 4549. Houston: Johnson Space Center, 1993.
- <sup>25</sup> Wilmshurst PT, Pearson MJ, Walsh KP, Morrison WL, Brysons P. Relationship between right-to-left shunts and cutaneous decompression illness. *Clinical Science* 2001; 100:539-42.
- <sup>26</sup> Duff F, Greenfield ADM, Whelan RF. Vasodilation produced by experimental arterial gas embolism in man. *Lancet* (ii), 1953; 230-34.
- <sup>27</sup> Duff F, Greenfield ADM, Whelan RF. Observations on the mechanisms of vasodilation following arterial gas embolism. *Clin Science* 1954; 13:365-76.
- <sup>28</sup> Durant TM, Oppenheimer MJ, Webster MR, Long J. Arterial air embolism. *Am Heart J* 1949; 38:481-500.
- <sup>29</sup> Arthur DC, Margulies RA. The pathophysiology, presentation, and triage of altitude-related DCS associated with hypobaric chamber operation. *Aviat Space Environ Med* 1982; 53:489-94.
- <sup>30</sup> Kidd DJ, Elliott DH. Clinical manifestations and treatment of DCS in divers. In: *The physiology and medicine of diving and compressed-air work* (first edition). Bennett PB, Elliott DH. eds. London: Bailliere, Tindall and Cassell, 1969; 464-90.
- <sup>31</sup> Whitton RC (ed.). *Flight Surgeon's Guide* (Vol. 1). USAF School of Aerospace Medicine, Brooks AFB, TX, 1992; 3-10 to 3-11.
- <sup>32</sup> Francis TJR, Smith DJ (eds). Describing decompression illness. *Proceedings of the Forty-second Undersea and Hyperbaric Medical Society Workshop* 1991; 153.
- <sup>33</sup> Zwart BP. Treatment of cutis marmorata (Cutis). *Aviat Space Environ Med* 2000; 71:457.



- <sup>34</sup> Hallenbeck JM, Andersen JC. Pathogenesis of the decompression disorders. In: The physiology and medicine of diving (third edition). Bennett PB, Elliott DH. eds. London: Bailliere, Tindall and Cassell, 1982; 449.
- <sup>35</sup> Morris L (ed.). Hyperbaric Chamber Operations. Air Force Pamphlet 161-27, Department of the Air Force, Headquarters U.S. Air Force, Washington, DC, 1983; 63.
- <sup>36</sup> Dart TS, Buttler W. Towards new paradigms for the treatment of hypobaric decompression sickness. *Aviat Space Environ Med* 1998; 69:403-09.
- <sup>37</sup> Krause KM, Pilmanis AA. The effectiveness of ground level oxygen treatment for altitude decompression sickness in human research subjects. *Aviat Space Environ Med* 2000; 71:115-8.

REPORT DOCUMENTATION PAGE			Form Approved OMB No. 0704-0188	
Public reporting burden for this collection of information is estimated to average 1 hour per response, including the time for reviewing instructions, searching existing data sources, gathering and maintaining the data needed, and completing and reviewing the collection of information. Send comments regarding this burden estimate or any other aspect of this collection of information, including suggestions for reducing this burden, to Washington Headquarters Services, Directorate for Information Operations and Reports, 1215 Jefferson Davis Highway, Suite 1204, Arlington, VA 22202-4302, and to the Office of Management and Budget, Paperwork Reduction Project (0704-0188), Washington, DC 20503.				
1. AGENCY USE ONLY (Leave Blank)	2. REPORT DATE April 2002	3. REPORT TYPE AND DATES COVERED NASA Technical Paper		
4. TITLE AND SUBTITLE Case Descriptions and Observations About Cutis Marmorata From Hypobaric Decompressions			5. FUNDING NUMBERS	
6. AUTHOR(S) Johnny Conkin, Ph.D., M.S., Andrew A. Pilmanis, Ph.D., M.S.*, James T. Webb, Ph.D., M.S.**				
7. PERFORMING ORGANIZATION NAME(S) AND ADDRESS(ES) Lyndon B. Johnson Space Center Houston, Texas 77058			8. PERFORMING ORGANIZATION REPORT NUMBERS S-889	
9. SPONSORING/MONITORING AGENCY NAME(S) AND ADDRESS(ES) National Aeronautics and Space Administration Washington, DC 20546-0001			10. SPONSORING/MONITORING AGENCY REPORT NUMBER TP-2002-210779	
11. SUPPLEMENTARY NOTES *Air Force Research Laboratory, Brooks Air Force Base, TX **Wyle Life Sciences, Inc.				
12a. DISTRIBUTION/AVAILABILITY STATEMENT Available from the NASA Center for AeroSpace Information (CASI) 7121 Standard Hanover, MD 21076-1320 Subject Category 52			12b. DISTRIBUTION CODE	
13. ABSTRACT (Maximum 200 words) There is disagreement about the pathophysiology, classification, and treatment of cutis marmorata (CM), so there is disagreement about the disposition and medical status of a person that had CM. CM is rare, associated with stressful decompressions, and may be associated with serious signs and symptoms of decompression sickness (DCS). CM presents as purple or bluish-red skin mottling, often in the pectoral region, shoulders, chest, or upper abdomen. It is unethical to induce CM in humans so all information comes from retrospective analysis of case reports, or from animal models. A literature search, seven recent case reports from the Johnson Space Center and Brooks Air Force Base Hypobaric DCS Databases, interviews with DCS treatment experts, and responses to surveys provided the factual information used to arrive at our conclusions and recommendations. The "weight of evidence" indicates that CM is a local, not centrally mediated or systemic response to bubbles. It is unclear whether obstruction of arterial or venous blood flow is the primary insult since the lesion is reported under either condition. Any neurological or cardiovascular involvements are coincidental, developing along the same time course. The skin could be the source of the bubbles due to its mass, the associated layer of fat, and the variable nature of skin blood flow. CM should not be categorized as Type II DCS, should be included with other skin manifestations in a category called cutaneous DCS, and hyperbaric treatment is only needed if ground level oxygen is ineffective in the case of altitude-induced CM.				
14. SUBJECT TERMS aviator decompression sickness, skin mottling, skin bends, bubbles, skin lesion, cutaneous circulation			15. NUMBER OF PAGES 35	16. PRICE CODE
17. SECURITY CLASSIFICATION OF REPORT Unclassified	18. SECURITY CLASSIFICATION OF THIS PAGE Unclassified	19. SECURITY CLASSIFICATION OF ABSTRACT Unclassified	20. LIMITATION OF ABSTRACT Unlimited	