

# Right Ventricular Tissue Doppler Assessment in Space during Circulating Volume Modification using the Braslet-M Device

D.R. Hamilton<sup>a</sup>, A.E. Sargsyan<sup>a</sup>, E. M. Fincke<sup>b</sup>, S.H. Magnus<sup>b</sup>, Y.V. Lonchakov<sup>c</sup>, I.V. Alferova<sup>d</sup>,  
S.A. Dulchavsky<sup>e</sup>, D. Ebert<sup>a</sup>, K. Garcia<sup>a</sup>, D. Martin<sup>a</sup>, V.P. Matveev<sup>c</sup>, Y.I. Voronkov<sup>d</sup>, S.L.  
Melton<sup>a</sup>, J.M. Duncan<sup>b</sup>, V.V. Bogomolov<sup>d</sup>

<sup>a</sup> Wyle Integrated Science and Engineering Group, 1290 Hercules Ave, Houston, TX, 77058, USA

<sup>b</sup> National Aeronautics and Space Administration Lyndon B. Johnson Space Center, 2101 NASA Road 1, Houston, TX 77058, USA

<sup>c</sup> Yuri A. Gagarin Cosmonaut Training Center (GCTC), Moscow Region, 141160, Russia

<sup>d</sup> Institute for Biomedical Problems, Russian Academy of Sciences, 76-A Khoroshevskoye sh., Moscow 123007, Russia

<sup>e</sup> Department of Surgery, Henry Ford Hospital, 2799 West Grand Boulevard Detroit, MI 48202, USA

---

## Abstract

**Introduction:** This joint U.S. - Russian work aims to establish a methodology for assessing cardiac function in microgravity in association with manipulation of central circulating volume. Russian Braslet-M occlusion cuffs were used to temporarily increase the volume of blood in the lower extremities, which effectively reduces the volume returning to the heart in the central circulation. A novel methodology was tested on the International Space Station (ISS) to assess the volume status of crewmembers by evaluating the responses to application and release of the Braslet-M occlusion cuffs, as well as to modified Valsalva and Mueller maneuvers.

**Results:** Baseline echocardiographic tissue Doppler imaging (TDI) of the right ventricular free wall with no Braslet applied shows early diastolic E' (16 cm/sec), late diastolic A' (14 cm/sec),

and systolic (12 cm/sec) velocities compatible with normal subjects on Earth. TDI of the RV free wall with Braslet applied shows that early diastolic  $E'$  decreased by 50% (8 cm/sec), late diastolic  $A'$  increased by 45%, and systolic  $S'$  remains unchanged. TDI of the RV free wall approximately 8 beats after the Braslet was released shows early diastolic  $E'$  (8 cm/sec), late diastolic  $A'$  (12 cm/sec), and systolic  $S'$  (13 cm/sec) velocities. During this portion of the release, early diastolic  $E'$  did not recover to baseline values but late diastolic  $A'$  and systolic  $S'$  recovered to pre-Braslet values. The pre-systolic cross-sectional area of the internal jugular vein with Braslet off was 1.07 cm<sup>2</sup> and 1.13 cm<sup>2</sup> 10 min after the Braslet was applied. The pre-systolic cross-sectional area of the common femoral vein with Braslet off was 0.50 cm<sup>2</sup>, and was 0.54 cm<sup>2</sup> 10 min after the Braslet was applied. The right ventricular myocardial performance Tei index<sup>17,18</sup> also was calculated for comparison with typical values found in healthy subjects on Earth. Baseline and Braslet-on values for Tei index were 0.25 and 0.22 respectively. Braslet Tei indices are within normal ranges found in healthy subjects and temporarily become greater than 0.4 during the dynamic Braslet release portion of this study.

Conclusions: Tissue Doppler imaging of the right ventricle revealed that the Braslet influenced cardiac preload and that fluid was sequestered in the lower-extremity interstitial and vascular space after only 10 minutes of application. This report demonstrates that Braslet application affects right ventricular physiology in long-duration space flight based on TDI and that this effect is in part due to venous hemodynamics.

*Keywords:* Hypervolemia, Space Flight, Fluid Shift, Microgravity, Venous Occlusion Cuffs, Braslet-M, Countermeasure, Echocardiography, Remote Guidance, International Space Station, Fluid Sequestration

---

## Introduction

Alterations in gravity affect the cardiovascular system. The acute redistribution of fluid upon onset of microgravity after launch is eventually compensated in the early adaptation period of space flight.<sup>1,7,13,15</sup> These fluid redistributions usually reach steady state within a week of exposure and persist until the subject returns to Earth or a partial gravity environment.<sup>6</sup> For long-duration microgravity missions, a thorough understanding of steady-state cardiovascular physiology and cardiovascular responses to interventions and disturbances (e.g., gravity change, volume overload, volume depletion) is important for planning of future long-duration exploratory missions and medical care.

ISS crewmembers have the option of using the Braslet-M (Kentavr-Nauka, Moscow, Russia) occlusion cuffs to help ameliorate the acute adverse effects of weightlessness. The Braslet is a set of elastic compression cuffs worn on the upper thighs, intended as countermeasures against the initial microgravity effects of blood pooling in the upper torso (heaviness and blood pulsation in the head), facial puffiness, nasal stuffiness, painful eye movement, and vestibular disorders (dizziness, nausea, vomiting). They are intended to create artificial blood accumulation in the lower extremities, causing some of the circulating blood volume to relocate inferiorly from the upper body, presumably correcting the adverse hemodynamic effect of microgravity and improving the crewmember's working capability. Braslet also has been used with the intent to “retrain” the cardiovascular system for the return of gravity forces after long-duration missions by inducing a hypovolemic state in space. The actual Braslet compression cuff is a combination of alternating tensile and non-tensile elements, which when tightened creates elastic forces that produce the necessary radial pressure on the thighs. The Braslet-M device is custom built and calibrated in a special preflight tilt-table procedure using subjective responses and rheographic

data to determine the setting of the device that provides appropriate compression of the extremity.

Recent advances in remote guidance techniques for ultrasound imaging on ISS have facilitated the acquisition of high-fidelity physiological and clinical data by non-medical ultrasound operators. Using the existing ultrasound on the ISS (HDI-5000 ATL/Philips, USA) and the Russian Braslet-M occlusive elastic leg cuffs, the ability to measure the vascular and cardiac effects of the Braslet in space is possible. This collaborative effort between NASA and the Federal Space Agency – Roscosmos was established to assess a subset of cardiovascular physiologic variables in microgravity.

The goal of this case study was to validate and establish a robust ultrasound-based methodology and procedures for the assessment of right ventricular cardiovascular function in microgravity in association with the manipulation of the volume status of the subject. This was accomplished through focused ultrasound tissue Doppler measurement before and after Braslet-M application to acutely alter volume distribution.

## **Methods**

### **Subject Selection**

Following informed consent, a volunteer crewmember (ISS Multilateral Space Medicine Board, Medical Disposition Category 1) who completed a comprehensive physical examination and screening cardiovascular assessment consisting of a resting ECG, maximum tolerance exercise stress test 2D-transthoracic echocardiogram, Holter monitor, Electron Beam CT for coronary calcium scoring, a large assortment of laboratory blood tests, and a clinical cardiovascular risk assessment was used as the study subject.

## **Training**

The subject received 2 hours of ultrasound training approximately 4 months before launch (L-120). These high-fidelity simulations were performed in vehicle mockups with hands-on instruction by an expert sonographer using a simulated flight control team. All training was performed in the U.S. laboratory module Human Research Facility (HRF) simulator (Johnson Space Center – Houston) containing a flight-modified ATL HDI-5000 (Advanced Technology Laboratories, Seattle, USA) ultrasound system with the L12-5 and P4-2 probes. The L12-5 linear array probe was used to image peripheral vascular dimensions and internal jugular vein and artery parameters. The P 4-2 phased-array probe has a very small footprint; hence its primary role is cardiac imaging. Through a narrow aperture between ribs or infrasternal, it allows acquiring sector-shaped images with a field of view up to 22 cm in depth, which is ideal for imaging pericardial fluid and cardiac dynamics.

For the simulations and on-orbit ultrasound exams,<sup>9</sup> real-time streaming video of the ultrasound image with two-way audio communication was used. Reference images were made available to the crew and were used as a means to aid the crew in acquiring the appropriate image.

## **Calibration of the Braslet**

The Braslet-M device (Kentavr-Nauka, Moscow, Russia) was fitted for each crewmember before flight. The device is initially sized according to the circumference of the subjects' upper thighs just inferior to the groin. The crewmember is placed on a tilt table in a 30 degree head-down position. Subjects become symptomatic within less than a minute with facial fullness, stuffiness, headache, and sensation of arterial pulses in the head. The Braslet-M device is

tightened to impede blood flow returning to the heart against a significant venous orthostatic gradient. The effective mechanical occlusion pressure of the cuffs is provided by tightening or loosening a calibrated tension strap located on the lateral aspects of the thigh. When the subject in the 30 degree head-down position reports relief from the initial symptoms with rheographic data agreement, the Braslet setting is recorded. This tension strap setting is used for adjusting the Braslet on orbit. Using a pressure transducer method by Hamilton et al <sup>5,11</sup> during a test Braslet calibration procedure (conducted at Johnson Space Center, Houston Texas), the occlusion pressure of the Braslet was found to be equivalent to an air-filled thigh cuff inflated to approximately 50 mmHg.

### **On Orbit Data Acquisition Session:**

During on-orbit experiments, real-time video from the ultrasound was transmitted to Mission Control Center - Houston (MCC-H) using the ISS video subsystem. Two-way private space-to-ground audio was provided to an expert sonographer in MCC-H, who remotely guided the crewmembers through the Braslet scanning protocol, which typically takes 60 minutes to perform (See Figure 1).

The subject and operator restraining techniques were coordinated with the sonographer on the ground. Self-scanning techniques were primarily used on orbit. Self-scanning provides self-stabilization and no concern of the subject floating away from the operator in microgravity. When available, a second crewmember assisted with keyboard operations, which improved the efficiency and quality of data acquired through self-scanning.

A unique feature of the remote guidance system is the equipment-specific reference cue card. The card constitutes the basis of verbal information exchange between the operator and the expert, as it allows confident reference to and rapid identification of hardware elements and controls by the remote operator, time-saving localization of anatomic sites for initial placement of the transducer, and clear depiction of probe manipulation techniques. Components of the card have at least double-redundant identification options, such as alphanumeric designation, position, and color.

A timeline of cardiovascular measurements is illustrated in Figure 1 for the subject, including an echocardiographic examination in two-dimensional (2D), pulsed Doppler (PW) and tissue Doppler (TD) modes, as well as femoral (Fem) and jugular vein imaging (Jug). The Braslet device was then applied for a short duration (~10 minutes) and measurements were repeated. The Braslet was then released and the cardiovascular “recovery” process was monitored with similar measurements. The timeline depicts modified Valsalva and Mueller maneuvers which were included in the protocol; however no data taken during these maneuvers is presented in this report. Right ventricular (RV) tissue Doppler indices were measured from the apical 4-chamber view with the sample volume positioned on the RV free wall immediately inferior to the tricuspid valve annulus. The following parameters were measured; peak systolic velocity (S'), peak early (E'), and late (A') diastolic velocities. Tissue Doppler Tei index was calculated by dividing the sum of the isovolumic contraction time and isovolumic relaxation time by the ejection time  $((IVCT+IVRT)/ET)$ . Cross sectional areas of jugular and common femoral veins also were obtained.

## **Results**

## **Tissue Doppler**

Echocardiographic TD images (TDI) of the right ventricular (RV) free wall from on orbit with no Braslet applied are seen in Figure 2. These baseline data show early diastolic E' (16 cm/sec), late diastolic A' (11 cm/sec), and systolic (12 cm/sec) velocities consistent with values on Earth. TDI of the RV free wall from on orbit with Braslet applied for at least 10 minutes is seen in Figure 3. These pre-Braslet release data show early diastolic E' has decreased by 50% (8 cm/sec) and late diastolic A' increased to 16 cm/sec and systolic S' remained unchanged. TDI of the RV free wall from on orbit approximately 8 beats after the Braslet was released is seen in Figure 4. These post Braslet release data show early diastolic E' (8 cm/sec), late diastolic A' (12 cm/sec), and systolic S' (13 cm/sec) velocities. Early diastolic E' did not recover to baseline values but late diastolic A' and systolic S' recovered to pre-Braslet values. Figure 5 shows the TDI velocities of the right ventricular free wall before and after Braslet release with breathing resuming approximately 8 beats after the Braslet was released.

## **Venous Cross Sectional Areas**

The pre-systolic (ECG R-wave) cross-sectional area of the internal jugular vein with Braslet off was 1.07 cm<sup>2</sup> (Figure 6) and 1.13 cm<sup>2</sup> 10 min after the Braslet was applied (Figure 7). The pre-systolic cross-sectional area of the common femoral vein with Braslet off was 0.50 cm<sup>2</sup> (Figure 8) and 0.54 cm<sup>2</sup> 10 min after the Braslet was applied (Figure 9).

## **Right Ventricular Tei Index**

Global right ventricular myocardial performance Tei index<sup>17,18</sup> also was calculated for comparison with typical values found in healthy subjects on Earth. The baseline (no Braslet) Tei index was 0.25, 0.22 after approximately 10 min of Braslet application, and 0.28 after an additional 10 to 15 minutes of Braslet application (just before Braslet release, as seen in Figure



10). Braslet release Tei indices in figure 10 are within normal ranges found in healthy subjects and temporarily become greater than 0.4 during the dynamic Braslet release portion of this study.

### **Discussion:**

This case study used Braslet-M (Kentavr-Nauka, Moscow, Russia) occlusion cuffs to evaluate cardiac physiology in response to venous occlusion. The Braslet-M is a Russian-made operational countermeasure already precalibrated and available on board for each ISS crewmember. Although the utility of Braslet-M device use after 2 weeks of long-duration space flight is questioned, its short-term effects in the early adaptation period are less controversial.

The International Space Station is a multilateral medical research environment with a broad range of experimental capabilities. This particular multinational cooperative experiment required:

1. Availability of an advanced multipurpose ultrasound imager on board as part of the ISS Human Research Facility (HRF).
2. Substantial prior experience of the investigators with ISS HRF Ultrasound System.
3. Involvement of Russian experts with many years of experience with the Braslet-M device.
4. Review of the procedures and protocols by the Human Research Multilateral Review Board.
5. Thorough design, rehearsal, and execution of the procedures to verify the timeline of highly specific data acquisition schedules.
6. Cooperation among the U.S. and Russian scientists – experts in cardiovascular physiology, imaging, and space physiology.

This case study reports the use of tissue Doppler imaging in space and the short-term (less than 30 minutes) application of Braslet-M occlusive cuffs to evaluate any gross changes in right ventricular loading or venous volume changes in the neck and lower extremities. This experiment was classified as procedure verification using the combination of the Braslet and HRF ultrasound and therefore preflight and postflight TDI data were not acquired. Ground based simulations preceded the on-orbit experiments to rehearse the protocols and ensure adequate time allocation for each step of the procedure and to adjust the remote guidance tactics, discourse, and terminology with the crew. These simulations confirmed the ability for crew to perform echocardiography using the developed ergonomic and remote guidance techniques.

The results of this case study confirm the need to investigate the effect of the Braslet with a larger cohort of test subjects in space and on the ground. Figure 1 illustrates the on-orbit experimental timeline, which shows that multiple echocardiographic modes were used to obtain more than 100 different echocardiographic and ultrasound indices and more than 2000 data points per subject per scanning session.

Preliminary data analysis indicates that there are significant cardiovascular changes induced by the use of Braslet. The echocardiographic data in this report were limited to tissue Doppler imaging (TDI) because it was the only imaging mode used to measure the RV free wall effects before, during, and after Braslet release. The immediate physiological effects of the Braslet release occur over 10 to 30 seconds and the opportunity to switch imaging locations and modes was not possible, therefore TDI was chosen because it is the least dependent on cardiac loading. The right ventricle was chosen to measure the immediate changes in preload caused by the sudden release of the Braslet because there is very little on-orbit echocardiographic data

published about this chamber and RV TDI indices give insight into the preload provided by the central venous system and the direct effects of Braslet.

The resting pre-Braslet E', A' and S' indices (Figure 2) were comparable to that seen in a similar cohort on Earth. The subject had been on orbit for an extended period of time before the exam, therefore total body and vascular volume status are assumed to have been equilibrated to 'space normal'. There is normally a 1- to 2-liter cephalad fluid shift from the legs (primarily the thighs) that takes place in the first 8 to 24 hours of space flight and remains until landing.<sup>19</sup> This shift in fluid towards the heart is paradoxically accompanied by about a 5- to 7-mmHg decrease in central venous pressure (CVP) with no clinically significant changes in cardiac output.<sup>2,3</sup> The bedside examination of the jugular venous pressure (JVP) on Earth is a reliable indicator of mean right atrial pressure and end diastolic right ventricular pressure because the vena cava acts as a venous hydrostatic column of blood. Jugular venous distension is a normal response to space flight that persists throughout the mission and would not be helpful in determining changes in right atrial pressure and right ventricular preload. Paradoxically, this test subject with a fully distended JVP would be considered hypovolemic by Earth standards yet euvoletic by microgravity standards.<sup>19</sup>

In this particular study, we observed a 5.5% increase in venous distension with the Braslet applied (Figure 6 and 7) at end diastole (ECG R-wave). This may occur because it takes very little pressure to completely distend the internal jugular vein, which is almost continually maximally distended in a crewmember on orbit. Minor respiratory maneuvers such as speech or momentary breath holding could cause the observed increase. For this subject, it appears that the application of Braslet does not produce hemodynamic changes significant enough to decrease jugular distension. Therefore, using measurements of jugular dimensions as a means of

determining central venous pressure and right ventricular preload in space is not a sensitive method.

Significant changes in RV preload were seen by TDI. TDI of the RV free wall from on-orbit with no Braslet applied is seen in Figure 2. These baseline on-orbit data show early diastolic E' (16 cm/sec), late diastolic A' (14 cm/sec), and systolic (12 cm/sec) velocities that have been seen in normal populations on Earth. This implies that the venous return in space is most likely similar to that seen on Earth despite the lack of a gravitational gradient and reduced fluid stored in the lower extremities. This is likely due to the lower-extremity venous vascular system operating at a much lower volume point on its pressure-volume relationship curve, causing capacitance vessels to behave more like conduit vessels. This would have minimal effect on venous return but it reduces the recruitable blood volume needed for response to acute volume changes that would cause cardiovascular stress and adrenergic venous constriction. Muscle sympathetic nerve activity as a direct measure of sympathetic nervous system responses was found to be increased on orbit in six subjects in a study by Levine et al.<sup>14</sup> Orthostatic intolerance is common when crewmembers return to Earth: after brief space flight, up to two-thirds are unable to remain standing for 10 minutes. Previous research suggests that susceptible individuals are unable to increase their systemic vascular resistance and plasma noradrenaline concentrations above preflight upright levels. The Levine study<sup>14</sup> tested the hypothesis that adaptation to the microgravity of space impairs sympathetic neural responses to upright posture on Earth. Muscle sympathetic nerve activity was higher postflight in all subjects, in supine and tilted positions. A strong linear correlation between left ventricular stroke volume and muscle sympathetic nerve activity suggested that sympathetic responses were appropriate for the hemodynamic challenge of upright tilt and were unaffected by space flight, therefore Levine et

al<sup>14</sup> concluded that after 16 days of space flight, muscle sympathetic nerve responses to upright tilt are normal. The relatively normal TDI seen in this subject, along with a minor increase in lower-extremity femoral cross section with the application of Braslet (approximately equivalent to 50 mmHg occlusion cuff pressure on the upper thigh) implies that the large conduit vessels of the venous system are almost fully distended despite the decrease in central venous pressure.<sup>2,3</sup> This result implies that RV preload can be maintained despite such low central venous pressures.

Under normal circumstances RV preload can be measured by observing the height of the jugular venous pulse relative to the “sternal angle of Lewis” under normal gravity conditions. These pressures typically have been found to be 5 to 7 mmHg with high normal around 10 mmHg relative to the right atrium. With central venous pressures at 1 to 2 mmHg in space yet baseline TDI E', A' and S' indices remaining normal seems to disagree with “Starling’s Law of the Heart.” Hamilton et al found that the actual amount of transmural pressure required for normal human right ventricular diastolic filling is approximately 1.5 mmHg.<sup>5,10,11</sup> Therefore, in order for right ventricular cavity pressures to maintain normal diastolic filling seen in the baseline TDI of our subject in space implies that epicardial radial stress (pericardial pressure) must decrease by approximately 5 to 6 mmHg to less than 1 mmHg in space.<sup>10</sup>

The pericardium is a thin fibrous sac that is relatively nondistensible compared to cardiac chambers when its total volume is greater than its unstressed volume. The results of this case study imply that either the pericardial unstressed volume increased or LV end-diastolic volumes decreased to make room for the RV. Earlier studies during Mir, Shuttle, and ISS (unpublished results from Hamilton) show that LV diastolic volumes were not significantly changed after total body fluid status reached a space normal level (after at least 1 month). One possible explanation for this phenomenon is the caudal shift of the central diaphragm due to unopposed abdominal

muscle tone, allowing the pericardial-diaphragmatic ligament to move superiorly and allow the pericardium to assume a more spherical shape compared to its terrestrial ellipsoidal shape. This shift would allow the effective pericardial volume to increase with no change in surface area, resulting in an increased unstressed pericardial volume. Further research on the ISS might confirm this theory, which would be useful for researchers who are attempting to model the behaviour of the cardiovascular system. Current cardiovascular models do not compensate for the observations of normal diastolic filling and normal TDI indices in spite of decreased central venous pressure. This deficiency in current models decreases their utility for space medicine physicians attempting to understand normal space cardiovascular physiology and pathophysiology.

These right ventricular TDI results imply that high- or low-pressure pulmonary edema in space may not respond to pharmacological treatments that increase veno-vascular compliance. In these cases, the Braslet may pose an alternative treatment for acutely reducing right ventricular preload. TDI of the RV free wall from on orbit with Braslet applied for at least 10 minutes is seen in Figure 3. These pre-Braslet release data show early diastolic  $E'$  (8 cm/sec), late diastolic  $A'$  (16 cm/sec), and systolic  $S'$  (12 cm/sec) velocities. Early diastolic  $E'$  has decreased by 50% (8 cm/sec), late diastolic  $A'$  has increased by 14%, and systolic  $S'$  remains unchanged. This indicates that although systolic velocity  $S'$  is unchanged and internal jugular vein dimensions remain distended, the early diastolic filling velocities  $E'$  are decreased with moderately increased late diastolic filling velocities ( $A'$ ). The diminished early diastolic preload seems to be compensated by the late contribution from atrial contraction. Since the jugular vein is near-maximally distended, a diminished v-wave and increased a-wave will not be observed in space. Therefore although RV early distending pressures and filling velocities were decreased

with the application of the Braslet, the compensatory atrial contraction seems to be able to maintain cardiac output. On Earth, test subjects who participated in the 30 degree head-down tilt Braslet calibration procedure and crewmembers who wore them shortly after launch reported a beneficial reduction in symptoms. The diminished  $E'$  seen with the application of the Braslet in our subject may be an indication of reduced CVP despite the distended jugular vein. Before fluid volume equilibration during the first days of space flight, the pre-Braslet  $E'$  may be higher than the control  $E'$  seen in our long-duration subjects due to the relative fluid overload in the central circulation.

TDI of the RV free wall from on orbit approximately 8 beats after the Braslet was released is seen in Figure 4. These post-Braslet release data show early diastolic  $E'$  (8 cm/sec), late diastolic  $A'$  (12 cm/sec), and systolic  $S'$  (13 cm/sec) velocities. Early diastolic  $E'$  has not recovered to baseline values but late diastolic  $A'$  and systolic  $S'$  have recovered to near pre-Braslet values. If all the fluid sequestered in the lower extremities was stored in the vascular space, the rapid Braslet release would be expected to increase  $E'$  and  $A'$  dramatically until fluid distribution equilibrium is established. One explanation for the slow recovery of the TDI indices after Braslet release could be that a significant portion of the fluid stored in the lower extremities was pushed into the interstitial compartments over the short 10-minute application. An alternative explanation is that the short duration of Braslet application does not cause substantial fluid pooling in the lower extremities despite the reduction in symptoms reported by test subjects and crewmembers. However, this explanation is not supported as evidenced by the alterations in TDI indices during Braslet application, as well as the dramatic changes seen during Braslet release.

Figure 5 shows the TDI velocities of the right ventricular free wall immediately before and after Braslet release, with breathing resuming approximately 8 beats after the Braslet was

released. There is an acute and noticeable increase in TDI velocities upon Braslet release but they did not fully return to the pre-Braslet values. Approximately 8 beats after the Braslet release, the normal respiratory variation of E' and A' and their effect on S' is seen. As the venous bed empties, E' trends back to the 'Braslet on' pre-release values, causing A' to increase to sustain S'. This implies that E' recovery to pre-Braslet values will occur when all interstitial fluid in the lower extremities returns to the vascular space.

RV Tei Index<sup>17,18</sup> was found to be similar to that found in healthy subjects of a similar age on Earth. Baseline and Braslet-on values for Tei Index was 0.25 and 0.22 respectively. The dynamic release of the Braslet (Figure 10) showed a temporary increase in Tei index to greater than 0.4, which normalized within 20 beats. This normalization period, which is extended as compared to the recovery of E', may have been caused due to the resumption of breathing. The predominant factor in this increase in Tei index was the relative increase in IVCT, which may reflect the increased stroke volume secondary to the Braslet release. Tricuspid 2D-Doppler and right ventricular chamber volume calculations will need to be measured in the future to confirm this.

The Braslet has measureable effects on the cardiovascular system on orbit, which agree with the reported changes in physical exam and symptoms reported by test subjects and crewmembers.

## **Conclusion**

A novel noninvasive methodology has been developed for cardiovascular system evaluation in conditions of space flight<sup>4,8,12,16</sup> with an emphasis on using upper thigh compression for hemodynamic modification. Preliminary results from this case study include echocardiographic



and vascular ultrasound data from a single volume-stabilized long-duration space flight crewmember. In association with the application and release of the Braslet device, this technique may provide a noninvasive means to manipulate vascular volume on orbit.

This case study was a portion of a larger project directed at the development and validation of appropriate methodology for studying cardiovascular responses to disturbances (for example, gravity change, volume overload, hemorrhage and others) using existing ISS resources. It is expected that this methodology will yield valuable physiological and operational data for planning and support of missions to the moon and other remote destinations.

This activity will also aid in defining the on-orbit and ground resources needed to enable comprehensive cardiovascular research during future ISS increments. In addition to investigating cardiovascular system physiology, a study of the safety, utility, and potentially new or expanded uses of the Braslet-M device is warranted. This investigation is the first report of measurements of the effect of occlusion cuffs on the cardiovascular system on long-duration crewmembers and initial results suggest that they may be useful for acute or chronic volume manipulation for both terrestrial and on orbit medical purposes.

TDI of the right ventricle revealed that the Braslet has an effect on preload and that fluid seems to be sequestered in the lower-extremity interstitial and vascular space after only 10 minutes of application. Further research is necessary, including whole heart imaging to more fully understand right heart physiology during long-duration space flight with or without venous occlusion.

# Figures

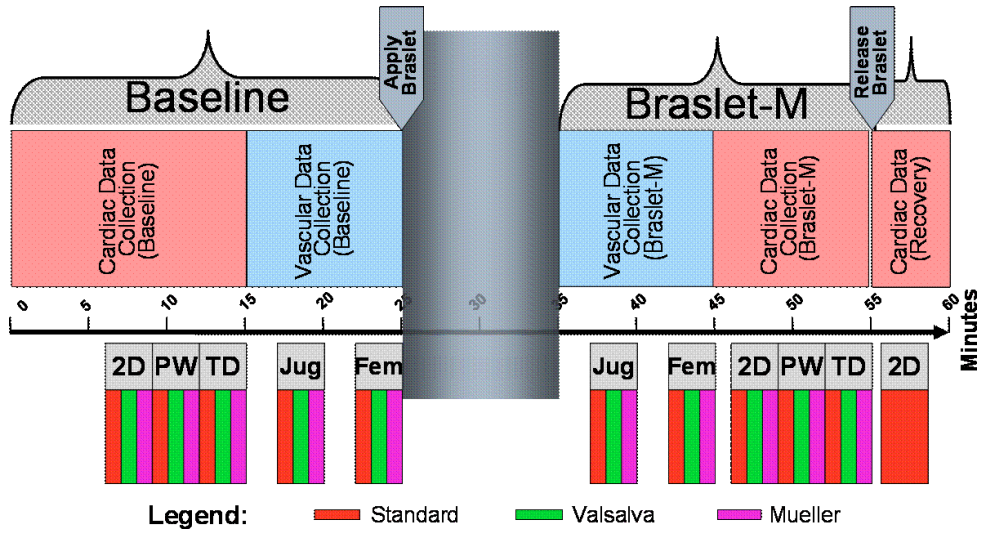


Figure 1. A timeline of cardiovascular measurements taken from each subject

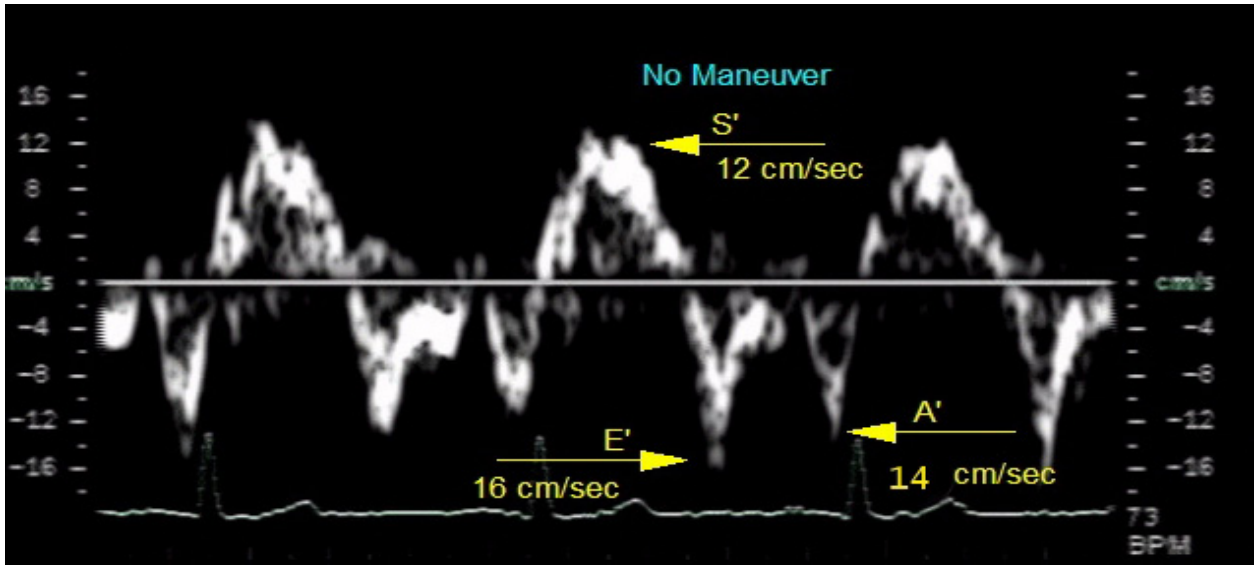


Figure 2. Echocardiographic tissue Doppler image of the right ventricular free wall from on orbit with no Braslet applied.

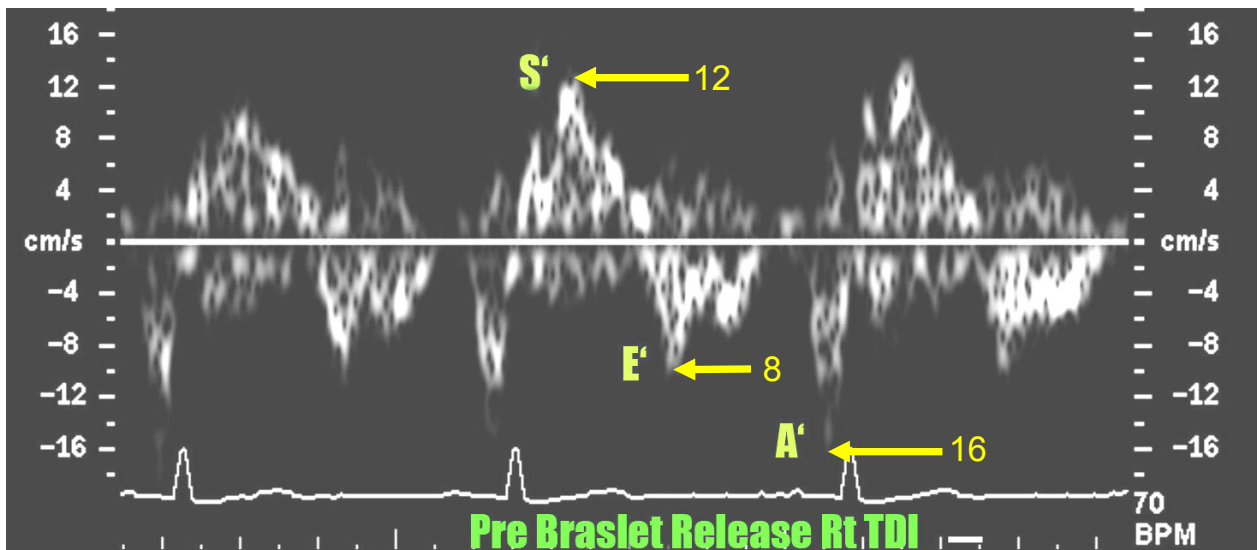


Figure 3. Echocardiographic tissue Doppler image of the right ventricular free wall from on orbit with Braslet applied for at least 10 minutes.

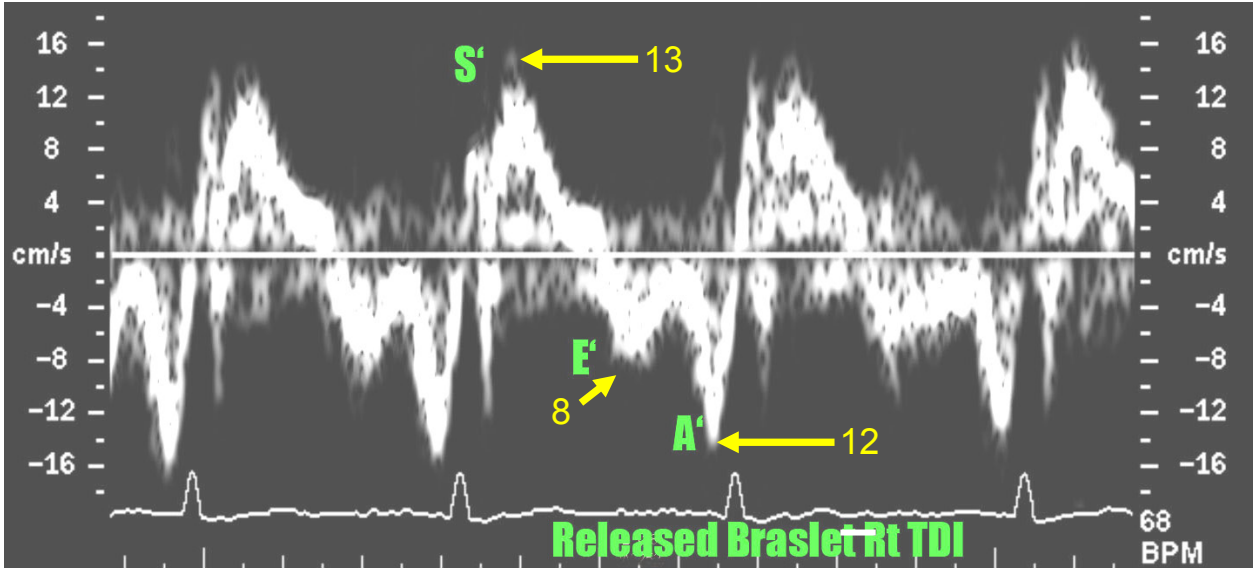


Figure 4. Echocardiographic tissue Doppler image of the right ventricular free wall from on orbit approximately 8 beats after the Braslet was released.

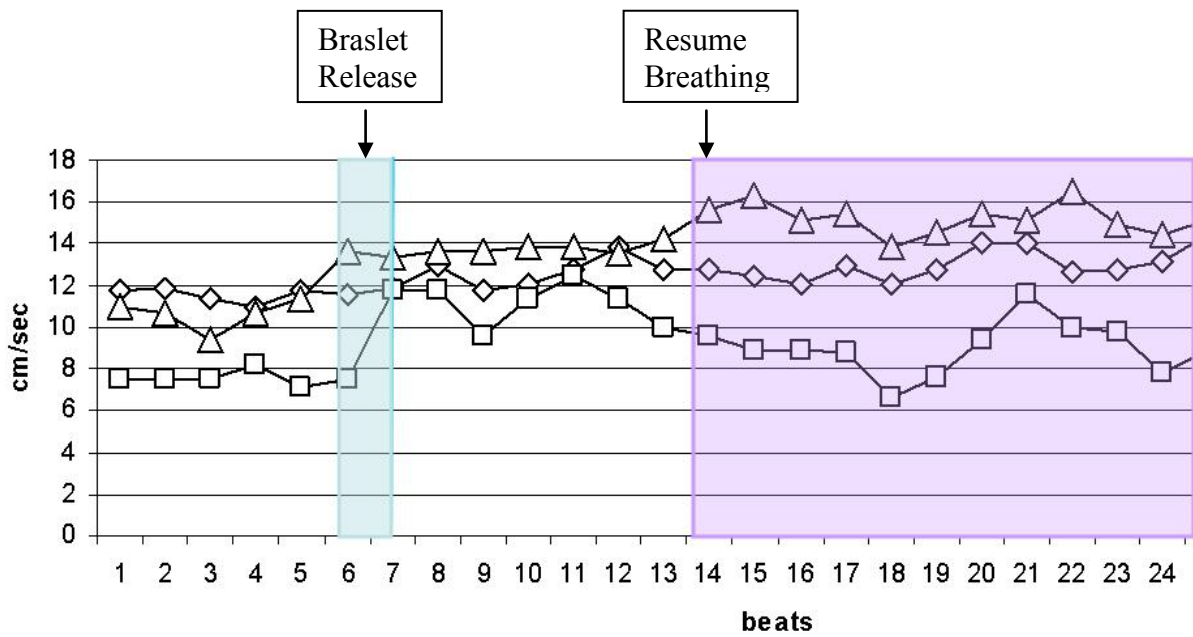


Figure 5. Echocardiographic tissue Doppler velocities of the right ventricular free wall (diamonds – S', squares - E', triangles – A') before and after Braslet release with breathing resuming approximately 8 beats after the Braslet was released. Braslet release is indicated by the blue-shaded area and breathing resumes 8 beats later as indicated by the purple-shaded area.

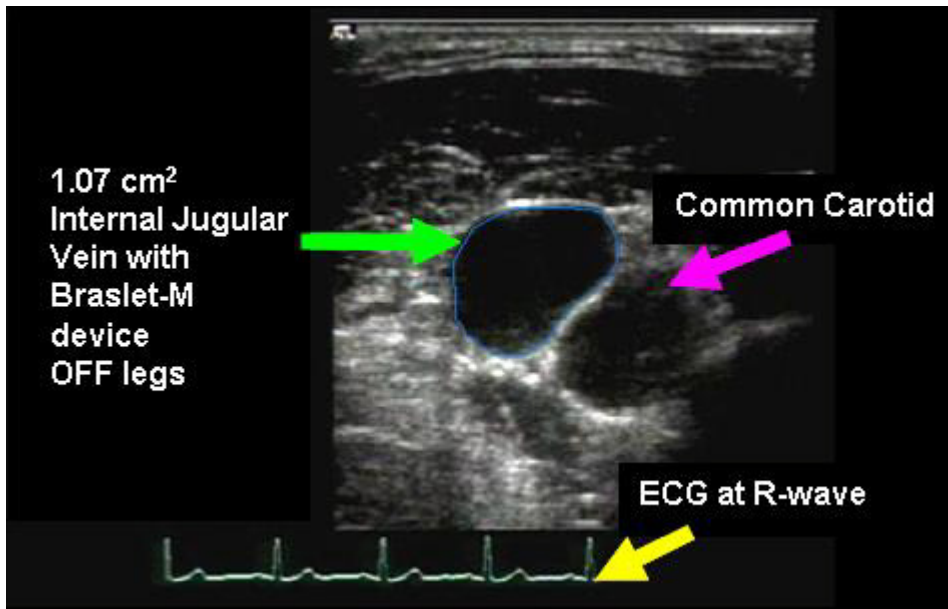


Figure 6. Pre-systolic (ECG R-wave) cross-section area of the internal jugular vein and common carotid artery before Braslet is applied.

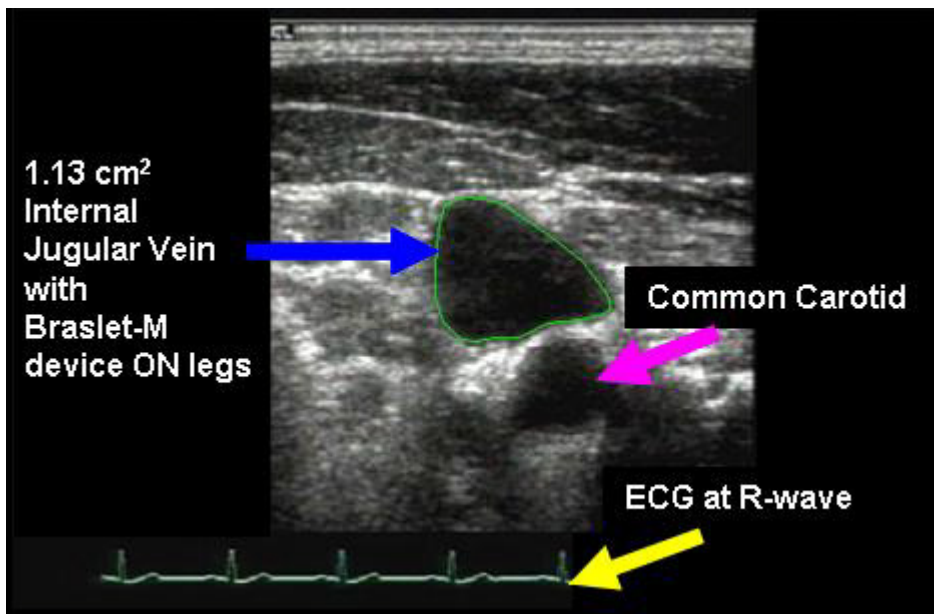


Figure 7. Pre-systolic (ECG R-wave) cross-sectional area of the internal jugular vein and common carotid artery 10 minutes after the Braslet was applied



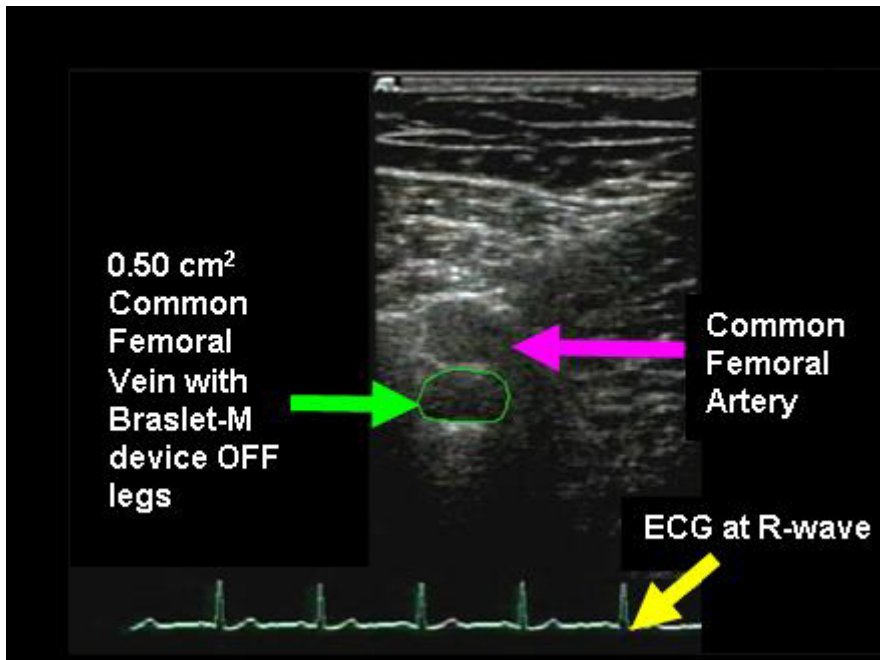


Figure 8. Pre-systolic (ECG R-wave) cross-section area of the common femoral vein and common femoral artery before the Braslet is applied.

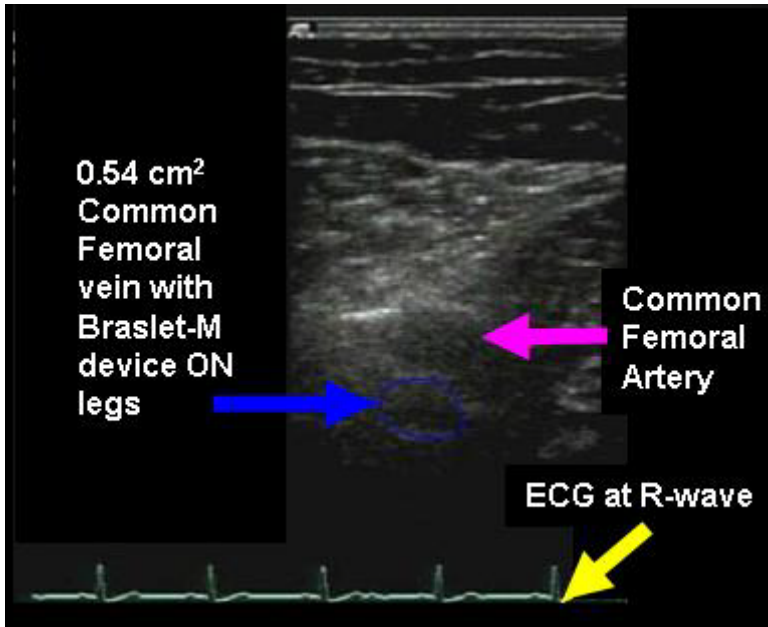


Figure 9. Pre-systolic (ECG R-wave) cross-sectional area of the common femoral vein and common femoral artery 10 minutes after Braslet was applied.

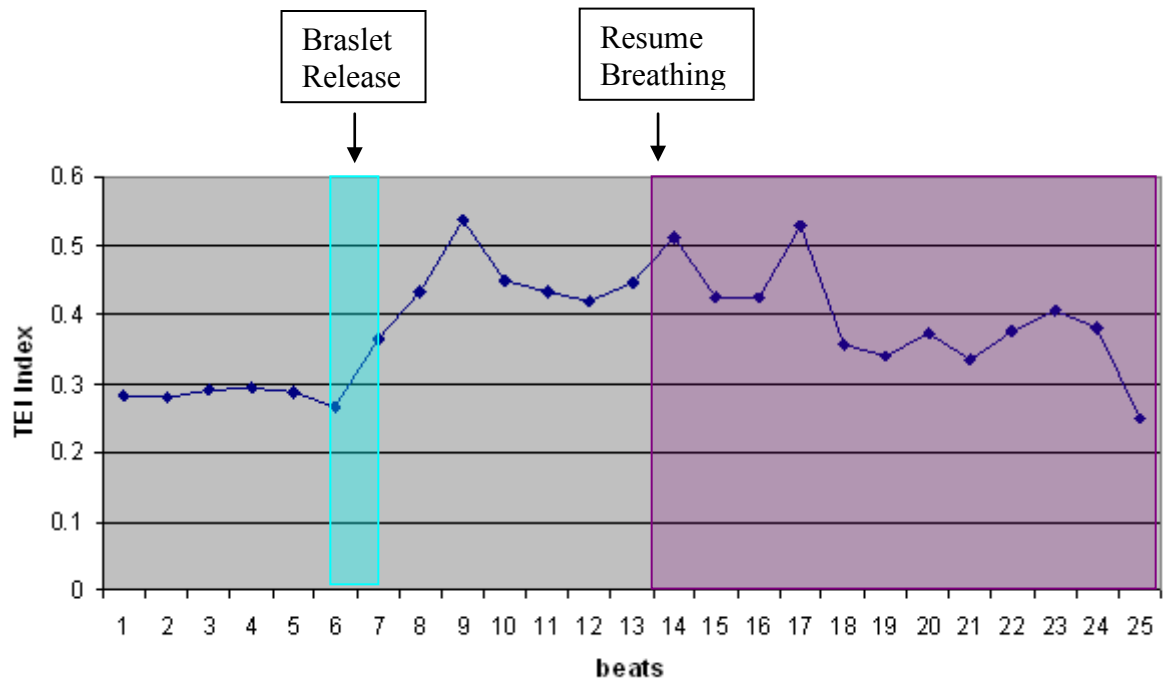


Figure 10. Tei index of RV global myocardial performance before and after Braslet release with breathing resuming approximately 8 beats after the Braslet was released. Braslet release is indicated by the blue-shaded area and breathing resumes 8 beats later as indicated by the purple-shaded area.

## Reference List

1. Alferova IV, Turchaninova VF, Golubchikova ZA, Liamin VR. [Functional state of the cardiovascular system of cosmonauts at rest in long-term space flight]. *Aviakosm Ekolog Med* 2002;36(4):20-5.
2. Buckey JC, Gaffney AF, Lane LD, Levine BD, Watenpaugh DE, Blomquist CG. Central Venous Pressure in Space. *NEJM* 1993;328(25):1853-4.
3. Buckey JC, Gaffney AF, Lane LD, Levine BD, Watenpaugh DE, Wtight SJ, et al. Central Venous Pressure in Space. *J Appl. Physiol.* 1996;81(1):19-25.
4. Chiao L, Sharipov S, Sargsyan AE, Melton S, Hamilton DR, McFarlin K, et al. Ocular examination for trauma; clinical ultrasound aboard the International Space Station. *J Trauma* 2005 May;58(5):885-9.
5. deVries G, Hamilton DR, Ter Keurs HE, Beyar R, Tyberg JV. A novel technique for measurement of pericardial pressure. *Am J Physiol Heart Circ Physiol* 2001 Jun;280(6):H2815-22.
6. Drummer C, Gerzer R, Baisch F, Heer M. Body fluid regulation in micro-gravity differs from that on Earth: an overview. *Pflugers Arch* 2000;441(2-3 Suppl):R66-72.
7. Egorov AD, Alferova IV, Anashkin OD, Bernadskii VI, Golubchikova ZA. [Cardiovascular system studies in long space flights on the Saliut orbital stations]. *Izv Akad Nauk SSSR Biol* 1982 Jul-1982 Aug;(4):485-98.
8. Fincke EM, Padalka G, Lee D, van Holsbeeck M, Sargsyan AE, Hamilton DR, et al. Evaluation of shoulder integrity in space: first report of musculoskeletal US on the International Space Station. *Radiology* 2005 Feb;234(2):319-22.
9. Foale CM, Kaleri AY, Sargsyan AE, Hamilton DR, Melton S, Martin D, et al. Diagnostic instrumentation aboard ISS: just-in-time training for non-physician crewmembers. *Aviat Space Environ Med* 2005 Jun;76(6):594-8.
10. Hamilton DR, Dani RS, Semlacher RA, Smith ER, Kieser TM, Tyberg JV. Right atrial and right ventricular transmural pressures in dogs and humans. Effects of the pericardium. *Circulation* 1994 Nov;90(5):2492-500.
11. Hamilton DR, Devries G, Tyberg JV. Static and dynamic operating characteristics of a pericardial balloon. *J Appl Physiol* 2001 Apr;90(4):1481-8.
12. Hamilton DR, Sargsyan AE, Kirkpatrick AW, Nicolaou S, Campbell M, Dawson DL, et al. Sonographic detection of pneumothorax and hemothorax in microgravity. *Aviat Space Environ Med* 2004 Mar;75(3):272-7.
13. Johnson PC. Fluid volumes changes induced by spaceflight. *Acta Astronaut* 1979 Oct;6(10):1335-41.
14. Levine BD, Pawelczyk JA, Ertl AC, Cox JF, Zuckerman JH, Diedrich A, et al. Human muscle sympathetic neural and haemodynamic responses to tilt following spaceflight. *J Physiol* 2002 Jan;538(Pt 1):331-40.
15. Poliakov VV, Anashkin OD, Alferova IV, Turchaninova VF, Golubchikova ZA, Poliakova AP, et al. [The cardiovascular system function of the cosmonauts of the 6th prime expedition on the Mir station]. *Aviakosm Ekolog Med* 1992 May-1992 Jun;26(3):48-52.
16. Sargsyan AE, Hamilton DR, Jones JA, Melton S, Whitson PA, Kirkpatrick AW, et al. FAST at MACH 20:

clinical ultrasound aboard the International Space Station. *J Trauma* 2005 Jan;58(1):35-9.

17. Tei C, Nishimura RA, Seward JB, Tajik AJ. noninvasive Doppler-derived myocardial performance index: correlation with simultaneous measurements of cardiac catheterization measurements. *Am J Cardiol*. 1997;19:169-78.
18. Tei C, Seward JB, Tajik AJ, Minagoe S, Toyama Y. Index of myocardial performance - a simple and reproducible measurement of global right-ventricular myocardial-function. *Am J Cardiol*. 1995;92:2834.
19. Thornton WE, Hedge V, Coleman E, Uri J, Moore T. Changes in Leg Volumes during microgravity simulation. *Aviat. Space Environ. Med.* 1992;63:789-94.