

# OPTIC NERVE SHEATH DIAMETER: TRANSLATING A TERRESTRIAL FOCUSED TECHNIQUE INTO A CLINICAL MONITORING TOOL FOR SPACEFLIGHT

Sara Mason<sup>1</sup>, Millennia Foy<sup>2</sup>, Ashot Sargsyan<sup>2</sup>, Kathleen Garcia<sup>2</sup>, Mary L. Wear<sup>2</sup>, Deepak Bedi<sup>3</sup>, Randy Ernst<sup>3</sup>, Mary Van Baalen<sup>4</sup>

<sup>1</sup>MEI Technologies, <sup>2</sup>Wyle Science, Technology and Engineering Group, <sup>3</sup>University of Texas MD Anderson Cancer Center, <sup>4</sup>NASA Johnson Space Center

## Introduction

Ultrasonography is increasingly used to quickly measure optic nerve sheath diameter (ONSD) when increased intracranial pressure (ICP) is suspected [1]. NASA Space and Clinical Operations Division has been using ground and on-orbit ultrasound since 2009 as a proxy for ICP in non-acute monitoring for space medicine purposes. In the terrestrial emergency room population, an ONSD greater than 0.59 cm is considered highly predictive of elevated intracranial pressure [1]. However, this cut-off limit is not applicable to the spaceflight setting since over 50% of US Operating Segment (USOS) astronauts have an ONSD > 0.60 cm even before launch. Crew Surgeon clinical decision-making is complicated by the fact that many astronauts have history of previous spaceflights. Our data characterize the distribution of baseline ONSD in the astronaut corps, its longitudinal trends in long-duration spaceflight, and the predictive power of this measure related to increased ICP outcomes.

## Methods

### Equipment

ONSD was measured in a standardized axial plane at 3mm from the retinal interface. Images were acquired with a HDI-5000 multipurpose ultrasound system (ATL/Philips Medical Systems, WA, USA) in the early phase, then with a HD-15 ultrasound system (Philips Medical Systems, WA, USA) for preflight and postflight data and the Vivid q ultrasound system (General Electric, USA) for inflight examinations. All systems were used with 12 MHz linear array probes. Measurements were made in the Synapse Cardiovascular DICOM analysis software environment (Fujifilm, USA).

### Material

We used the first ground-based measurement of ONSD in astronauts to estimate a cohort-specific distribution of normative values. Spaceflight representative trends were analyzed using the preflight, inflight (L+(30±7)d; L+(100±7)d; R-(30±7)d) and postflight R+(3-7)d measurements. Disc edema diagnosis is based on postflight (R+(3-7)d) fundoscopic examination.

### Statistical Analysis

Distribution curves were created using normal kernel smoothing estimators of the probability density and cumulative distribution functions. Permutation testing was used to assess differences in ONSD between disc edema and non-edema eyes. Mean ONSD and confidence limits were estimated using bootstrap resampling.

## Results

Figure 1. First ground measurement.

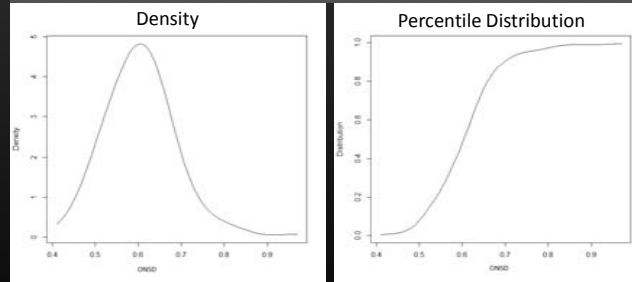


Figure 2. Inflight averages vs. time.

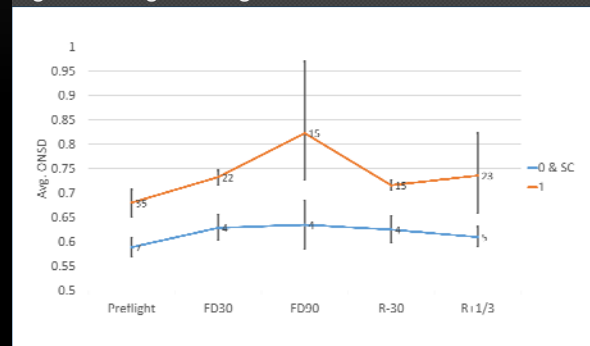
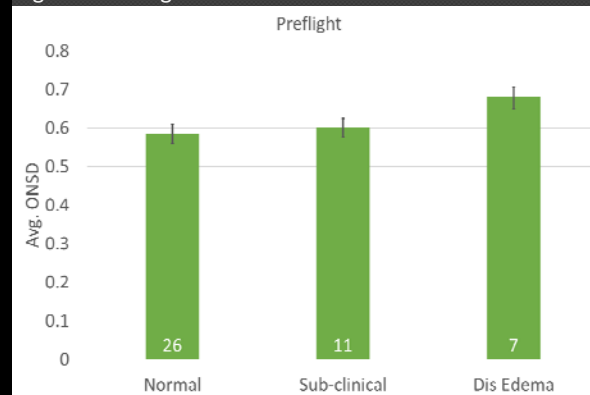


Figure 3. Preflight ONSD vs. disc edema.



## Discussion

Within the astronaut cohort, we have determined that ultrasound measurement of ONSD using a standardized method has high inter-rater reliability. Terrestrial values for ONSD have limited generalizability to the astronaut population due to significant differences in the setting, health status, population characteristics, and measurement fidelity. This necessitated creation of population-specific distribution curves.

## Conclusions

1. A cohort-specific distribution curve of the ONSD values was successfully created, thus providing a reference framework for clinical use of ONSD.
2. Astronauts who developed disc edema started out with larger preflight ONSD values (difference of 0.09; 95%CI: 0.06, 0.13; p<0.001).
3. Inflight ONSD appears to moderately increase (difference of 0.05; 95%CI: 0.01, 0.10; p<0.0001)
4. More data are necessary to assess the clinical significance of trends within an individual astronaut.

## Future Work

Optic nerve sheath diameter is just one of the many features of the eye and orbit assessed with ultrasound; other features include globe length, disc elevation, and posterior globe flattening. A broader analysis is underway to examine the value of these anatomical and functional criteria for clinical management, as well as to elucidate the intricate mechanisms in the pathogenesis of VIIP phenomena.

## Reference

[1] Dubourg, J., Javouhey, E., Geeraerts, T., Messerer, M., & Kassai, B. (2011). Ultrasonography of optic nerve sheath diameter for detection of raised intracranial pressure: a systematic review and meta-analysis. *Intensive Care Medicine*, 37(7), 1059-1068