

Analysis by NASA's VESGEN Software of Vascular Branching in the Human Retina with a Ground-Based Microgravity Analog

Patricia Parsons-Wingerter¹, Ruchi J. Vyas¹, Sneha Raghunandan¹, Amanda C. Vu², Susana B. Zanello³, Robert Ploutz-Snyder³, Giovanni Taibbi⁴, Gianmarco Vizzeri⁴

¹Space Life Sciences Research Branch, Ames Research Center, National Aeronautics and Space Administration (NASA), Moffett Field CA 94022-1000

²NASA SLSTP Summer Internship & Biomedical Engineering, University of California, Berkeley CA

³Universities Space Research Association, NASA Johnson Space Center, Houston TX

⁴Department of Ophthalmology and Visual Sciences, The University of Texas Medical Branch at Galveston, Galveston TX

PURPOSE

Significant risks for visual impairment were discovered recently in astronauts following spaceflight, especially after long-duration missions.¹ We hypothesize that microgravity-induced fluid shifts result in pathological changes within the retinal vasculature that precede visual and other ocular impairments. We therefore are analyzing retinal vessels in healthy subjects with NASA's VESSEL GENERATION ANALYSIS (VESGEN) software² before and after head-down tilt (HDT), a ground-based microgravity analog.

METHODS

Heidelberg Spectralis® 30 degree infrared (IR) fundus images were collected from both eyes of 6 subjects before and after 70 days of bed rest at 6 degree HDT (NASA Campaign 11). For our retrospective study, branching patterns in arterial and venous trees are mapped by VESGEN into vessel branching generations (G_x) quantified by parameters that include densities of vessel length (L_v), area (A_v), number (N_v) and fractal dimension (D_f) as described previously for diabetic retinopathy.² Results are further assigned by VESGEN into groups of large (G_{1-3}), medium (G_{4-6}) and small ($G_{\geq 7}$) vessels.

RESULTS

All subjects remained asymptomatic throughout duration of HDT. To date, we have analyzed one IR image from each of the 12 eyes. Interestingly, two groups identified by VESGEN analysis within the masked study population are distinguished by the presence or absence of small veins ($G_{\geq 7}$). For example, $L_{\geq 7}$ and $A_{v\geq 7}$ are $2.7 \pm 1.3 \text{ E-4 micron/micron}^2$ and $7.2 \pm 3.6 \text{ E-4 micron}^2/\text{micron}^2$ in 6 retinas, but 0 in the other 6 retinas. Nonetheless, the space-filling properties of the entire venous trees for all 12 retinas were remarkably uniform by all parameters, such as $D_f = 1.56 \pm 0.02$ for 6 retinas with $G_{\geq 7}$ and 1.55 ± 0.02 for retinas without $G_{\geq 7}$. No small arteries ($G_{\geq 7}$) were detected.

CONCLUSIONS

For our preliminary study of masked images, two groups of venous trees with and without small veins ($G_{\geq 7}$) were clearly identified by VESGEN analysis. Upon completing all images and unmasking the subject status of pre- and post- HDT, we will determine whether differences in the presence or absence of small veins are important correlates, and perhaps reliable predictors, of other ocular and physiological adaptations to prolonged HDT and microgravity. Greater peripapillary retinal thickening was measured following 70-day HDT bed rest than 14-day HDT bed rest, suggesting that time of HDT may increase the amount of optic disc swelling.³ Spectralis OCT detected retinal nerve fiber layer thickening post HDT, without clinical signs of optic disc edema. Such changes may have resulted from HDT-induced cephalad fluid shifts. Clinical methods for examining adaptive microvascular remodeling in the retina to microgravity space flight are currently not established.

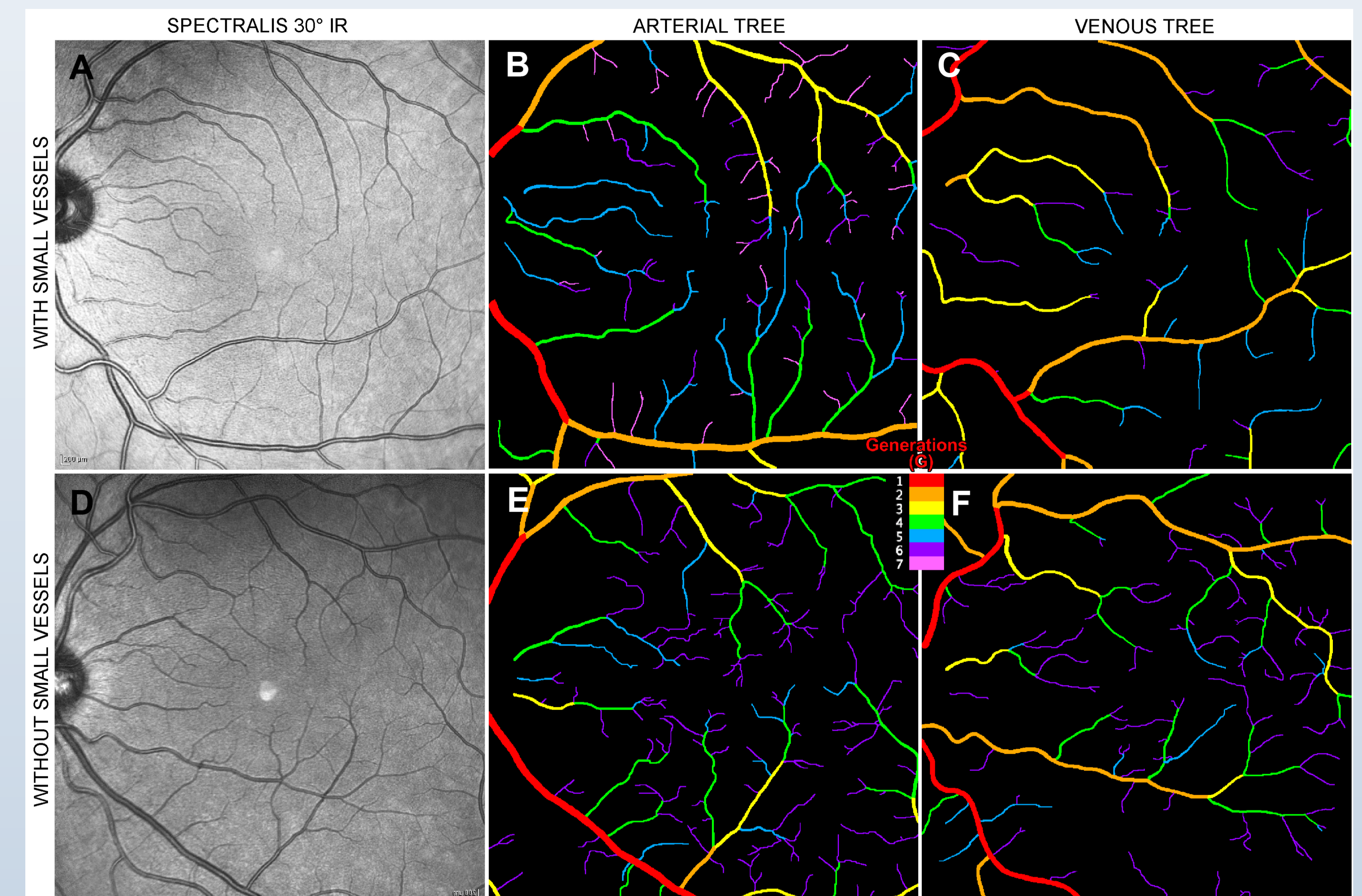


Figure 1 VESGEN Mapping and Detection of Two Distinct Populations in the HDT Retina

Arterial and venous trees were automatically analyzed by NASA's VESGEN software following extraction of vascular trees from Spectralis® 30 degree IR fundus images. The images were collected from both eyes of 6 subjects before and after 70 days of bed rest at 6 degree HDT. Two groups were identified by VESGEN analysis within the masked study population that are distinguished by the presence or absence of small veins ($G_{\geq 7}$). For example, $L_{\geq 7}$ and $A_{v\geq 7}$ are $2.7 \pm 1.3 \text{ E-4 micron/micron}^2$ and $7.2 \pm 3.6 \text{ E-4 micron}^2/\text{micron}^2$ in 6 retinas (a-b), and 0 in the other 6 retinas (d-e). However, the space-filling properties of the entire venous trees were remarkably uniform by all parameters, such as $D_f = 1.56 \pm 0.02$ for 6 retinas with $G_{\geq 7}$ and 1.55 ± 0.02 for retinas without $G_{\geq 7}$. No small arteries ($G_{\geq 7}$) were detected in either group (c, f).

REFERENCES

1. Mader TH, Gibson CR, Pass AF, Kramer LA, Lee AG, Fogarty J, Tarver WJ, Dervay JP, Hamilton DR, Sargsyan A, Phillips JL, Tran D, Lipsky W, Choi J, Stern C, Kuyumjian R and Polk JD (2011) *Ophthalmology* 118:2058-2069.
2. Parsons-Wingerter PA,* Radhakrishnan K,* Vickerman MB and Kaiser PK (2010) . *Invest Ophthalmol Vis Sci* 51(1):498-507 2010. *Co-authors contributed equally.
3. Taibbi G, Cromwell RL, Zanello SB, Yarbough PO, Ploutz-Snyder RJ, Godley BF, Vizzeri G. Ocular Outcomes Comparison Between 14- and 70-Day Head-Down-Tilt Bed Rest. *Invest Ophthalmol Vis Sci.* (2016) Feb 1;57(2):495-501. doi: 10.1167/iovs.15-18530.

Author Disclosure Information: P.A. Parsons-Wingerter, Code P (Patent Application), R.J. Vyas, none; S. Raghunandan, none; A. Vu, none; S.B. Zanello, none; R. Ploutz-Snyder, none; G. Taibbi, none; G. Vizzeri, none. The study is supported by a National Research Award by the NASA Human Research Program to PPW, RP-S, GT, GV.