



KBRwyle



UCLA Stein Eye Institute

Assessment of Intraocular and Systemic Vasculature Pressure Parameters in Simulated Microgravity with Thigh Cuff Countermeasure

Alex S. Huang¹, Siva Balasubramanian¹, Tudor Tepelus¹, Jaya Satta¹, Srinivas Satta¹, Michael B. Stenger², Stuart M.C. Lee³, Steve S. Laurie³, John Liu⁴, and Brandon R. Macias³

1) Doheny Eye Institute and UCLA Department of Ophthalmology, David Geffen School of Medicine, Los Angeles, CA. 2) NASA Johnson Space Center, Houston, Texas 3) KBRwyle, Houston, Texas. 4) Shiley Eye Institute and UCSD Department of Ophthalmology, San Diego, CA

Introduction

Changes in vision have been well documented among astronauts during and after long-duration space flight. One hypothesis is that the space flight induced headward fluid alters posterior ocular pressure and volume and may contribute to visual acuity decrements. Therefore, we evaluated venoconstrictive thigh cuffs as a potential countermeasure to the headward fluid shift-induced effects on intraocular pressure (IOP) and cephalic vascular pressure and volumes.

Methods

In this prospective comparative study (UCLA IRB 15-002011), 20 healthy participants (12 males; 8 females) were studied during a tilt protocol in the following sequential positions (10 min each): seated, supine, 15° head-down tilt (HDT), and 15° HDT with bilateral venoconstrictive thigh cuffs inflated to 60 mm Hg (HDTC). IOP, internal jugular vein (IJV) cross-sectional area, blood pressure (BP) and heart rate (HR) were measured in each position. Mean arterial pressure (MAP) was calculated as: $DBP + (SBP - DBP) / 3$. SBP and DBP = systolic and diastolic blood pressure respectively. Ocular Perfusion pressure (OPP) was calculated as: seated = $0.68(MAP - IOP)$, supine $0.88(MAP - IOP)$, and HDT $(MAP + 19.7 - IOP)$. Vertical subfoveal choroid thickness was measured using optical coherence (OCT) images obtained by the Heidelberg Spectralis mounted on a FLEX module that allowed for imaging in multiple positions throughout the study.

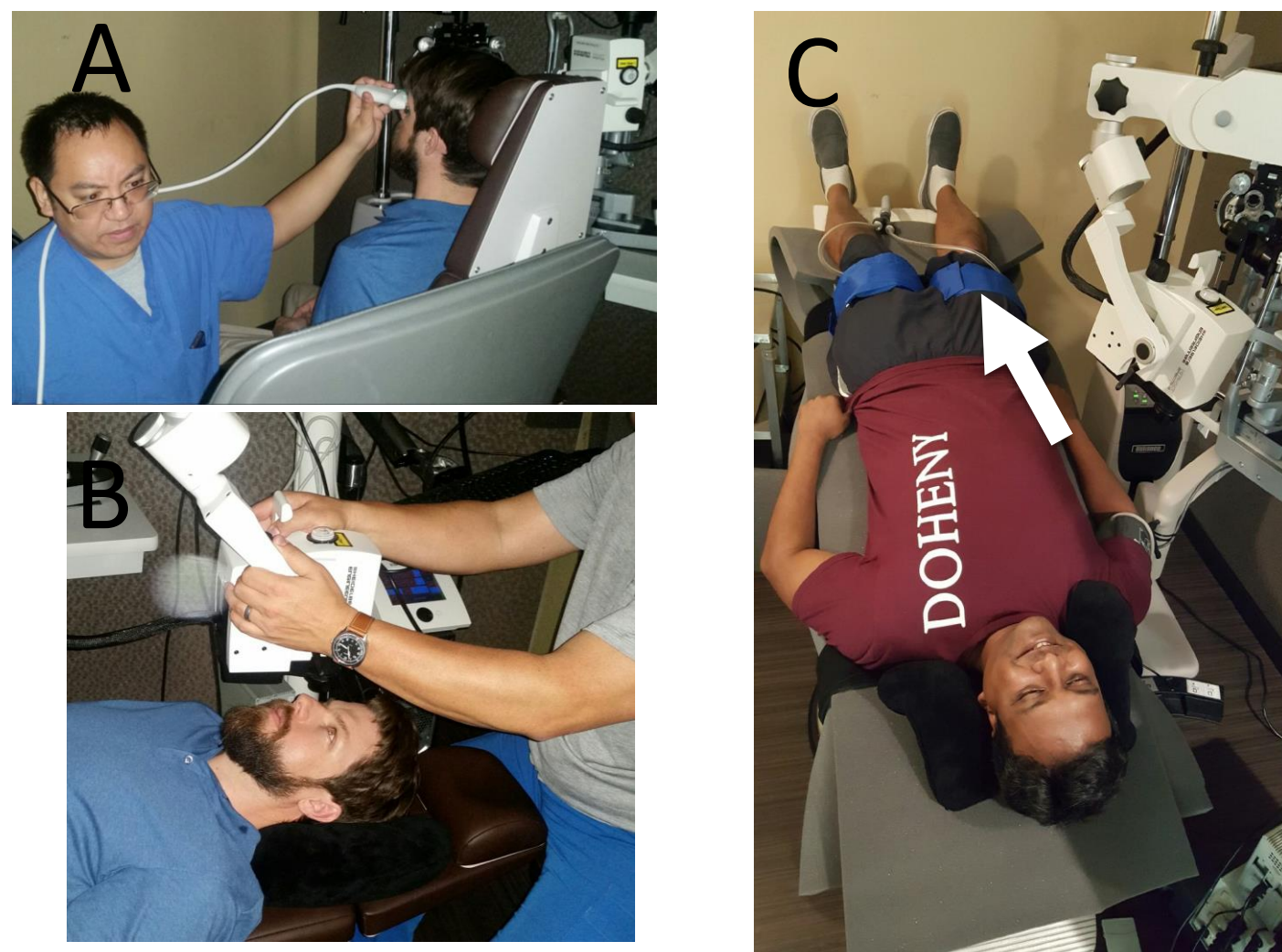

Figure 1. Testing in Multiple Positions (A) Seated position with example of ocular ultrasound. (B) Supine position with ophthalmic imaging. (C) Head-down tilt (HDT) position achieved by patient lying on a triangular foam with feet up. Blue thigh cuffs occlude femoral venous blood flow (white arrow).

Conclusions

- Moving from seated to supine to head-down tilt led to increased IOP and subfoveal choroid thickness that was reversed by the venoconstrictive cuff.
- Brachial MAP and HR decreased with progressive head-down tilt. This may be consistent with changes with sympathetic tone.
- OPP increased with progressive head-down tilt and did not change with cuff. Observed changes may be secondary to deriving OPP from the surrogate measure of MAP with mathematical corrections.
- IJV cross-sectional area increased as expected when moving from seated to supine to head-down tilt and began to diminish with cuff but was not statistically significant.

	Condition	Time
1	Upright (seated)	10 min
2	Supine	10 min
3	15° HDT	10 min
4	15° HDT + Cuff	10 min

Table. Acute Study Protocol.

HDT = 15 degree head-down tilt; Cuff = countermeasure

Results

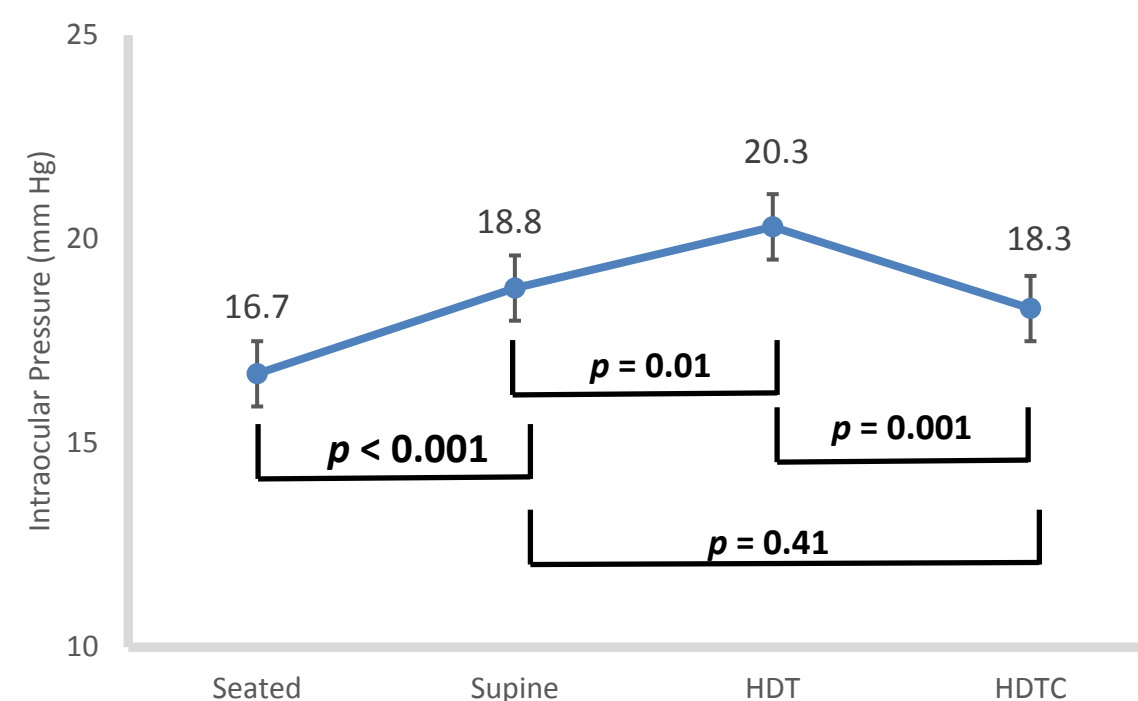


Figure 2. IOP During Each Study Condition (Mean +/- SE).

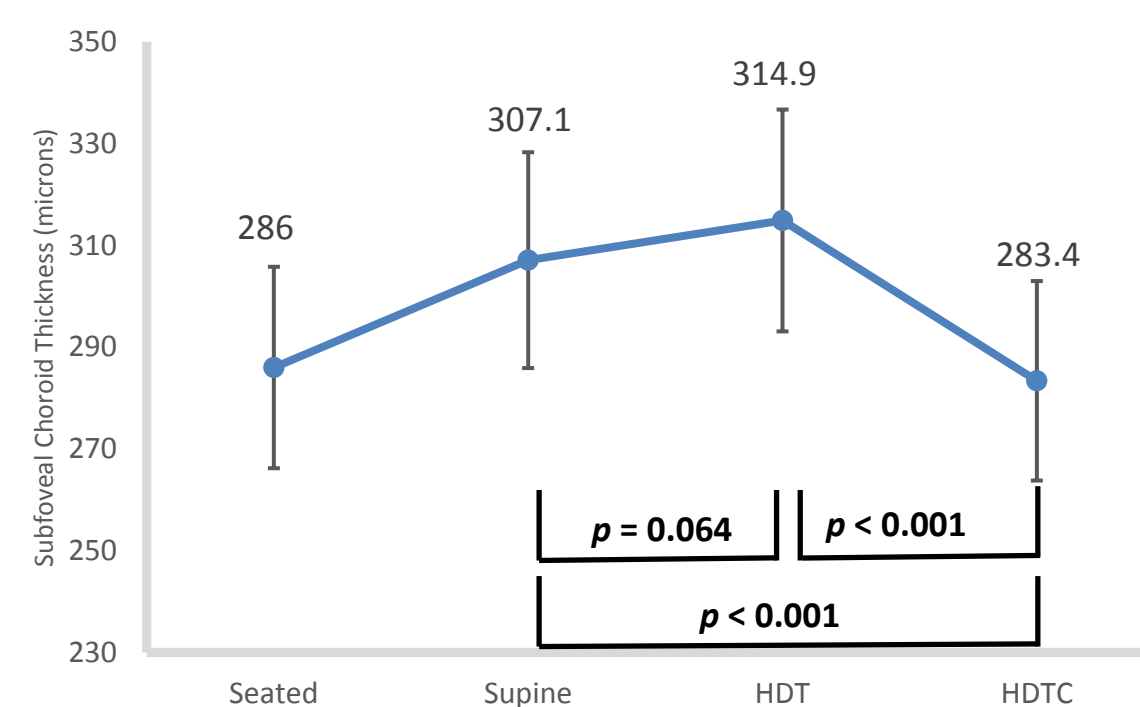


Figure 3. Subfoveal Choroid Thickness During Each Study Condition (Mean +/- SE).

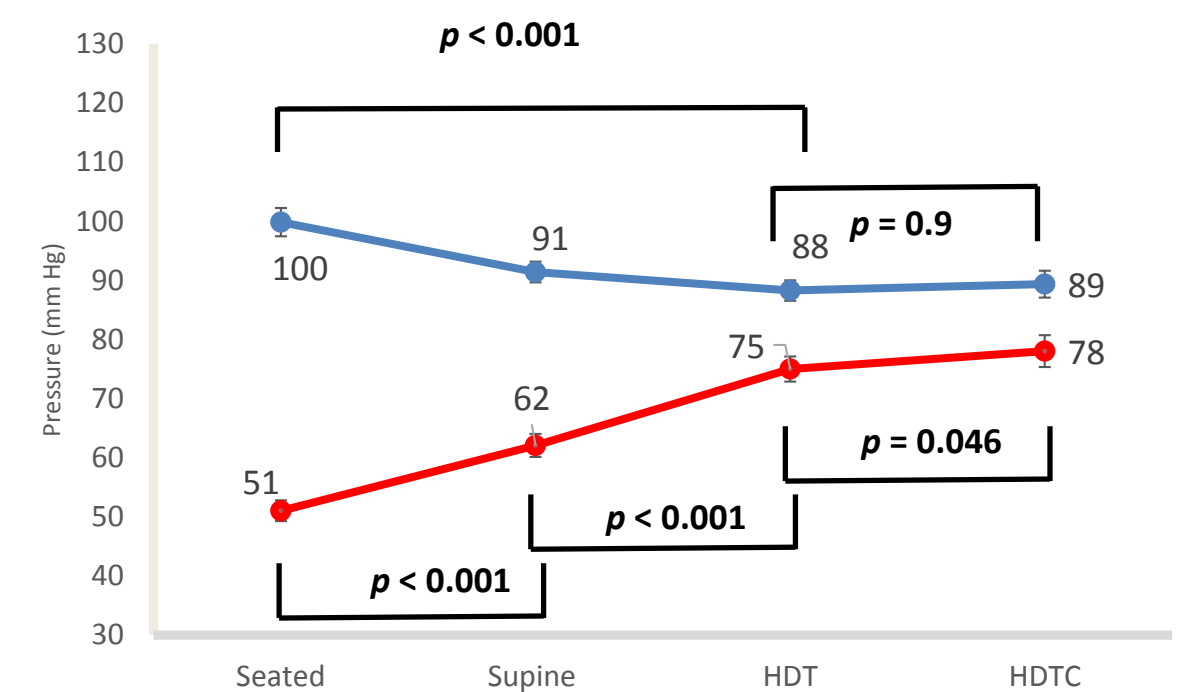


Figure 4. MAP and OPP During Each Study Condition (Mean +/- SE).

MAP = diastolic BP + (systolic BP - diastolic BP)/3

OPP (seated) = $(0.66 \times \text{MAP}) - \text{IOP}$ OPP (HDT) = $\text{MAP} + 7 - \text{IOP}$

OPP (supine) = $(0.88 \times \text{MAP}) - \text{IOP}$

Liu et al J Ocu Pharm Ther 2003

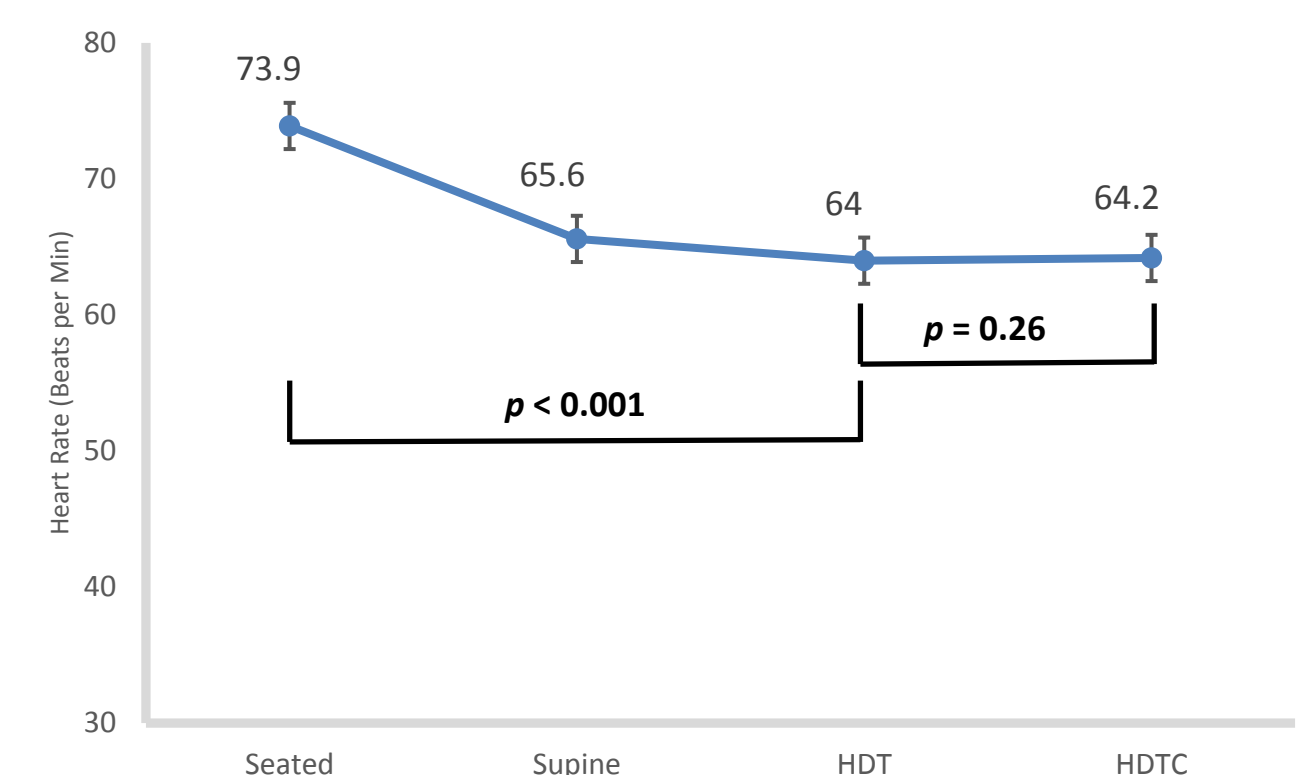


Figure 5. HR During Each Study Condition (Mean +/- SE).

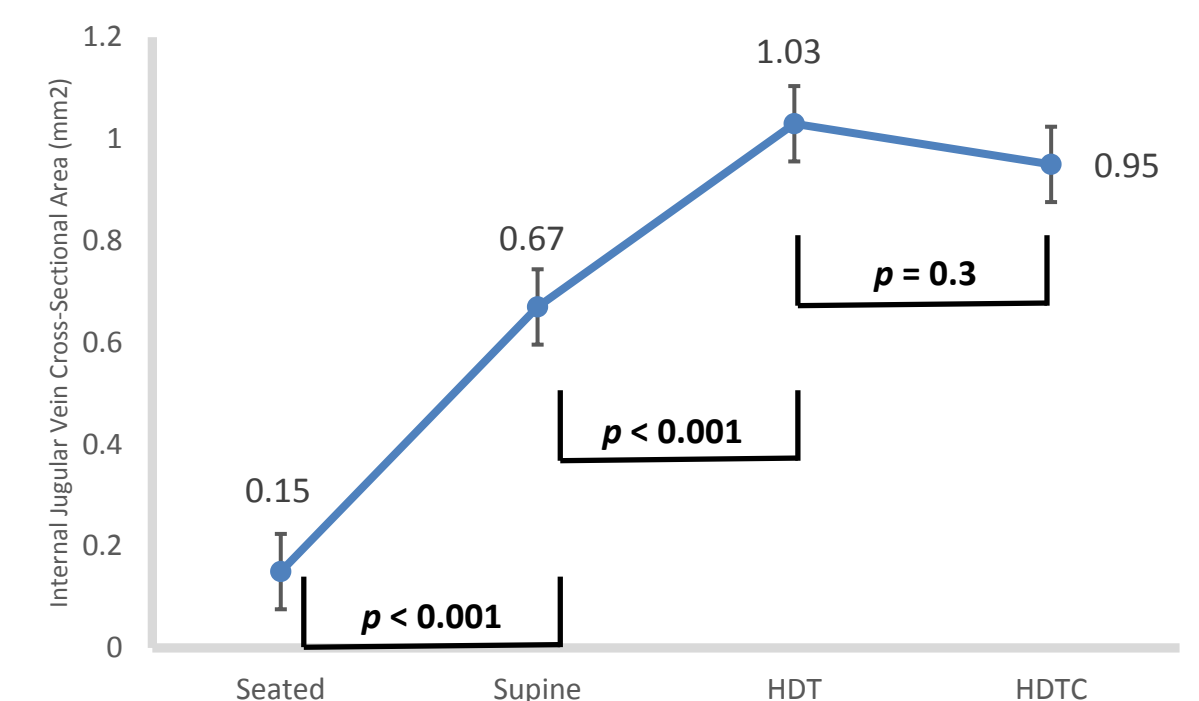


Figure 6. IJV Cross-Sectional Area During Each Study Condition (Mean +/- SE).

Acknowledgements

This work was supported by NSBRI (Validation of a Cephalad Fluid Shift Countermeasure; PI = Brandon Macias).