



SANS-related ISS Hardware & Data

Tyson Brunstetter, OD, PhD, MBA, FAAO, FAsMA
CAPT, MSC (AsO), U.S. Navy
Deputy SANS Clinical Lead
Space and Occupational Medicine Branch (SD3)
NASA Johnson Space Center


OCT2 Technical Interchange Meeting (TIM)
Houston, TX – 13 June 2018



BACKGROUND

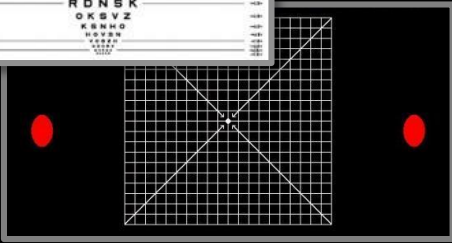



- 55 ISS expedition missions have been completed (since 2000)
- NASA Eye Exams
 - Astronaut eyes have always been *eval'd* pre- & post-flight
 - But limited & inconsistent prior to 2005
 - Initial ISS (in-flight) testing capability:
 - Ophthalmoscope, paper visual acuity (VA) chart, Amsler grid
- **Sentinel SANS (VIIP) case discovered post-flight in 2005**
 - *Optic disc edema* (grade 1) OD/OS
 - Refractive error shift w/ decreased visual acuity @ distance & near
 - Choroidal folds & cotton wool spot OD
- NASA ocular data collection evolved...and continues to evolve...
 - **Feb 2010: Standardized terrestrial & on-orbit monitoring initiated w/ Exp 23 (i.e., "Eye MEDB 1.10")**

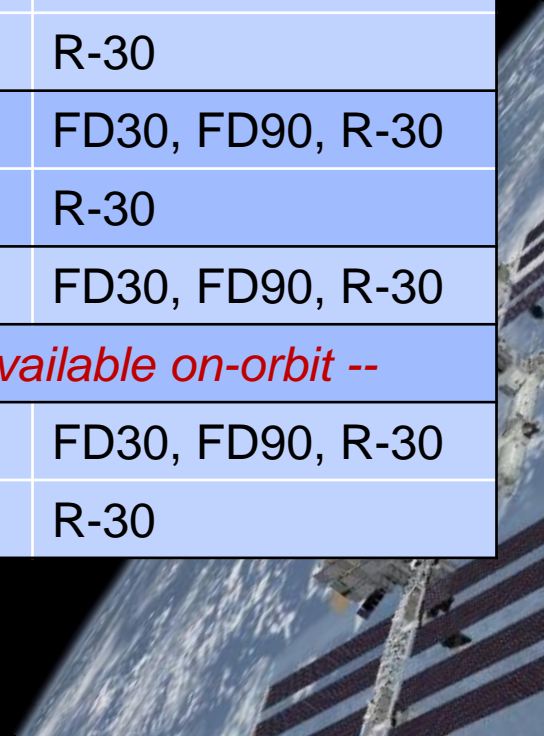



ON-ORBIT MEDB 1.10 OVERVIEW



Test	Crewmembers	Frequency
Visual Acuity, Amsler Grid, Questionnaire	USOS	FD30, FD90, R-30
	Roscosmos	R-30
Fundoscopy	USOS	FD30, FD90, R-30
	Roscosmos	R-30
Optical Coherence Tomography (OCT)	USOS	FD30, FD90, R-30
	Roscosmos	R-30
Tonometry	ESA only	FD30, FD90, R-30
Threshold Visual Field (VF)	<i>-- TBD; not yet available on-orbit --</i>	
Ocular Ultrasound	USOS	FD30, FD90, R-30
	Roscosmos	R-30





ON-ORBIT MEDB 1.10 OVERVIEW



Test	Crewmembers	Frequency
Visual Acuity, Amsler Grid, Questionnaire	USOS	FD30, FD90, R-30
	Roscosmos	R-30
Fundoscopy	USOS	FD30, FD90, R-30
	Roscosmos	R-30
Optical Coherence Tomography (OCT)	USOS	FD30, FD90, R-30
	Roscosmos	R-30
Tonometry	ESA only	FD30, FD90, R-30
Threshold Visual Field (VF)	<i>-- TBD; not yet available on-orbit --</i>	
Ocular Ultrasound	USOS	FD30, FD90, R-30
	Roscosmos	R-30

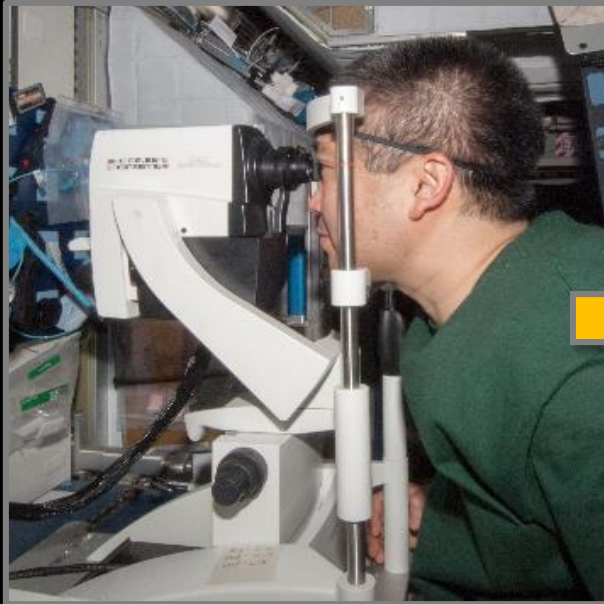



ON-ORBIT MEDB 1.10 OVERVIEW

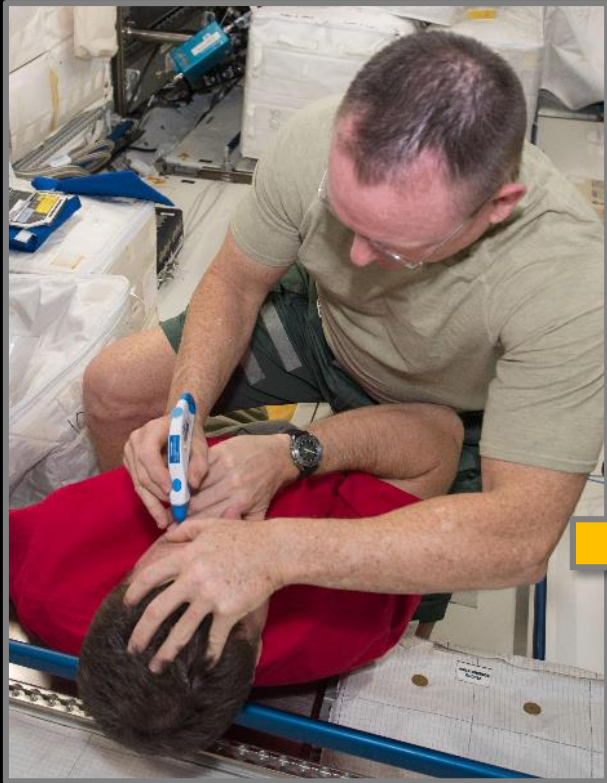

Test	Crewmembers	Frequency
Visual Acuity, Amsler Grid, Questionnaire	USOS	FD30, FD90, R-30
	Roscosmos	R-30
Fundoscopy	USOS	FD30, FD90, R-30
	Roscosmos	R-30
Optical Coherence Tomography (OCT)	USOS	FD30, FD90, R-30
	Roscosmos	R-30
Tonometry	ESA only	FD30, FD90, R-30
Threshold Visual Field (VF)	<i>-- TBD; not yet available on-orbit --</i>	
Ocular Ultrasound	USOS	FD30, FD90, R-30
	Roscosmos	R-30






ON-ORBIT MEDB 1.10 OVERVIEW



Test	Crewmembers	Frequency
Visual Acuity, Amsler Grid, Questionnaire	USOS	FD30, FD90, R-30
	Roscosmos	R-30
Fundoscopy	USOS	FD30, FD90, R-30
	Roscosmos	R-30
Optical Coherence Tomography (OCT)	USOS	FD30, FD90, R-30
	Roscosmos	R-30
Tonometry	ESA only	FD30, FD90, R-30
Threshold Visual Field (VF)	<i>-- TBD; not yet available on-orbit --</i>	
Ocular Ultrasound	USOS	FD30, FD90, R-30
	Roscosmos	R-30



ON-ORBIT MEDB 1.10 OVERVIEW

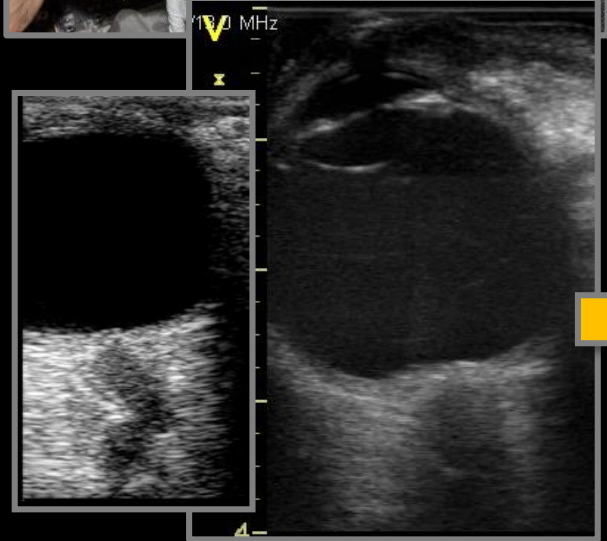
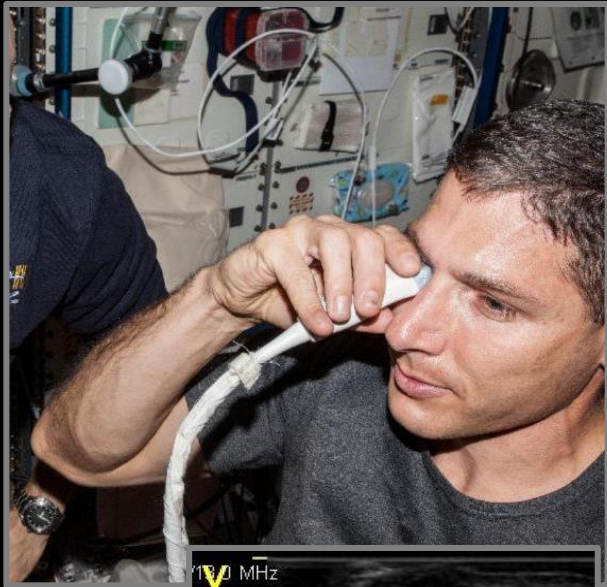

Example VF
Not Astronaut Data

Test	Crewmembers	Frequency
Visual Acuity, Amsler Grid, Questionnaire	USOS	FD30, FD90, R-30
	Roscosmos	R-30
Fundoscopy	USOS	FD30, FD90, R-30
	Roscosmos	R-30
Optical Coherence Tomography (OCT)	USOS	FD30, FD90, R-30
	Roscosmos	R-30
Tonometry	ESA only	FD30, FD90, R-30
Threshold Visual Field (VF)	<i>-- TBD; not yet available on-orbit --</i>	
Ocular Ultrasound	USOS	FD30, FD90, R-30
	Roscosmos	R-30



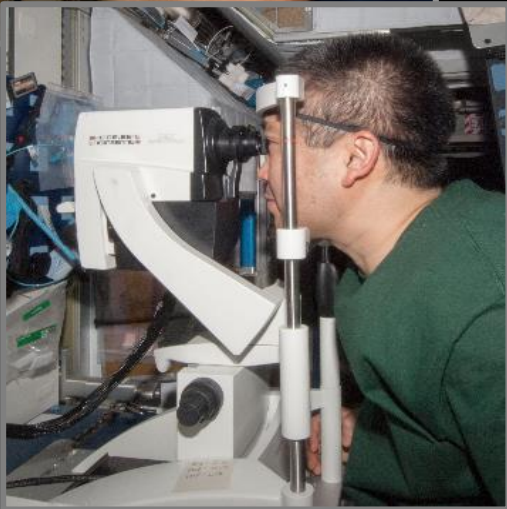ON-ORBIT MEDB 1.10 OVERVIEW



Test	Crewmembers	Frequency
Visual Acuity, Amsler Grid, Questionnaire	USOS	FD30, FD90, R-30
	Roscosmos	R-30
Fundoscopy	USOS	FD30, FD90, R-30
	Roscosmos	R-30
Optical Coherence Tomography (OCT)	USOS	FD30, FD90, R-30
	Roscosmos	R-30
Tonometry	ESA only	FD30, FD90, R-30
Threshold Visual Field (VF)	<i>-- TBD; not yet available on-orbit --</i>	
Ocular Ultrasound	USOS	FD30, FD90, R-30
	Roscosmos	R-30



ON-ORBIT MEDB 1.10 OVERVIEW



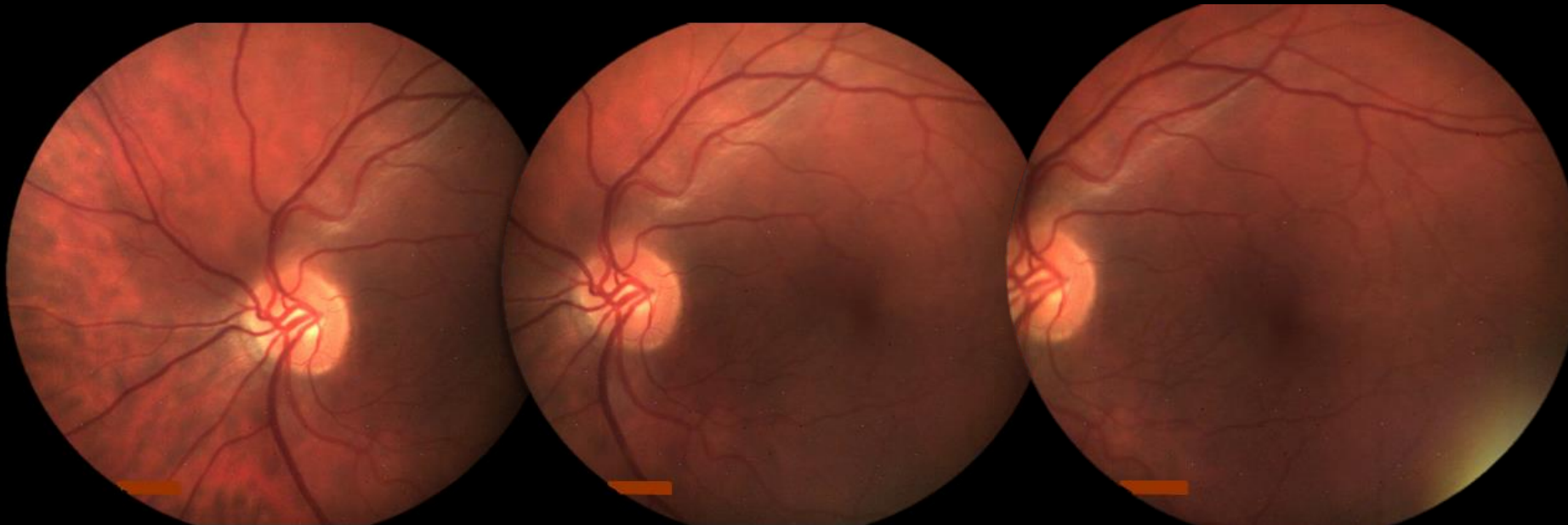
Test	Crewmembers	Frequency
Visual Acuity, Amsler Grid, Questionnaire	USOS	FD30, FD90, R-30
	Roscosmos	R-30
Fundoscopy	USOS	FD30, FD90, R-30
	Roscosmos	R-30
Optical Coherence Tomography (OCT)	USOS	FD30, FD90, R-30
	Roscosmos	R-30
Tonometry	ESA only	FD30, FD90, R-30
Threshold Visual Field (VF)	<i>-- TBD; not yet available on-orbit --</i>	
Ocular Ultrasound	USOS	FD30, FD90, R-30
	Roscosmos	R-30



ON-ORBIT FUNDOSCOPY



- Current device: OIS “Merge” fundoscope
 - No longer manufactured or supported
 - Not originally compatible w/ ISS ZBook; however, NASA engineers developed a temporary solution
 - Viable until Microsoft ends support for Windows 7: *Jan 2020*. At that time, device must be retired
 - Replacement devices being pursued
 - OCT2 “MultiColor Imaging” may be a partial solution, but likely not a complete one (NOTE: *This topic will be discussed tomorrow...*)



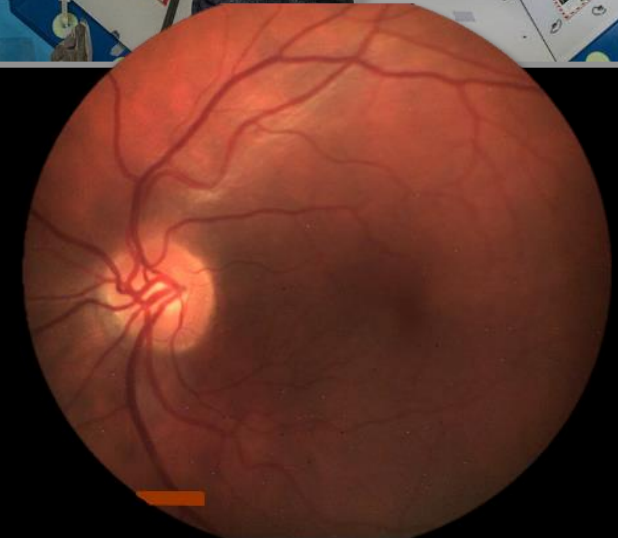


ON-ORBIT FUNDOSCOPY: DATA



FINDINGS	Normal	Clear	Normal	Clear	COMMENTS
	RIGHT EYE		LEFT EYE		
Optic Nerve:	<input type="text"/>	<input type="text"/>	<input type="text"/>	<input type="text"/>	
Disc Edema:	<input type="text"/>	<input type="text"/>	<input type="text"/>	<input type="text"/>	
Peripapillary Area:	<input type="text"/>	<input type="text"/>	<input type="text"/>	<input type="text"/>	
Macula:	<input type="text"/>	<input type="text"/>	<input type="text"/>	<input type="text"/>	
Post Pole:	<input type="text"/>	<input type="text"/>	<input type="text"/>	<input type="text"/>	
Periphery of Fundus:	<input type="text"/>	<input type="text"/>	<input type="text"/>	<input type="text"/>	
Choroidal Folds:	<input type="text"/>	<input type="text"/>	<input type="text"/>	<input type="text"/>	
Location:	<input type="text"/>	<input type="text"/>	<input type="text"/>	<input type="text"/>	
Cotton Wool Spots:	<input type="text"/>	<input type="text"/>	<input type="text"/>	<input type="text"/>	
Location:	<input type="text"/>	<input type="text"/>	<input type="text"/>	<input type="text"/>	
Retinal Hemorrhage:	<input type="text"/>	<input type="text"/>	<input type="text"/>	<input type="text"/>	
Location:	<input type="text"/>	<input type="text"/>	<input type="text"/>	<input type="text"/>	
Vasculature:	<input type="text"/>	<input type="text"/>	<input type="text"/>	<input type="text"/>	
Spontaneous Venous Pulsations (SVP):	<input type="text"/>	<input type="text"/>	<input type="text"/>	<input type="text"/>	
General Impression:	<input type="text"/>	<input type="text"/>	<input type="text"/>	<input type="text"/>	
Cup to Disc Ratio:	RE <input type="text"/> / <input type="text"/>		LE <input type="text"/> / <input type="text"/>		

LEGEND
0 = Clear 1 = Trace 2 = Mild 3 = Moderate 4 = Severe





ON-ORBIT OCT



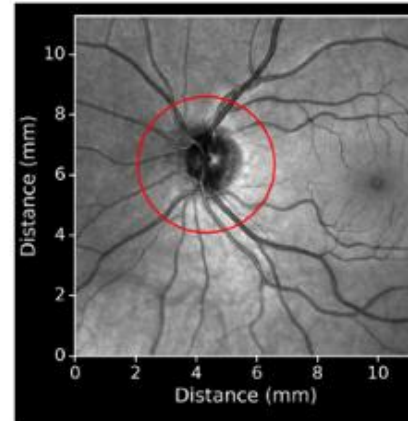
Device: Heidelberg OCT

- 6 scans/eye (nominally)
- One w/ Enhanced Depth Imaging (EDI)

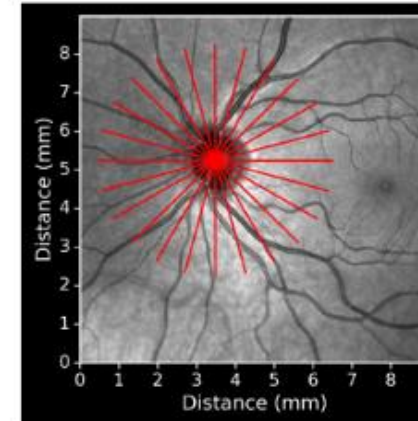


Nominal OCT Protocol

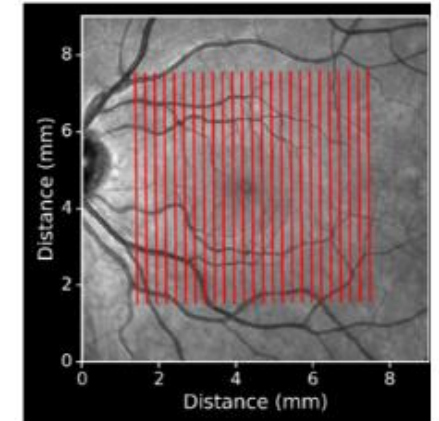
Circular ONH Scan



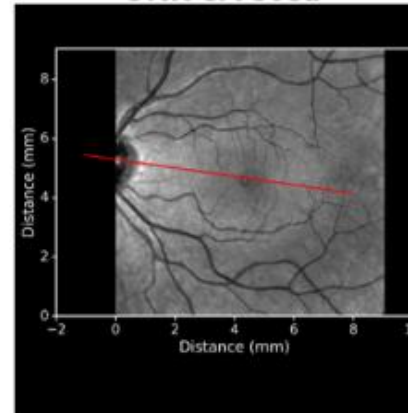
Radial ONH Scan



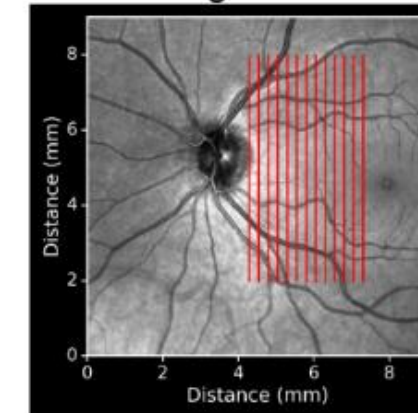
Vertical Macula Scan



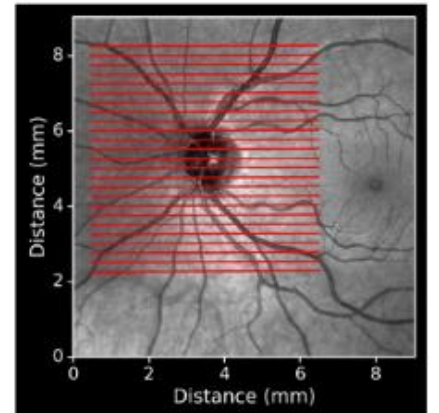
Single Scan through ONH & Fovea



Vertical Scan Between Disk Edge & Fovea



Horizontal ONH Scan

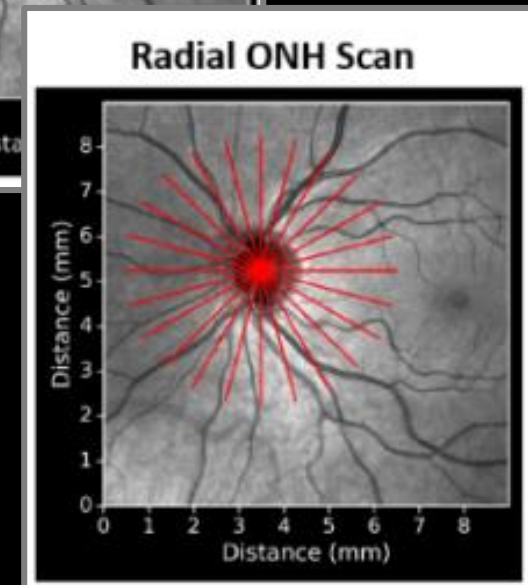
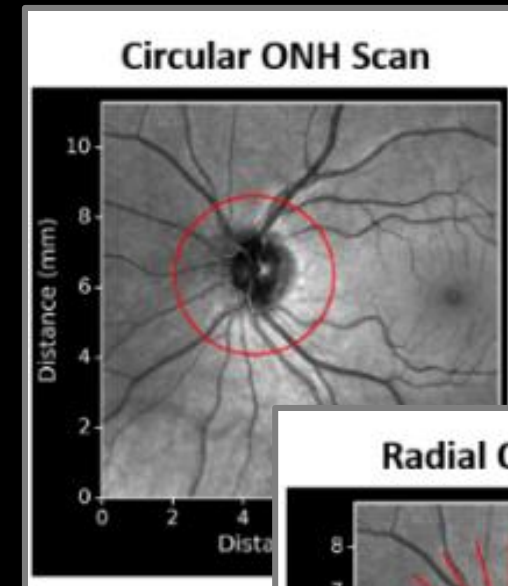




ON-ORBIT OCT: DATA



- MEDB OCT analyses performed by Nimesh Patel, OD, PhD
- Typical analysis includes, per eye:
 - **Retinal Nerve Fiber Layer (rNFL) thickness**
 - 6 sectors + average + comments
 - Source: Circle scan
 - **Total Retinal Thickness (TRT)**
 - 4 quadrants @ 0-250 & 250-500 microns from disc + comments
 - Source: Radial scan
 - **Minimum Rim Width (MRW)**
 - 4 quads + comments
 - Source: Radial scan
 - **Bruch's Membrane Opening (BMO)**
 - Horizontal + vertical + Retinal pigment epithelium (RPE) angle
 - Source: Radial scan

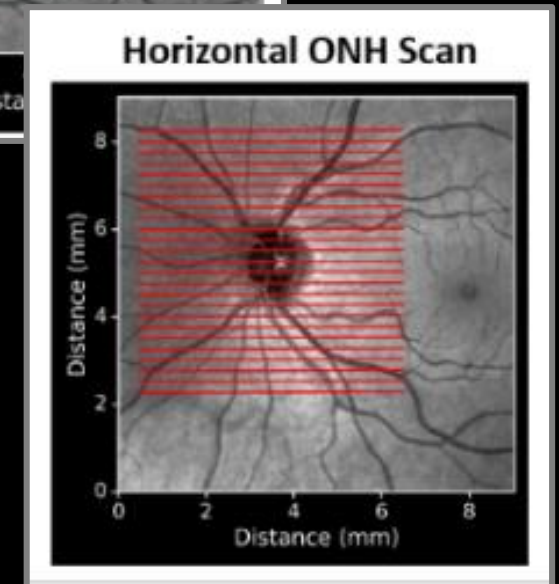
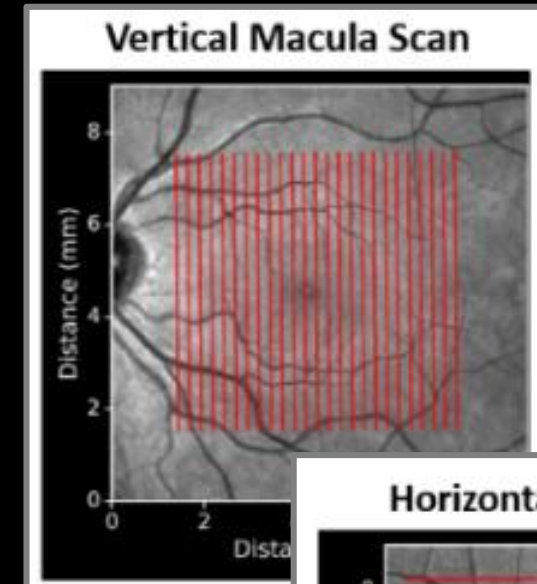




ON-ORBIT OCT: DATA



- Typical analysis includes, per eye: *(cont.)*
 - **Macula**
 - Avg thickness @ 4 quads btwn 1-3mm & 3-6mm + comments
 - Source: Macular block scan
 - **Choroid**
 - Choroidal folds description – Sub-macular & peripapillary
 - Choroidal thickness (avg) – Sub-macular & peripapillary
 - General impressions
 - Source: Macular + Disc-centered block scans
 - **Overall impressions**
 - Including changes/trends, highlights, etc.
 - **Plan & Recommendations**





Questions / Comments?

CAPT Tyson Brunstetter, MSC (AsO), USN
COM: 281-792-7705
Email: Tyson.J.Brunstetter@nasa.gov

