https://ntrs.nasa.gov/search.jsp?R=19740008716 2018-07-24T05:45:30+00:00Z

AD-770 292

# ULTRASTRUCTURAL PATHOGENESIS OF LESIONS PRODUCED BY EXPOSURE TO OXYGEN DIFLUORIDE WITH CORRELATIVE LIGHT MICROSCOPY

Gladys Harrison, et al

National Aeronautics and Space Administration
Moffett Field, California

July 1973

DISTRIBUTED BY:

NTIS
National Technical Information Service
U. S. DEPARTMENT OF COMMERCE
5285 Port Royal Road, Springfield Va. 22151

AD-770292

SECURITY CLASSIFICATION OF THIS PAGE (When Data Entered)

| REPORT DOCUMENTATION PAGE | | READ INSTRUCTIONS BEFORE COMPLETING FORM |
|---|---|---|
| 1. REPORT NUMBER<br>AMRL-TR-72-107 | 2. GOVT ACCESSION NO. | 3. RECIPIENT'S CATALOG NUMBER |
| 4. TITLE (and Subtitle)<br>ULTRASTRUCTURAL PATHOGENESIS OF LESIONS PRODUCED BY EXPOSURE TO OXYGEN DIFLUORIDE WITH CORRELATIVE LIGHT MICROSCOPY. | | 5. TYPE OF REPORT & PERIOD COVERED<br><br>6. PERFORMING ORG. REPORT NUMBER |
| 7. AUTHOR(s)<br>Gladys Harrison, PhD*<br>William Mackenzie, Lt Col USAF, VC** | | 8. CONTRACT OR GRANT NUMBER(s)<br>MIPR FQ 7624-71-00003 |
| 9. PERFORMING ORGANIZATION NAME AND ADDRESS<br>National Aeronautics and Space Administration<br>Ames Research Center<br>Moffett Field, California 94035 | | 10. PROGRAM ELEMENT, PROJECT, TASK AREA & WORK UNIT NUMBERS<br>Project No. 6302<br>Task No. 630206<br>Work Unit No. 63020620 |
| 11. CONTROLLING OFFICE NAME AND ADDRESS<br>Aerospace Medical Research Laboratory, Aerospace Medical Division, Air Force Systems Command, Wright-Patterson Air Force Base, Ohio 45433. | | 12. REPORT DATE<br>July 1973<br>13. NUMBER OF PAGES<br>56 |
| 14. MONITORING AGENCY NAME & ADDRESS (if different from Controlling Office) | | 15. SECURITY CLASS. (of this report)<br>Unclassified<br>15a. DECLASSIFICATION/DOWNGRADING SCHEDULE |

16. DISTRIBUTION STATEMENT (of this Report)

Approved for public release; distribution unlimited.

17. DISTRIBUTION STATEMENT (of the abstract entered in Block 20, if different from Report)

18. SUPPLEMENTARY NOTES

*NASA
**Aerospace Medical Research Laboratory

19. KEY WORDS (Continue on reverse side if necessary and identify by block number)

$OF_2$
Pathogenesis
Ultrastructural

20. ABSTRACT (Continue on reverse side if necessary and identify by block number)

The lungs of rats exposed to $OF_2$ were examined by light and electron microscopy. The exposures were for 30 and 60 minutes to an average of 4.5 ppm $OF_2$, the minimal lethal dose. Animals were sacrificed after 30 (group 1) and 60 minutes (group 2) exposure and 1 (group 3) and 2 (group 4) hours following 60 minutes exposure. Lung tissue for microscopy was fixed by intratracheal instillation of phosphate buffered 10% formalin and routine paraffin embedding.

(Over)

DD FORM 1 JAN 73 1473 EDITION OF 1 NOV 65 IS OBSOLETE

SECURITY CLASSIFICATION OF THIS PAGE (When Data Entered)

Reproduced from best available copy.

Reproduced by
NATIONAL TECHNICAL INFORMATION SERVICE
U S Department of Commerce
Springfield VA 22151

Tissue for electron microscopy was fixed by immersion in 6% phosphate buffered glutaraldehyde followed by post-fixation in osmium with subsequent embedding in an epon/araldite mixture. Mild gross changes were observed in groups 3 and 4, but no light microscopic lesions were found. Alterations were noted in all four groups using electron microscopy. These were mostly indicative of fluid change and consisted of blebbing of the endothelial and epithelial layers of the alveolo-capillary wall and rarification of the cytoplasm of these cells. The lamellar bodies of the Type II cells showed an increasing and consistent loss of matrix structure and density. These fine structural changes increased in quantity and severity as time of exposure or post-exposure period increased.

# NOTICES

When US Government drawings, specifications, or other data are used for any purpose other than a definitely related Government procurement operation, the Government thereby incurs no responsibility nor any obligation whatsoever, and the fact that the Government may have formulated, furnished, or in any way supplied the said drawings, specifications, or other data, is not to be regarded by implication or otherwise, as in any manner licensing the holder or any other person or corporation, or conveying any rights or permission to manufacture, use, or sell any patented invention that may in any way be related thereto.

Organizations and individuals receiving announcements or reports via the Aerospace Medical Research Laboratory automatic mailing lists should submit the addressograph plate stamp on the report envelope or refer to the code number when corresponding about change of address or cancellation.

Do not return this copy. Retain or destroy.

Please do not request copies of this report from Aerospace Medical Research Laboratory. Additional copies may be purchased from:

National Technical Information Service
5285 Port Royal Road
Springfield, Virginia 22151

The experiments reported herein were conducted according to the "Guide for the Care and Use of Laboratory Animals," DHEW 73–23.

ACCESSION for
NTIS White Section
DDC Buff Section
UNANNOUNCED
JUSTIFICATION
BY
DISTRIBUTION/AVAILABILITY CODES
Dist. AVAIL. and/or SPECIAL

AIR FORCE/56780/9 November 1973 — 100

## FOREWORD

This study was initiated by the Pathology Branch, Toxic Hazards Division of the Aerospace Medical Research Laboratory, under Project 6302, "Toxic Hazards of Propellants and Materials," Task 630206, "Pathology of Toxic Injury." The research was performed under MIPR FQ 7624-71-00003 with NASA, Ames Research Center, Moffett Field, California.

Dr. Gladys Harrison was the Principal Investigator for Ames Research Center. Lt Col William Mackenzie,* then Chief of Pathology Branch, was the initial Contract Monitor for the Aerospace Medical Research Laboratory and was succeeded by Maj Ernest E. McConnell of the Pathology Branch. Research was initiated in March, 1971 and completed in October, 1972.

The authors gratefully acknowledge the technical support of the enlisted personnel at the Aerospace Medical Research Laboratory and the personnel of Systemed Corporation.

This technical report has been reviewed and is approved.

A. A. Thomas, MD
Director
Toxic Hazards Division
Aerospace Medical Research Laboratory

*Lt Col William Mackenzie is presently assigned to the Veterinarian Sciences Division, SAM, AMD, Brooks Air Force Base, Texas 78235.

## INTRODUCTION

Oxygen difluoride is a strong oxidizing agent of considerable interest as a rocket fuel component. However, there is substantial hazard to persons involved in handling it. The first demonstration of inhalation toxicity of $OF_2$ was reported by La Belle in 1945 (ref. 11). Since this time other workers have determined lethal dose concentrations for monkeys (ref. 6), dogs (ref. 6), rats (refs. 5, 6, 12), and guinea pigs (ref. 5). When histological pathology was reported, such things as pulmonary edema, pneumonia, and damage to the alveolar epithelium and to some extent the bronchiolar epithelium (ref. 12) were noted.

In most cases of sublethal concentrations, there was little or no effect until some hours later, at which time the animal developed severe respiratory symptoms and often died. This led Dost, et al. (ref. 7) to postulate, based on the solubility of oxygen difluoride, that this gas passes through the cell membranes and acts internally to destroy the cell.

Since intracellular changes and changes in the layers of the alveolo-capillary wall are impossible to visualize with light microscopic techniques, it seemed appropriate to study a group of animals exposed to oxygen difluoride using the greater magnification available with the electron microscope.

## MATERIALS AND METHODS

White laboratory rats were randomly divided into groups of 10. Immediately prior to the exposure, half the animals in each experimental group were injected with 1 cc of 3% ferritin solution via the femoral vein under local anesthetic.

Exposures were made in a Rochester exposure chamber with prediluted $OF_2$ gas as previously described (ref. 6). This chamber was modified so that rats were held in two smaller chambers, each of which could be independently removed without altering the exposure. $OF_2$ concentrations were continually monitored with a MSA billionaire. The attempted levels of exposure were the 60-minute LC/50, 2.6 ppm (ref. 6). Actual levels as measured during exposure were a high of 5.3 ppm, a low of 2.6, and an average of 4.5, the minimal lethal

dose (ref. 6) The exposures for each group were:

| Experimental Group | Exposure Length | Sacrificed |
|---|---|---|
| 1 | 30 minutes | Immediately |
| 2 | 60 minutes | Immediately |
| 3 | 60 minutes | 1 hr. post-exp. |
| 4 | 60 minutes | 2 hr. post-exp. |

| Control Group | Sacrificed |
|---|---|
| C1 | Not injected immediately. |
| C2 | 30 minutes after injection. |
| C3 | 60 minutes |
| C4 | 120 minutes |
| C5 | 180 minutes |

To allow for adequate time to harvest and process tissue, two exposures were made on succeeding days. Groups 1 and 3 were exposed on the first day and 2 and 4 on the second day. Four injected and two uninjected controls were killed the first day and four injected controls, the second day.

In each group, 6 of the 10 animals were randomly selected for study. At necropsy, animals were anesthetized with intraperitoneal injection of pentobarbital. The thoracic cage was opened, the right apical lobe was ligated and removed for electron microscopy. The remaining lung was slowly re-expanded with phosphate buffered 10% formalin to just less than its original volume *in situ* using a syringe and blunted 20 G hypodermic needle. The trachea was ligated and the heart, lung, esophagus, and trachea removed en masse and suspended under 10% phosphate buffered formalin. Heads, kidneys, and livers were also fixed in formalin.

Tissues were prepared for light microscopy using standard methods of paraffin embedding and consisted of coronal sections of lung, kidney, and heart, coronal sections of the head through the middle ear and the nasal cavity, and a piece of liver. Heads were decalcified in RDO.* Slices were cut at 4 microns and stained with hematoxylin eosin. Tissues for electron microscopy were diced into 1 mm cubes and fixed in 6% glutaraldehyde in isotonic phosphate

*Dupate Kinetic Laboratory, Downer's Grove, Illinois.

buffer. Elapsed time form sacrifice to fixative was not more than 5 minutes and usually averaged 3 minutes. After 2 hours in glutaraldehyde, the tissues were postfixed for 1 hour in 1% osmium in acetate veronal buffer. They were then dehydrated in acetone and propylene oxide and embedded in an araldite/epon mixture of plastic. The resulting blocks were cut with diamond or glass knives using a Porter Blum II Microtome. Silver to dull grey sections were picked up on 75/300 slotted or 200-mesh grids, stained in lead followed by uranyl-acetate and viewed in a Philips EM-300 Electron Microscope.

## RESULTS

Of the four animals in each group not used, all of Group 2, 3, and 4 died within 3 days and those of Group 1 showed signs of respirat ory distress for 2 days and then recovered. Gross lesions occurred only in the Groups 3 and 4 animals and consisted of patchy areas of hyperemia and possibly edema. These were minimal but definite. Microscopic lesions were not found. Epithelium of the nasal mucosa was regular; the cilia were undisturbed (figs. 1a and b). The lungs also showed no changes in the ciliated epithelium of the air passages nor in the pneumocytes of the alveoli (figs. 1c and d). Even in Groups 3 and 4 where mild gross changes were apparent, no lesions were found.

Electron microscopic studies revealed a number of changes even as soon as 30 minutes of exposure. Changes occurred in the lining of small blood vessels, in the alveolar-capillary wall, and in the Type II cells. The changes were similar but patchy in occurrence at all stages, and as exposure of post-exposure period progressed, or the changes appeared more widespread and more extensive.

For the purposes of comparison, the first three figures are from control lung. The normal alveolar-capillary wall consisting of two very narrow cell layers separated by a thin basement membrane is shown in figure 2. A small blood vessel lined with normal appearing endothelial cells appears in figure 3. Figure 4 illustrates a normal Type II cell containing lamellar bodies with their structured interior of densely staining lamellae.

After 30 minutes exposure to oxygen difluoride, a number of alterations appeared. In a number of areas the endothelial cell appeared fluid filled (fig. 5 & 6) and the inner membrane protruded far into the lumen of the capillary. Fluid also appeared in the basement membrane between the epithelial and endothelial cell layers (fig. 7). There was blebbing and rarification of the cytoplasm of the epithelial cell (fig. 7) and occasionally seen was discontinuity of the epithelial cell (fig. 5). On the rare occasions that this was observed it was accompanied by indistinct

| | | |
|---|---|---|
| Figure 1a | Coronal section of the nasal cavity of a rat exposed to $OF_2$ for 60 minutes and sacrificed 1 hour post-exposure. No evidence of damage. | 9X |
| Figure 1b | High power of ciliated epithelium of rat in Figure 1a. Completely undamaged cilia. | 700X |
| Figure 1c | Low power micrograph of lung from rat sacrificed 1 hour following 1 hour exposure. Note lack of pathology. | 80X |
| Figure 1d | High magnification of lung shown in Figure 1c. | 325X |

1A

1B

1C



1D

Figure 2 Normal alveolar-capillary wall. Capillary lumen (CAP), alveolar space (ALV), endothelial cell (END), epithelial cell (EPI), red blood cell (RBC) basement membrane (BM). 31,250X

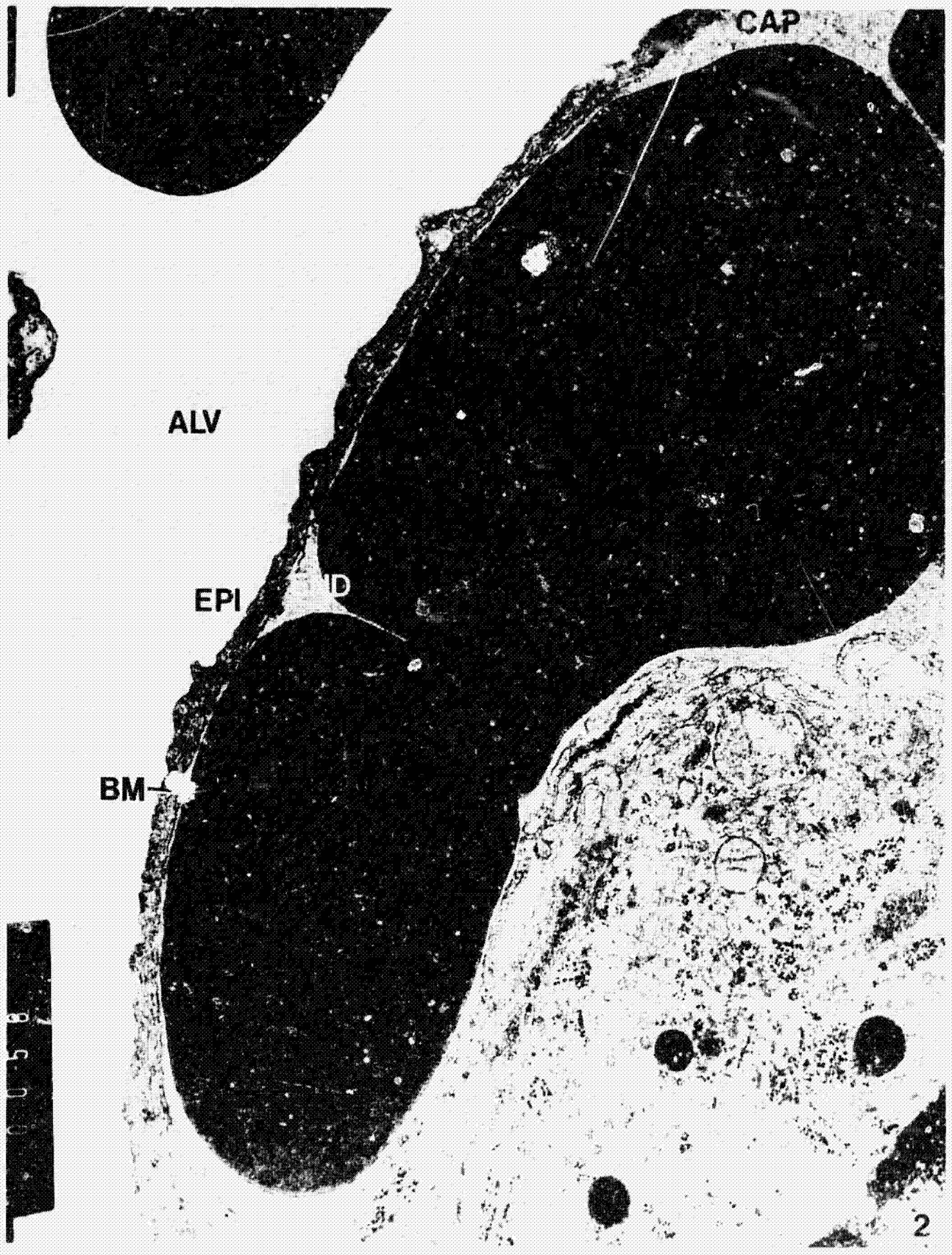
CAP
ALV
EPI
ID
BM
2

Figure 3 Normal small blood vessel. Elastic Tissue (EL), mitochondria (M). 25,600X

EL
M
EL
RBC
3

Figure 4 Normal lamellar body (LB) in a Type II Cell (II). 31,250X

4

Figure 5 30-minute exposure. Fluid in basement membrane. 31,250X

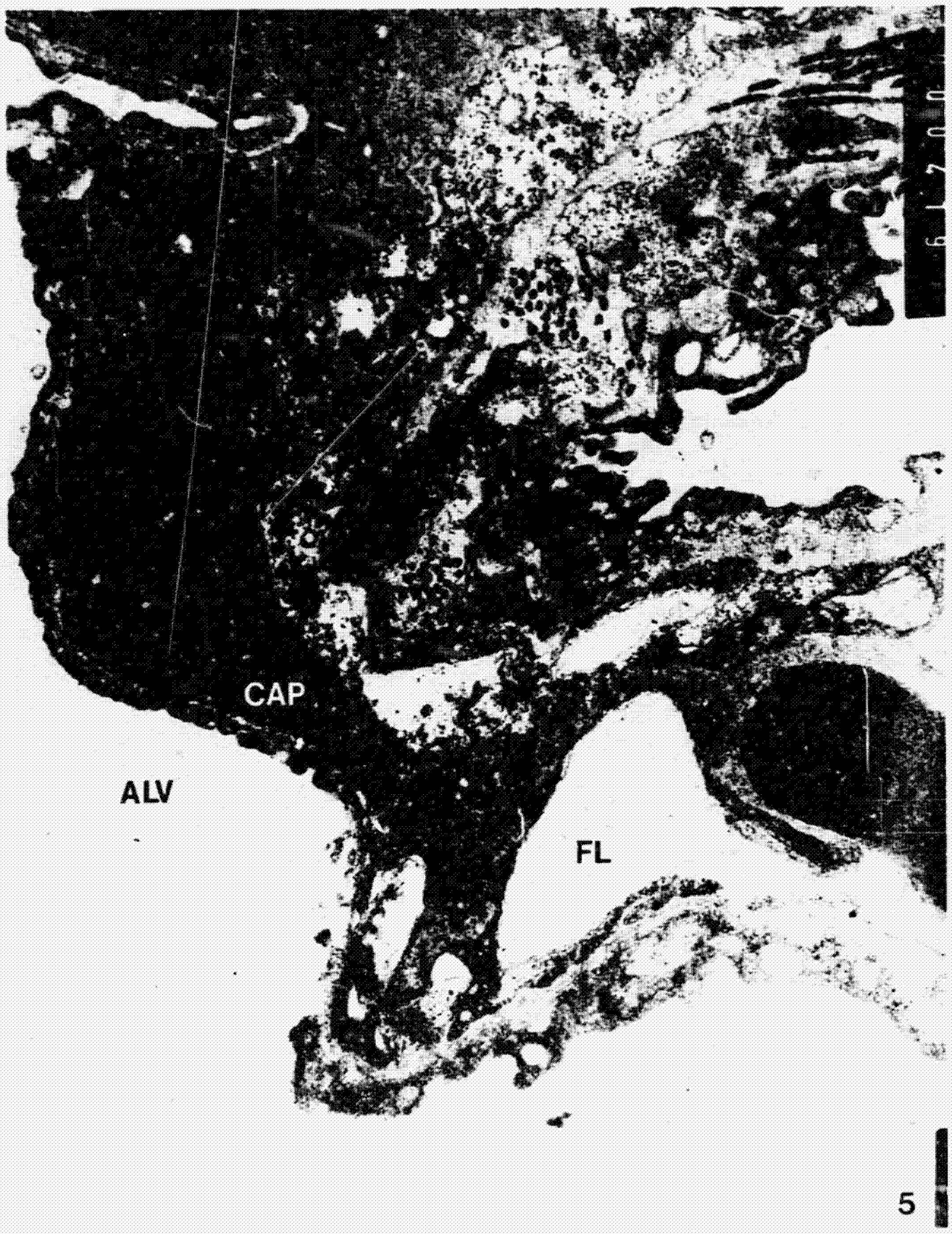
CAP
ALV
FL
5

Figure 6 30-minute exposure. Fluid in endothelial cell. Bleb occludes part of capillary lumen. 25,600X

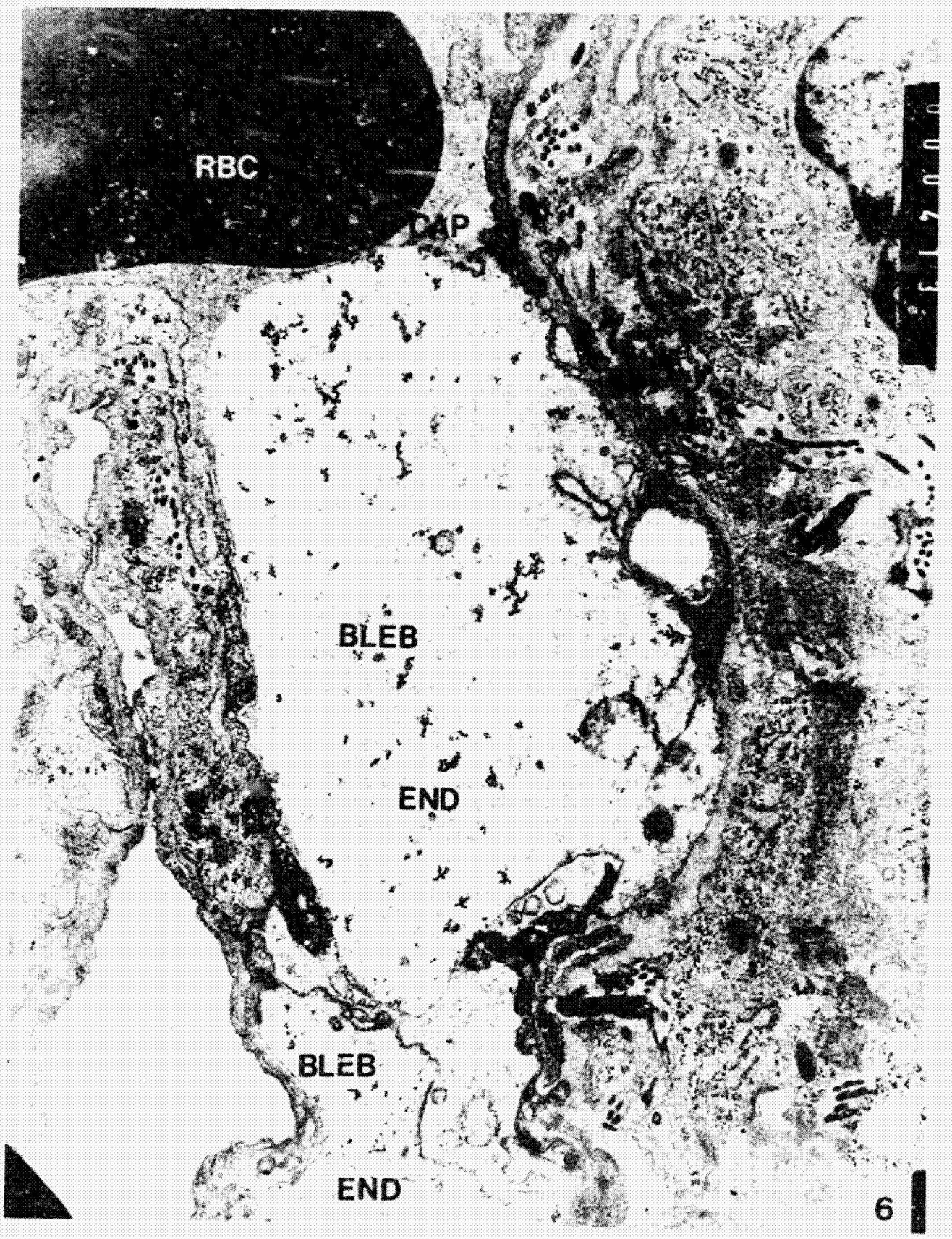
RBC
CAP
BLEB
END
BLEB
END
6

Figure 7 30-minute exposure. Epithelial cell blebs and rarified cytoplasm. 31,250X

CAP
ALV
BLEB
EPI
7

"wooly or fuzzy" cell membranes. Occasionally, there was a minimal amount of exudate in widely spaced alveolar spaces. The lining of the small blood vessels appeared to contain large vacuoles at the base of most of the endothelial cells (fig. 8). The lamellar bodies of the Type II epithelial cells appeared to have lost much of their internal structure (fig. 9). The mitochondria were normal, and in fact, nowhere in the sections examined did they appear abnormal.

After an exposure of 1 hour, the changes noted at 30 minutes were seen more frequently. Again, there was blebbing of the capillary endothelium (fig. 10), and of the epithelium (fig. 11). There was slightly more alveolar exudate (fig. 10). The lining of the small blood vessels was more extensively vacuolated than at 30 minutes with the lining thrown into great folds (fig. 12). The lamellar bodies were devoid of internal structure and the empty sacs appeared larger than normal size bodies (fig. 13). At this time a small amount of interstitial edema could be seen, but it was limited in quantity and sparsely located. Also at this time the indistinct or "fuzzy" epithelial cell membranes with their apparent discontinuities were observed more often than at 30 minutes exposure (fig. 14).

One hour following sixty minutes exposure to oxygen difluoride, all the alterations appearing at earlier intervals were present. There were many endothelial blebs (fig. 15, 16) alveolar exudate (fig. 16), "fuzzy" epithelial cells (fig. 15), extensively vacuolated endothelial lining of small blood vessels (fig. 17) and empty lamellar bodies (fig. 16).

In addition, a number of platelets appeared in the capillaries and in the small blood vessels (fig. 18). Also at this time, definite breaks occurred in the capillary endothelium ( fig. 19).

At 2 hours postexposure, the picture was about the same with endothelial blebs (fig. 20), and breaks in the endothelium (fig. 21), "fuzzy" partially destroyed aveolar-epithelium, empty sacs in place of lamellar bodies (fig. 20) and some interstitial edema.

Tissue from animals injected with ferritin was also examined, but not enough ferritin remained after the exposure to provide conclusive results concerning small leaks in or early compromise of the capillary or small blood vessel lining.

## DISCUSSION

The changes observed were not those expected. The early alterations were, indeed, indicative of increased fluid accumulation,

Figure 8 30-minute exposure. Small blood vessel. Note large vacuoles and rarified cytoplasm of endothelial lining cells. 9,700X

Reproduced from best available copy.

Figure 9 30-minute exposure. Loss of internal structure of lamellar bodies within Type II epithelial cells. 31,250X

LB
LB
M
M

Figure 10 60-minute exposure. Endothelial blebs partially obstructing capillary lumen. Minimal alveolar exudate (*). Disruption of Type I epithelial cell plasma membrane (→) and distortion of surface (⇒). 11,400X

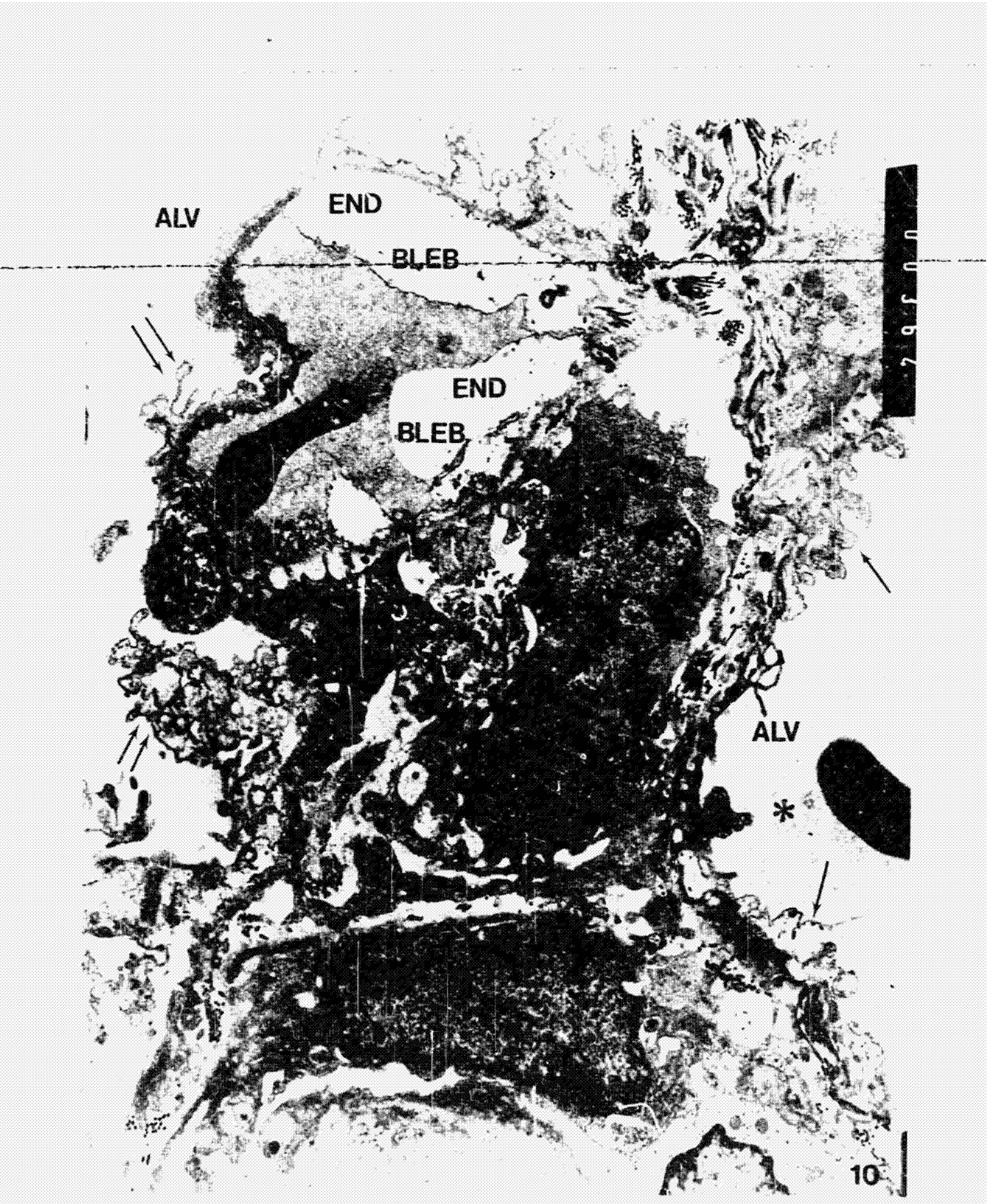




Reproduced from best available copy.

Figure 11 60-minute exposure. Epithelial bleb, rarified cytoplasm. 20,250X


EPI
CAP
RBC

Figure 12 60-minute exposure. Small blood vessel, note large vacuoles at bases of endothelial lining cells. 17,100X

V
END
V
V
0.5 μ
12

Figure 13 60-minute exposure. Lamellar bodies of Type II epithelial cells have lost their internal structure. Note rarified cytoplasm of blood vessel lining cells. 11,400X

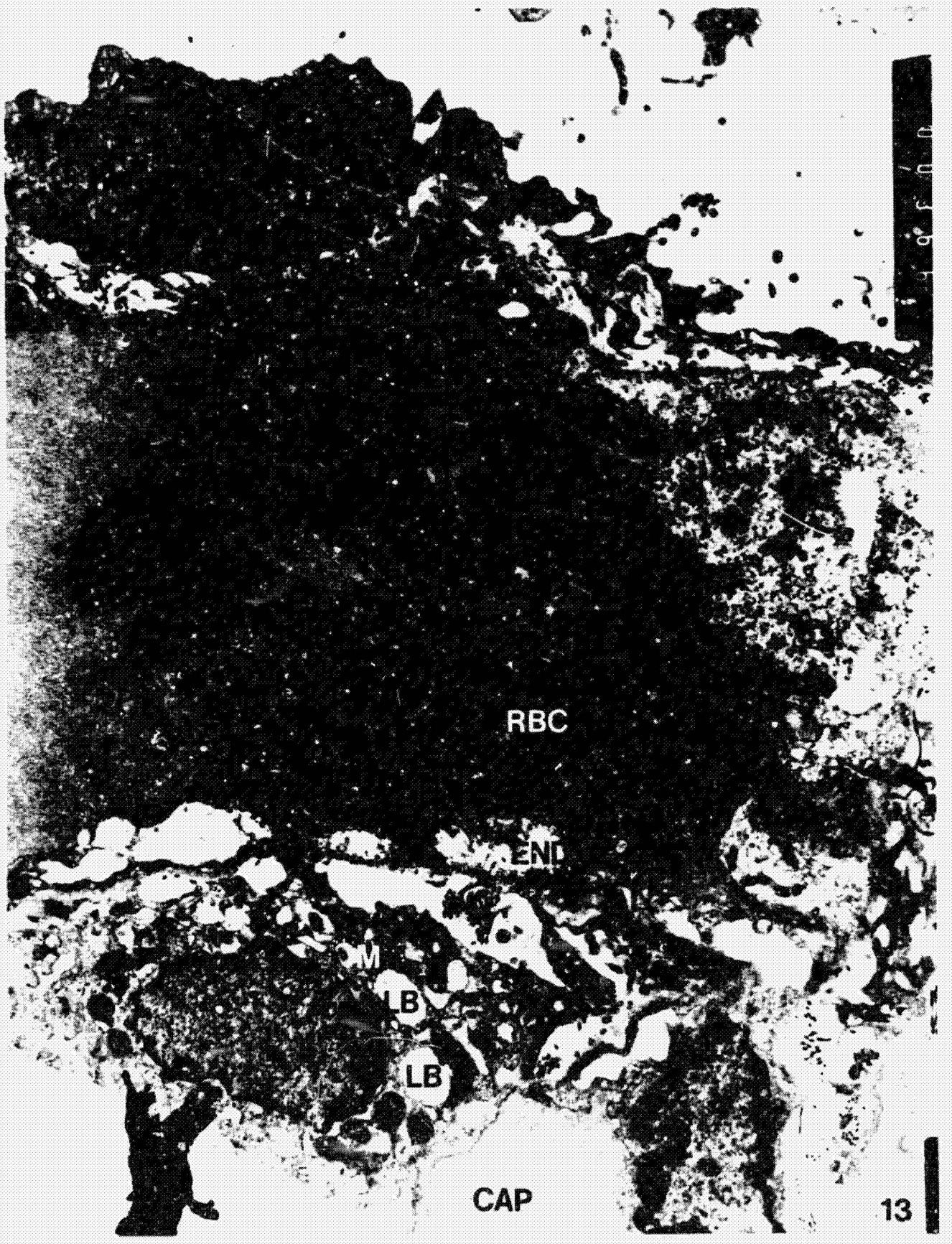
RBC
END
M
LB
LB
CAP
13

Figure 14 60-minute exposure. "Fuzzy" epithelium. 17,100X

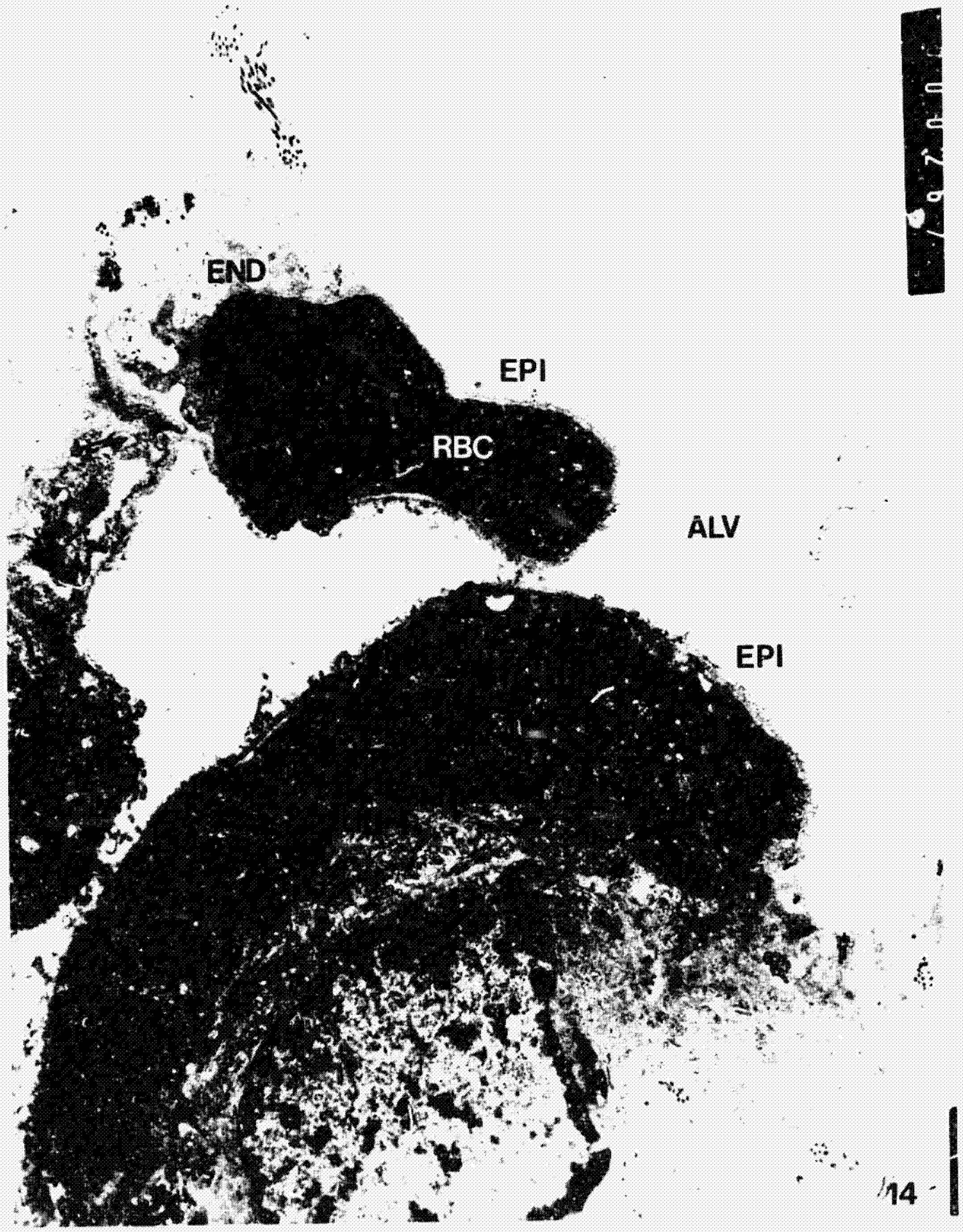
END
EPI
RBC
ALV
EPI
14

Figure 15 1 hour post-exposure. "Fuzzy" epithelium. 20,250X

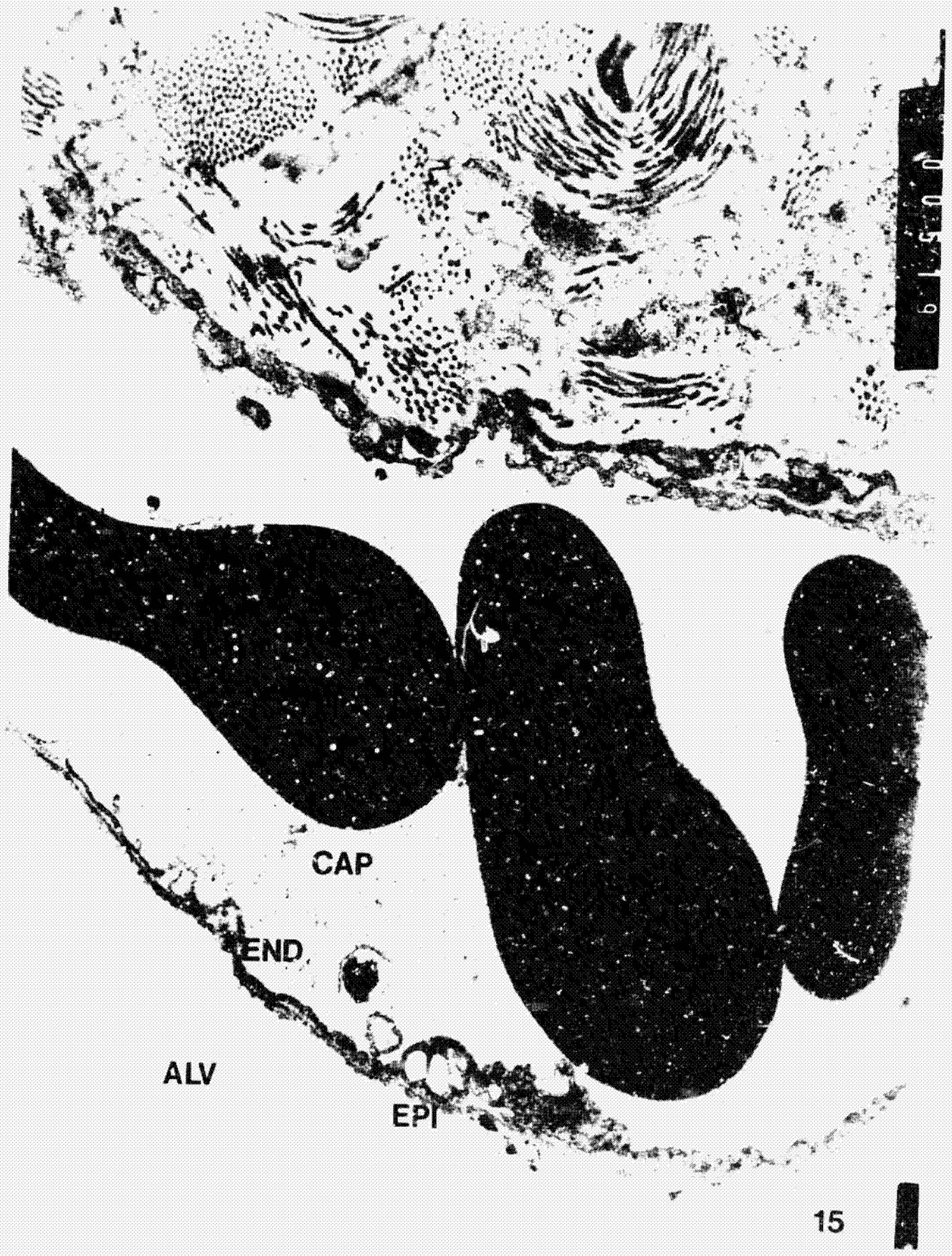
CAP
END
ALV
EPI
15

Figure 16 1 hour post-exposure. Endothelial blebbing occurs here. Note minimal alveolar exudate (*). 17,100

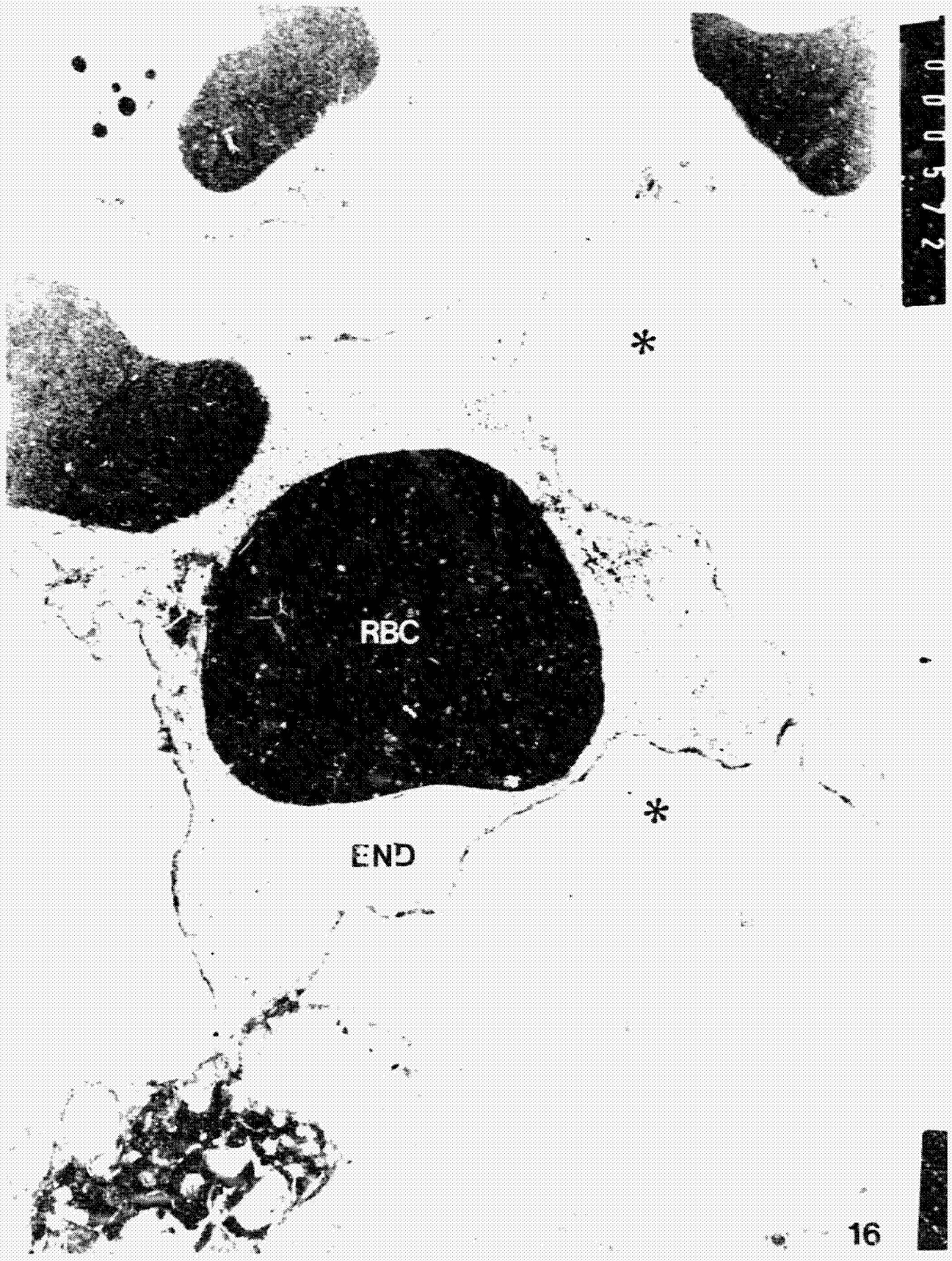
RBC
END
*
*
16

Figure 17 1 hour post-exposure. Type II cell with enlarged empty vesicles in place of lamellar bodies. Cytoplasm very condensed 20,250X

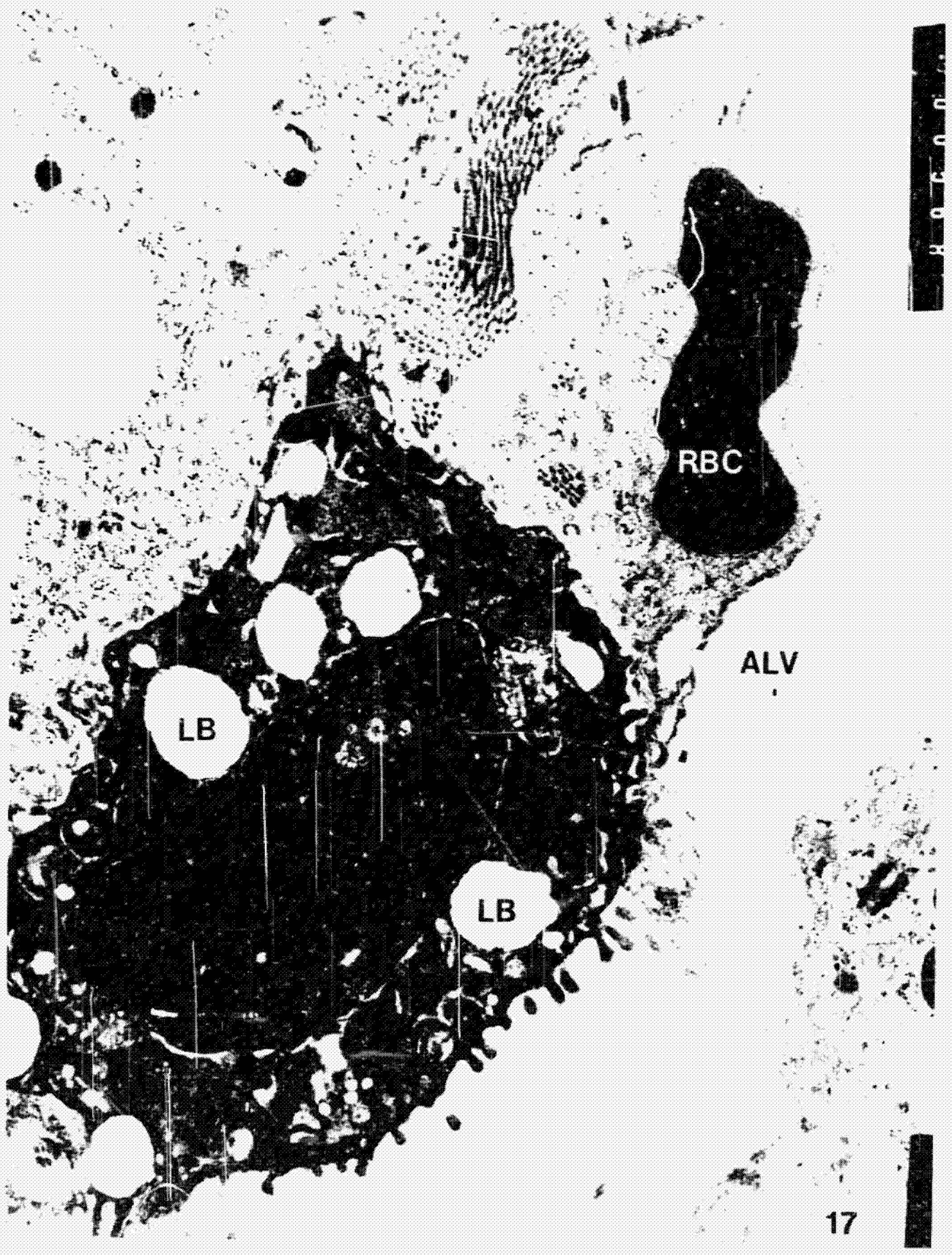
RBC
ALV
LB
LB
17

Figure 18 1 hour post-exposure. Aggregation of platelets (PL) in small blood vessel or capillary. Rupture of endothelial bleb (→). Degenerative changes in epithelial cell (⇒). 11,400X

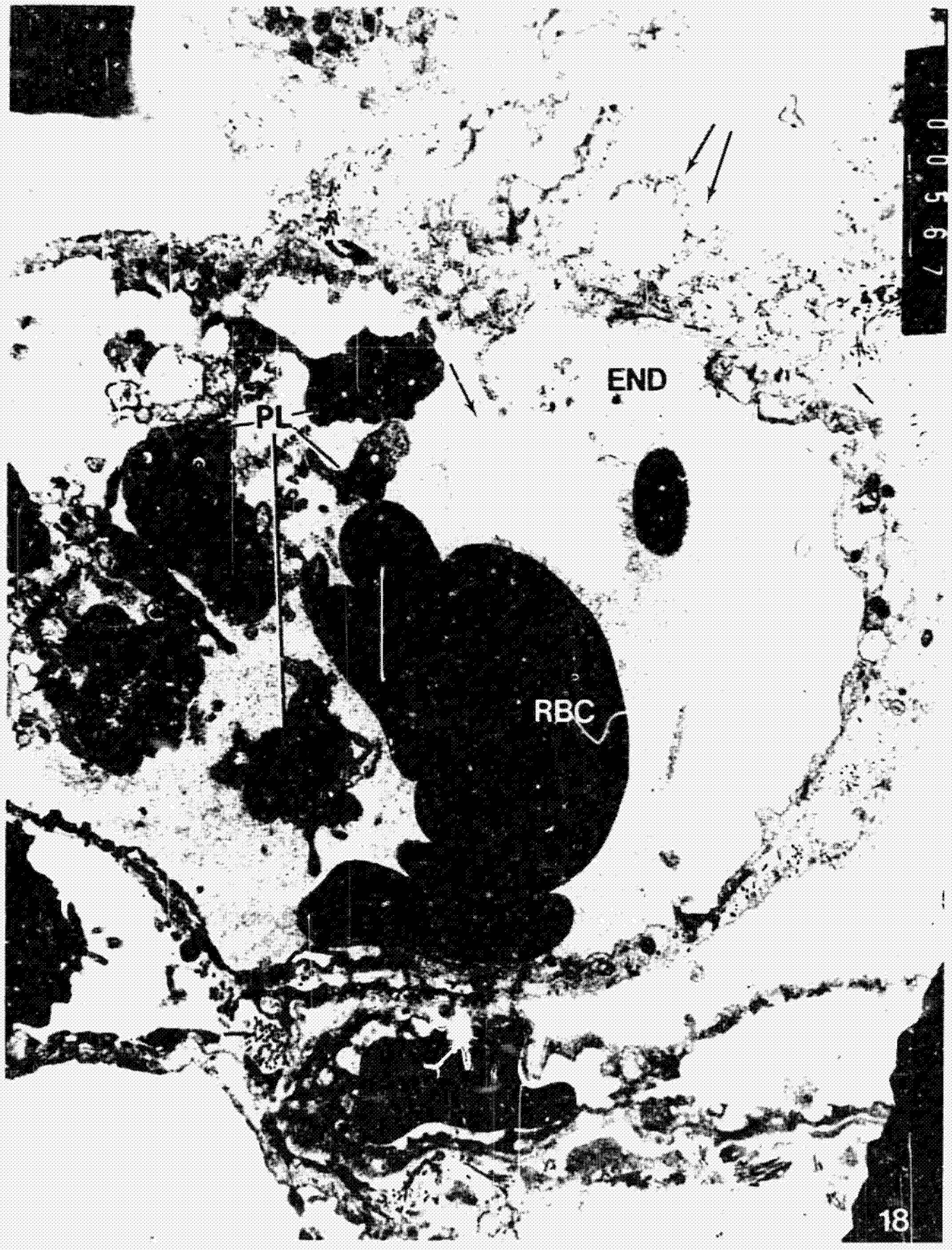
END
PL
RBC
18

Figure 19 1 hour post-exposure. Breaks have occurred in the endothelial lining (→). Actually there is complete erosion of the epithelial and endothelial cells leaving only the basement membrane with shreds of debris. 25,600X

EPI
19

Figure 20 2-hour post-exposure. Endothelial blebbing still seen. Type II cell with enlarged empty vesicles in place of lamellar bodies. 20,250X

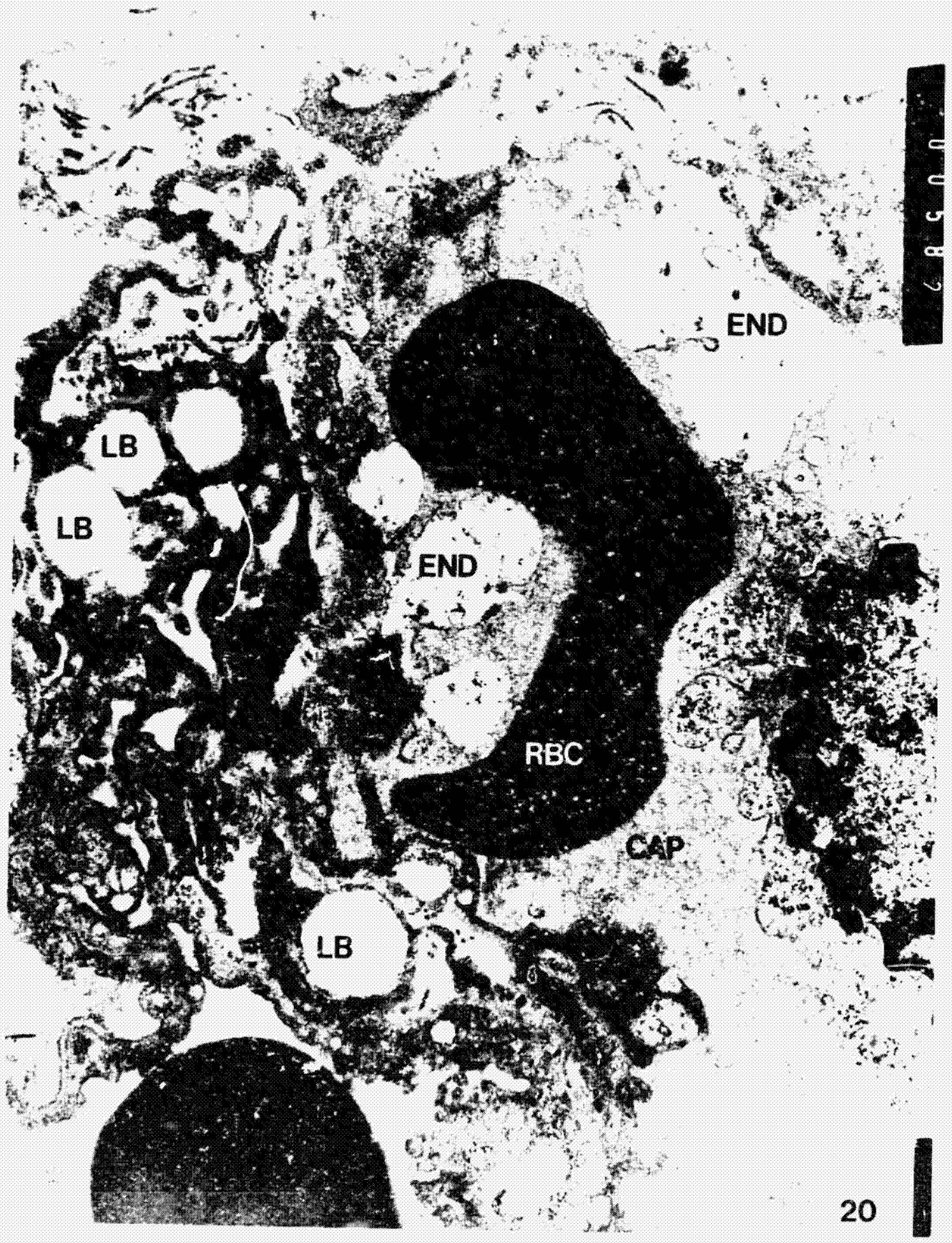
END
LB
LB
END
RBC
CAP
LB
20

Figure 21 2-hour post-exposure. Breaks in endothelial cell (→). 11,400X

Reproduced from best available copy.

but increased mainly intracellularly, not extracellularly. The blebbing of both the endothelial and epithelial cells is surely caused by increased fluid as are the large fluid filled vacuoles in the endothelial lining cells of the small blood vessels. At this point, however, the organizm is still able to handle the increased fluid and there are apparently no major leaks or breaks in either the capillary or small blood vessel walls even though occasional discontinuities do appear in a few epithelial cells. The only extra-cellular fluid apparent was a very small amount in the basement membrane and an occasional alveolus containing some exudate. No interstitial edema of any significance was noted after 30 minutes exposure. Platelets, often indicative of small capillary leaks (ref. 1) were not evident at this time.

After 60 minutes exposure, the same types of changes were seen as at 30 minutes, but the blebbing was more extensive as was the vacuolization of the endothelial lining of the small blood vessels. Extracellular fluid had increased somewhat in the form of more alveoli containing exudate and in some scattered patches of interstitial edema. Of note at this time was the increase in occurrence of the indistinct or "fuzzy" appearance of the epithelium with its concomitant loss of continuity. This appeared to be a corrosive change of the epithelium, an unexpected change, which had its beginning early in exposure, certainly as early as 30 minutes. At 1 hour post-exposure, this deterioration was even more marked and often the epithelium appeared to form a row of vesicles. At the same time, the endothelium was undergoing changes and it, too, had now lost its integrity in some places. As if to mark the compromise of the alveolo-capillary wall, paltelets now appeared in the capillaries. These also appeared in the small blood vessels, very possibly indicating small breaks in that area. At 2 hours post-exposure, the lungs exhibited a similar picture with the damage more widespread and more extensive.

Throughout the exposure, evidences of intracellular damage were sought, but none appeared except for the increase in intracellular fluid. Changes in cellular organelles, especially in the mitochondria were expected as occur in oxygen (refs. 8, 10) and ozone (ref. 2) exposure, but were not observed. Dost et al. (ref. 7) suggested that the action of $OF_2$ was intracellular, and that it possibly destroyed cells internally, but left their external structure intact and therefore still observable by light microscopy. No evidence to support this theory was found. The only organelles consistently altered were the lamellar bodies of the Type II epithelial cells. These are reportedly the source of surfactant

(ref. 13) and alterations in this most important substance could lead to such things as atelectasis, as the alveoli lose their ability to remain patent. Atelectasis was reported by Lester and Adams (ref. 12) using 5-minute 20 ppm exposures. The interesting feature of the Type II cell is that its cell membrane remains intact whereas the internal membranes of the lamellar body are destroyed. Also, the Type II cell membrane remains while the Type I cell and the endothelial cell membranes are greatly disrupted.

As is so often the case, this investigation has undoubtedly raised more questions than it has answered. However, we do know that exposure to $OF_2$ causes progressive destruction to lung tissue which does not cease when exposure ceases. Early damage is manifested promarily as increased cellular fluid as evidenced by rarified cytoplasm, large fluid-filled blebs and vacuoles. These early changes are quite similar to those observed with other lung toxicants, e.g., oxygen (refs. 4, 8, 9, 10) ozone (ref. 2) smog ref. 3) and nitrogen oxide (ref. 14). At this stage the $OF_2$ may be acting as Dost has suggested, by passing intact into the cell where it acts on the cytoplasmic membrane altering its permeability. However, it would then seem that the cellular organelles should also show alteration. I would, therefore, suggest that the $OF_2$ passes intact into the capillary where it acts on the endothelial cytoplasmic membranes and also on the lining membranes of the small blood vessels. Not all the $OF_2$ passes into the blood stream, however, since the epithelial cells also show some rarification of cytoplasm and blebbing. The main injury to the epithelial cell has begun before 30 minutes exposure and continues increasing in severity up to two hours post-exposure. This type of destruction is more easily linked to a corrosive action as $OF_2$ slowly converts to HF. Oxygen difluoride, then, acts first on membranes, altering their permeability or, in the case of the lipid rich membranes of the lamellar bodies, destroying them completely. The residue, over a period of time, converts to HF both on the alveolar side and the capillary side and destroys both the epithelial and endothelial cells.

The expected profuse edema of the alveoli and interstitium was not seen. In fact, the tissue appeared quite "dry", with much of the alveolar exudate being more debris than fluid. Perhaps sacrificing animals at a later time post-exposure might have revealed more edema, but this study was designed to seek the earliest changes.

As for the light microscopy, finding no lesions using paraffin-embedded sections and the light microscope after a minimal $LC_{100}$ is not surprising during the first hour post-exposure, and has been previously described by Dost (ref. 7) when minimal lethal doses are given. Lester and Adams (ref. 12), as previously stated, using five-minute 20 ppm exposures reported minimal changes at five minutes post-exposure consisting of congestion and atelectasis. Petechial hemorrhages occurred at one hour. Microscopically, they described a purulent response. In our experience in previous exposures, a purulent response is not typical, and the possibility of an infectious pneumonia in these rats must be considered. The method of fixation, for light microscopy, instilling fixative via the trachea under pressure, could have masked the early minimal changes noted grossly. The changes noted in tissue fixed for electron microscopy, by immersion, would tend to indicate that this is indeed the case.

## REFERENCES


1. Ashford, T. P. and D. G. Freidman, "Platelet Aggregation at Sites of Minimal Endothelial Injury." Amer. J. Path. 53:599-607, 1968.

2. Bils, R. G., "Ultrastructural Alterations of Alveolar Tissue of Mice; III. Ozone." Arch. Environ. Health 20: 468-480, 1970.

3. Bils, R. F. and J. C. Romanovsky, "Ultrastructural Alterations of Alveolar Tissue of Mice; II. Synthetic Photochemical Sm. " Arch. Environ. Health 14:844-858, 1967.

4. Cedergren, B., L. Gyllensten, and J. Wersall, "Pulmonary Damage Caused by Oxygen Poisoning; An Electron Microscopic Study in Mice." Acta Paed. 48:477-494, 1959.

5. Cianko, G. M., Range Finding Tests on Oxygen Difluoride, Technical Report, Rockdyne Division of North American Aviation, Canoga Park, California, 1961.

6. Davis, Harvey V., "Acute Toxicity of Oxygen Difluoride." (AD 727525) In AMRL-TR-70-102, Proc. 1st Ann. Conf. Env. Tox., Sept. 9-11, 1970, p. 329, Aerospace Medical Research Laboratory, Wright-Patterson Air Force Base, Ohio, December 1970.

7. Dost, F. N., D. J. Reed, A. Finch, and C. H. Wang, Metabolism and Pharmacology of Inorganic and Fluorine Containing Compounds. AMRL-TR-67-224 (AD 681161) Aerospace Medical Research Laboratory, Wright-Patterson Air Force Base, Ohio, August 1968.

8. Harrison, G. A., "Fine Structural Alterations in the Blood-Air Barrier Following Exposure to 100% Oxygen at One Atmosphere." J. Cell. Biol. 39:58A, 1968.

9. Harrison, G. A., "Ultrastructural Changes in Rat Lung During Long-Term Exposure to Oxygen." Exptl. Med. Surg. 29:96-107, 1971.

10. Kistler, G. S., P. R. B. Caldwell, and E. R. Weibel, "Development of Fine Structural Damage to Alveolar and Capillary Lining Cells in Oxygen-Poisoned Rat Lungs." J. Cell. Biol. 32:605-628, 1967.

11. LaBelle, C. W., Studies on the Toxicity of Oxygen Difluoride at Levels of Exposure from 10 to 0.1 ppm by Volume, University of Rochester Manhattan Project, Pharmacology Report No. 478, 1945.

12. Lester, David and Robert W. Adams, "The Inhalational Toxicity of Oxygen Difluoride." Am. Ind. Hygiene Assn. Journal, Vol. 26, pp. 562-567, 1965.

13. Macklin, C. C., "Pulmonary Alveolar Mucoid Film and Pneumocytes." Lancet 1:1099-1104, 1954.

14. Stephens, R. J., G. Freeman, and M. J. Evans, "Early Response of Lungs to Low Levels of Nitrogen Dioxide; Light and Electron Microscopy." Arch. Environ. Health 24:160-179, 1972.



*U.S.Government Printing Office: 1973 — 758-428/240